

Case Vignettes and Clinical Pearls

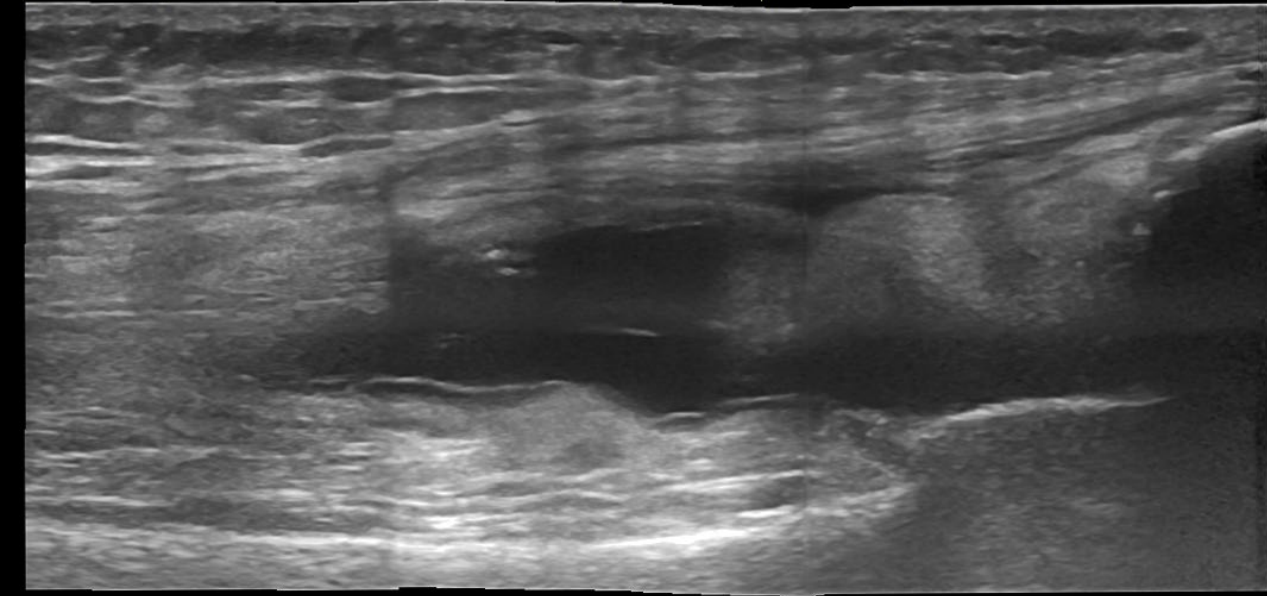
Case 1: 38 y/o male with severe hemophilia A with increased Left knee swelling s/p TKA (Hemlibra)

Patient History/Subjective

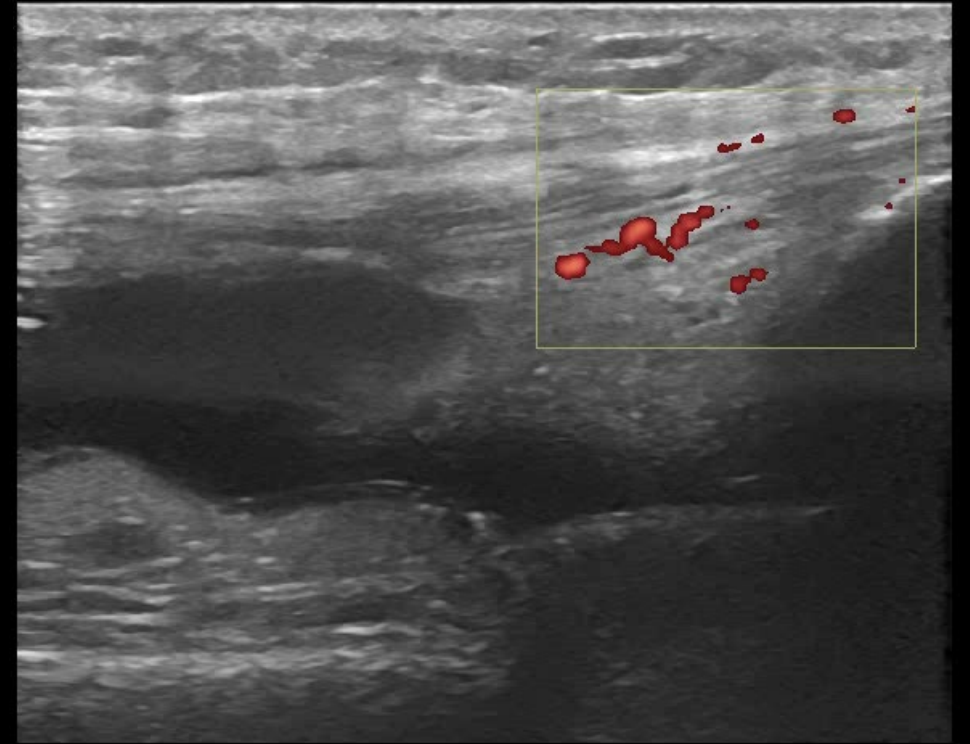
1. Patient unsure why he is swollen
2. Moved into a new apartment 5 days ago, swelling began 3 days ago. Consequently he infused but without change in symptoms.
3. Patient reports that over the last 3 days there has not been an improvement. Has stopped exercises 2/2 to swelling. Pain has improved over the last 3 days.
4. Surgery 5/26, visit 6/14 (close to 3 weeks post-op)
5. Discontinued NSAID 7 days ago

Patient Presentation

1. L knee AROM = 0-100
2. Increased swelling and redness in the L knee
3. Gait: Decreased stance time on L, reduced stride length on L, decreased knee flexion during swing phase.

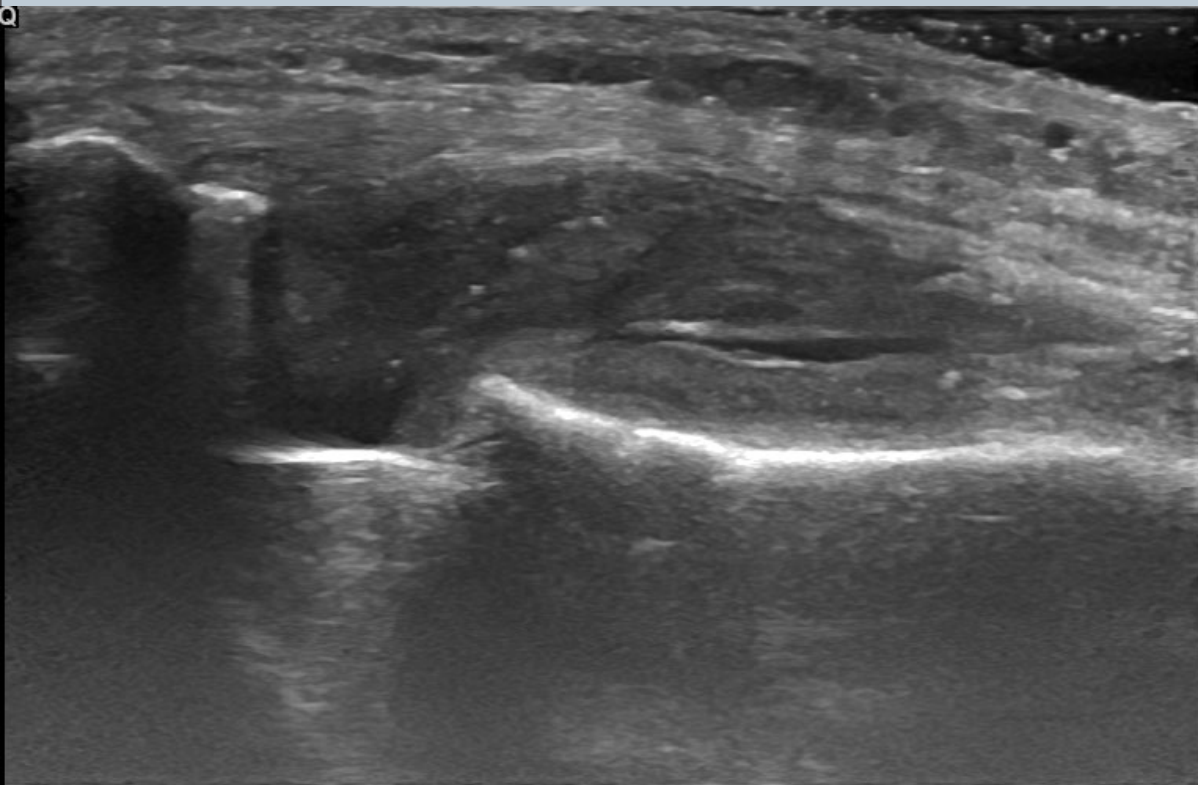


L KNEE SURPAPATELLA

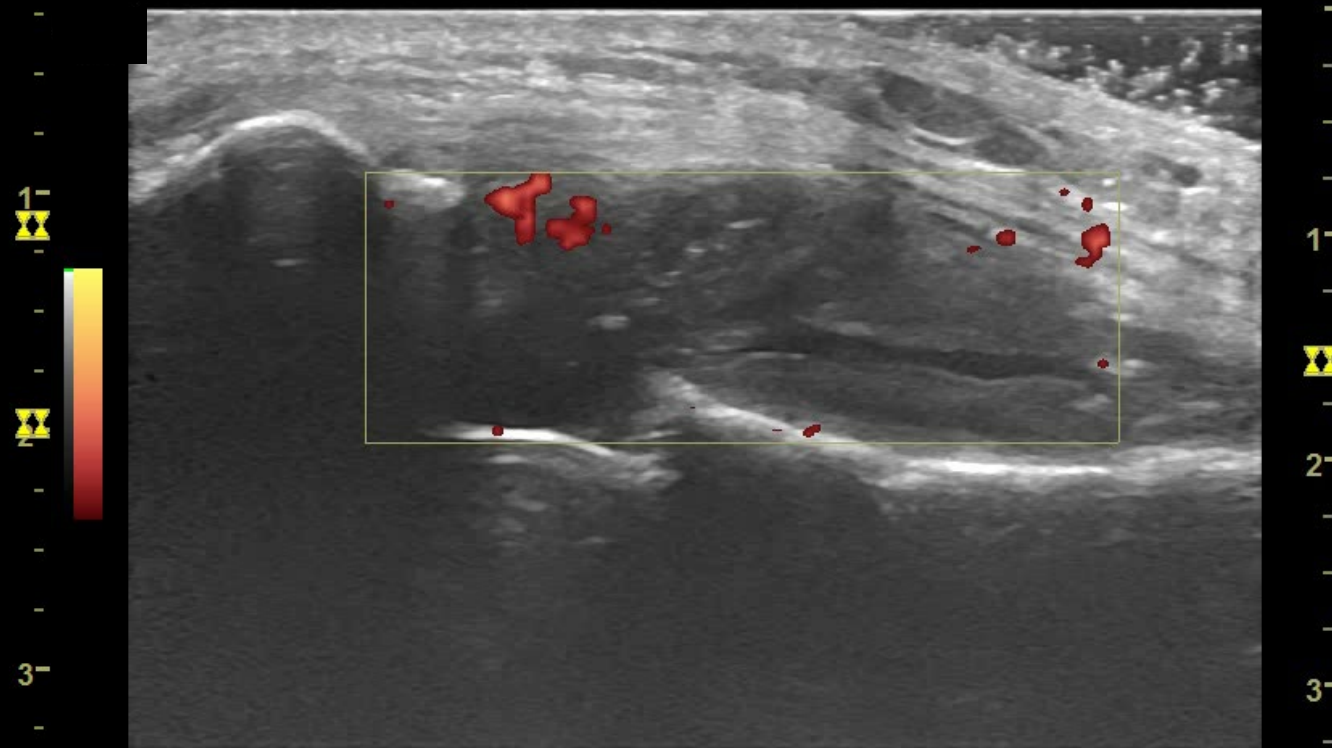


L KNEE SURPAPATELLA

Left SupraPatellar Bursa LAX

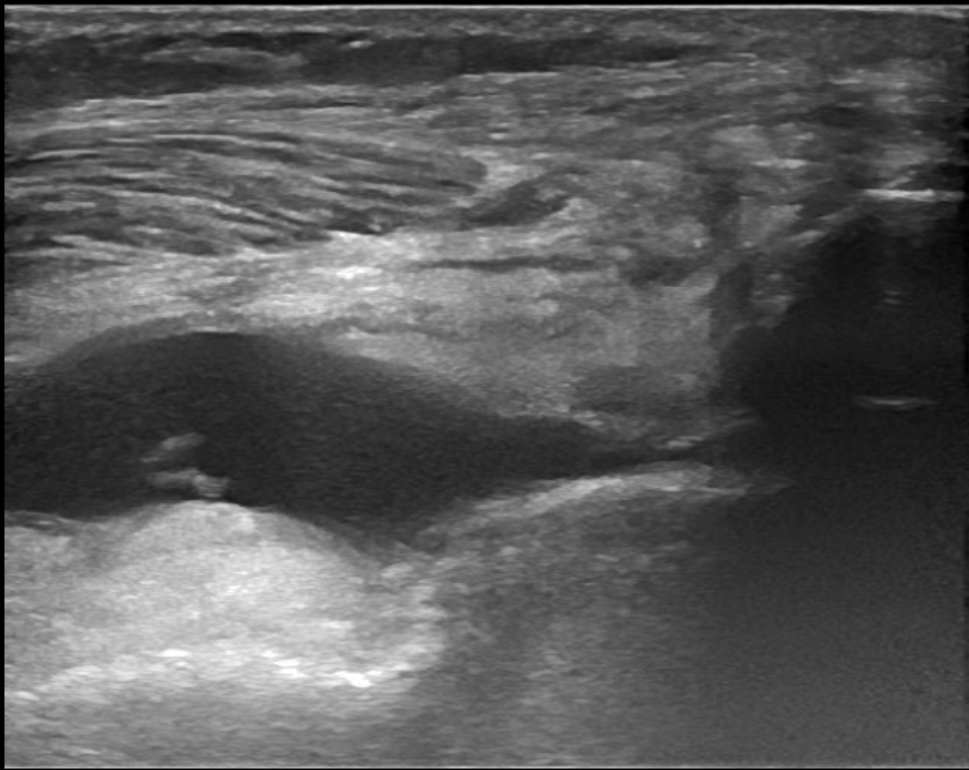


L KNEE LAT RECESS

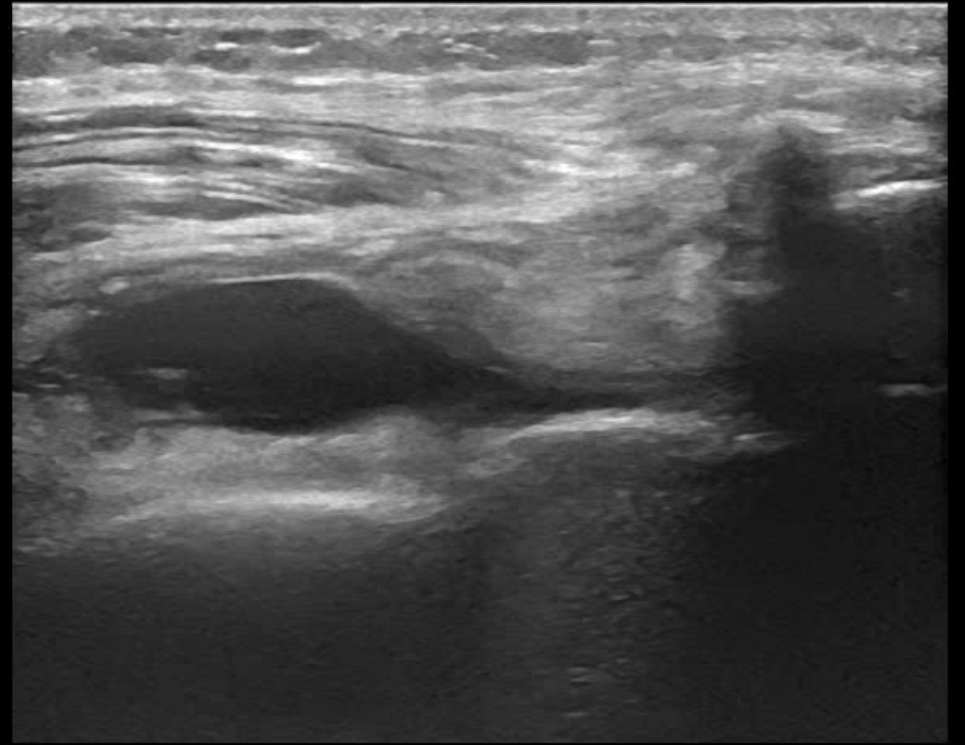


L KNEE LAT RECESS

Left Knee Lateral Recess SAX



L KNEE SUPRA OBQ



L KNEE SUPRA OBQ

Left SupraPatellar Bursa LAX (oblique)

Results/Treatment Plan

Findings

1. Anechoic simple fluid with positive PD

Treatment

1. Encourage use of NSAID
2. Continue Physical Therapy

Clinical Pearls

1. 6/20 (6 days later): Patient reports that he is doing better than last week. Thinks that he had new onset of swelling 2/2 to discontinuing NSAID for 2 days leading up in swelling. Has since restarted NSAID.

Knee flexion = 116

Knee extension = -3

Case 2: 73 y/o male with mild hemophilia A with Right knee pain after loss of balance

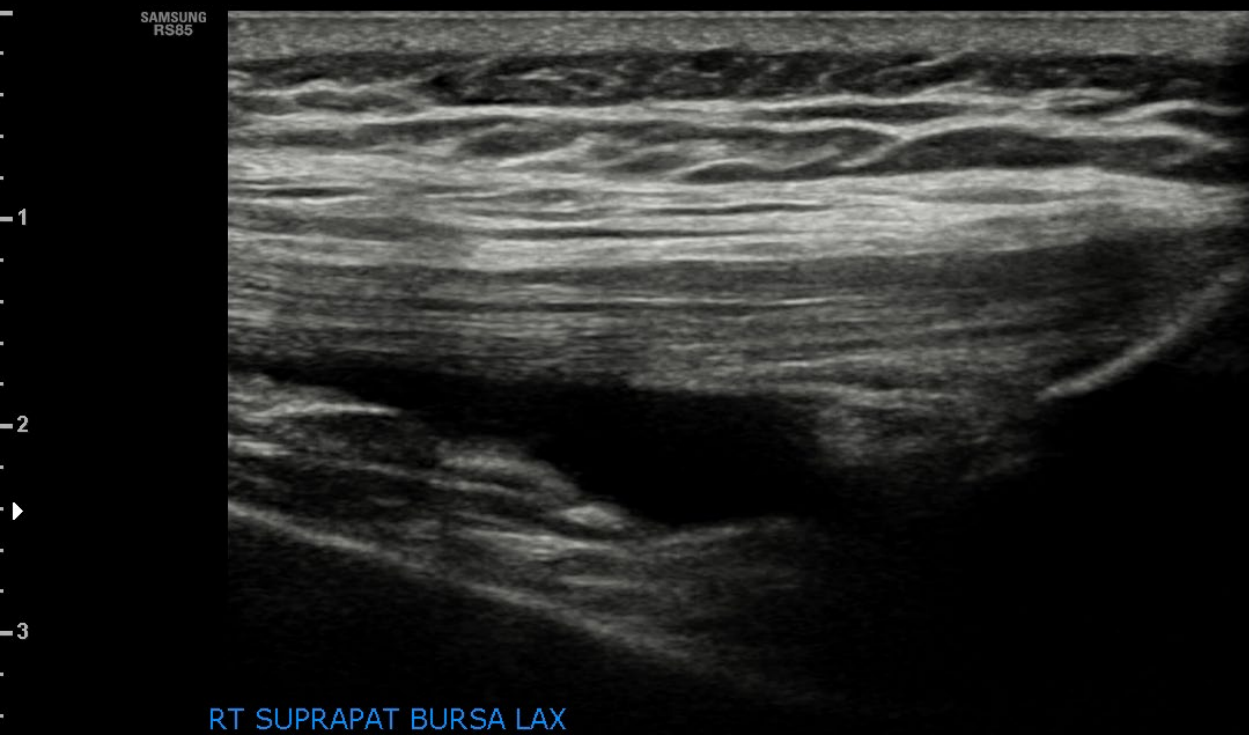
Patient History/Subjective

1. Patient reports that he was walking in his garden 2 days ago when he tried to avoid stepping on an object at the last second and “twisted” his knee. Patient lost his balance but was able to catch himself
2. Since the LOB, PRICE has helped a little.
3. Per patient, it feels like a bleed and “gelatinous-like.” Also, feels like it is going to give out
4. Patient is unable to self-infuse

Patient Presentation

1. ROM: Approximately 25% reduction
2. Swelling: increased warmth and edema noted
3. Gait: Severely antalgic, decreased WB on R
4. Palpation: Generalized tenderness surrounding knee

L3-12A / Musculoskeletal / FPS42 / MI1.1 / TIs0.2 / 04-23-2020 08:11:47 AM
2D G55 DR56 FA8 P90 Frq Gen./3.5cm



Right SupraPatellar Bursa LAX

SAMSUNG

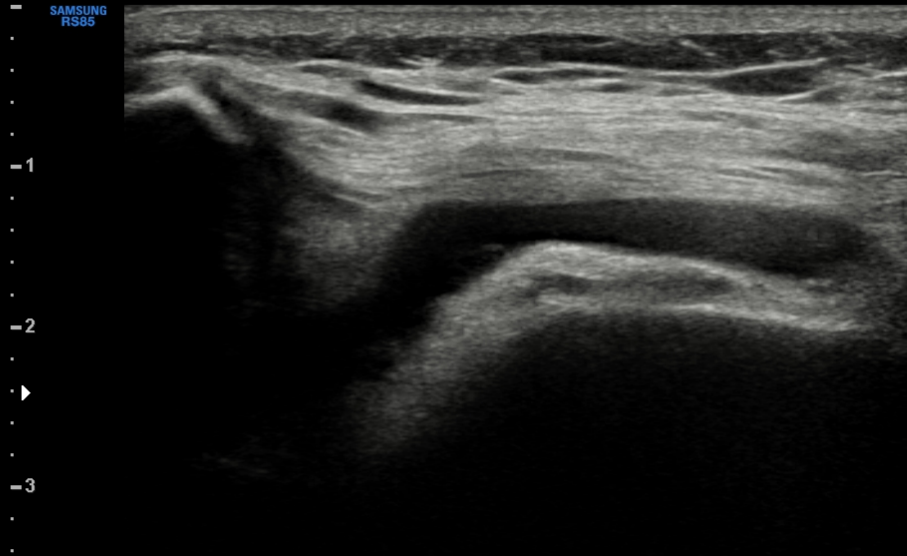
L3-12A / KNEE / FR42Hz

MI 1.1
TIs 0.2

04-23-2020

08:16:49 AM

2D G55 DR56 FA8 P90 Frq Gen./3.5cm

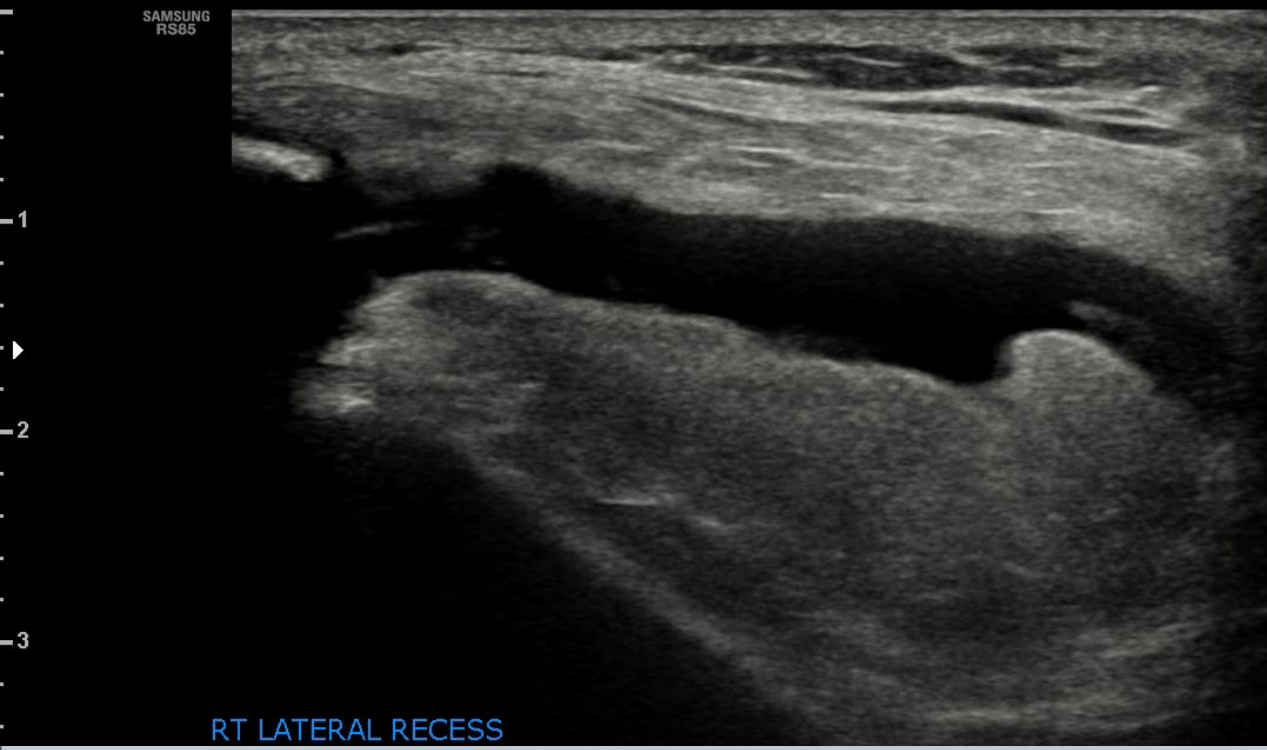


RT MEDIAL RECESS



Right Knee Medial Recess SAX

L3-12A / Musculoskeletal / FPS42 / MI1.2 / TIs0.1 / 04-23-2020 08:22:26 AM
2D G55/DR56/FA8/P90/Frq Gen./3.5cm



Right Knee Lateral Recess SAX

Results/Treatment Plan

Findings

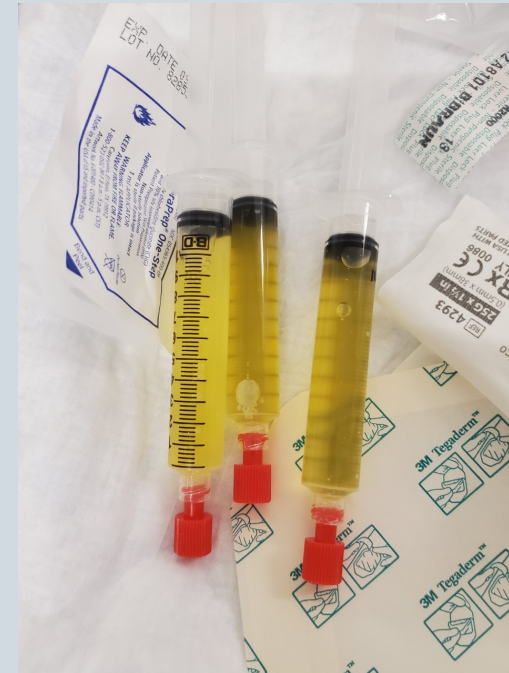1. Suprapatellar Bursa LAX: **Anechoic simple fluid and soft tissue proliferation**
2. Medial Recess SAX: **Hypoechoic complex fluid, soft tissue proliferation and irregular bony margin**
3. Lateral Recess SAX: **Anechoic simple fluid, soft tissue proliferation and irregular bony margin**

Treatment

1. Aspiration
2. Physical Therapy

Clinical Pearls

1. Don't be afraid to compress
2. Confirmation bias



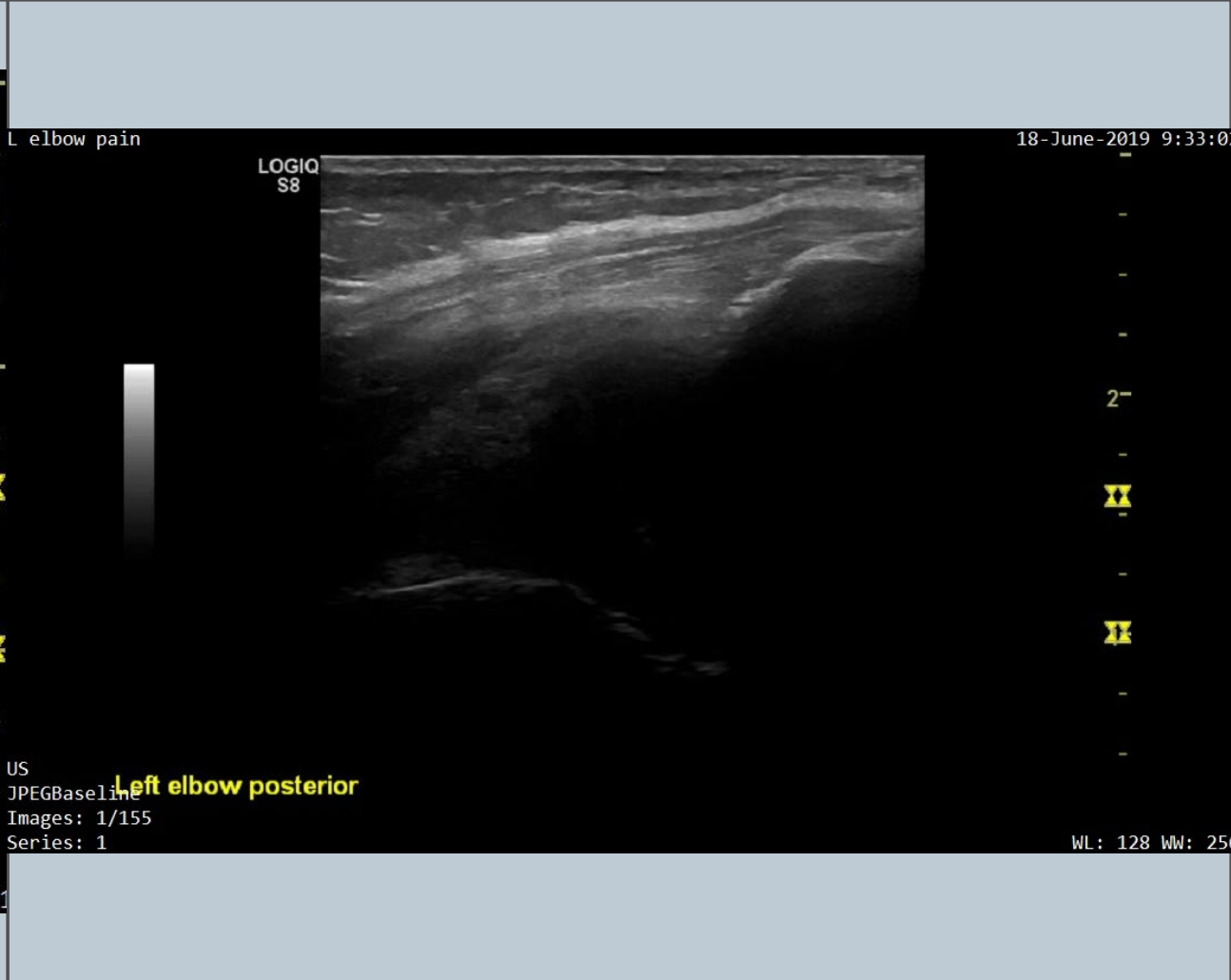
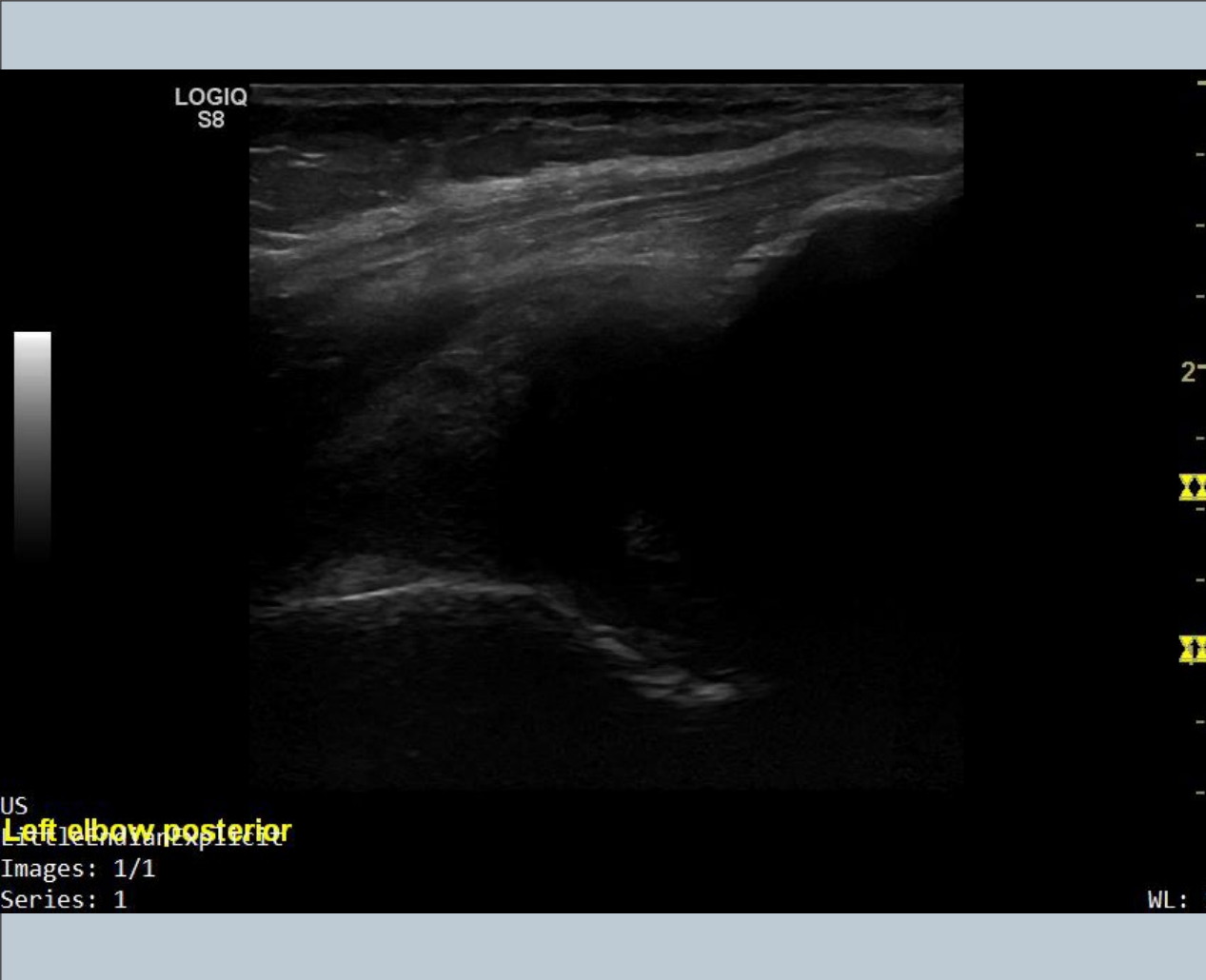
Case 3: 38 y/o male with moderate hemophilia A with Left elbow swelling and loss of ROM

Patient History/Subjective

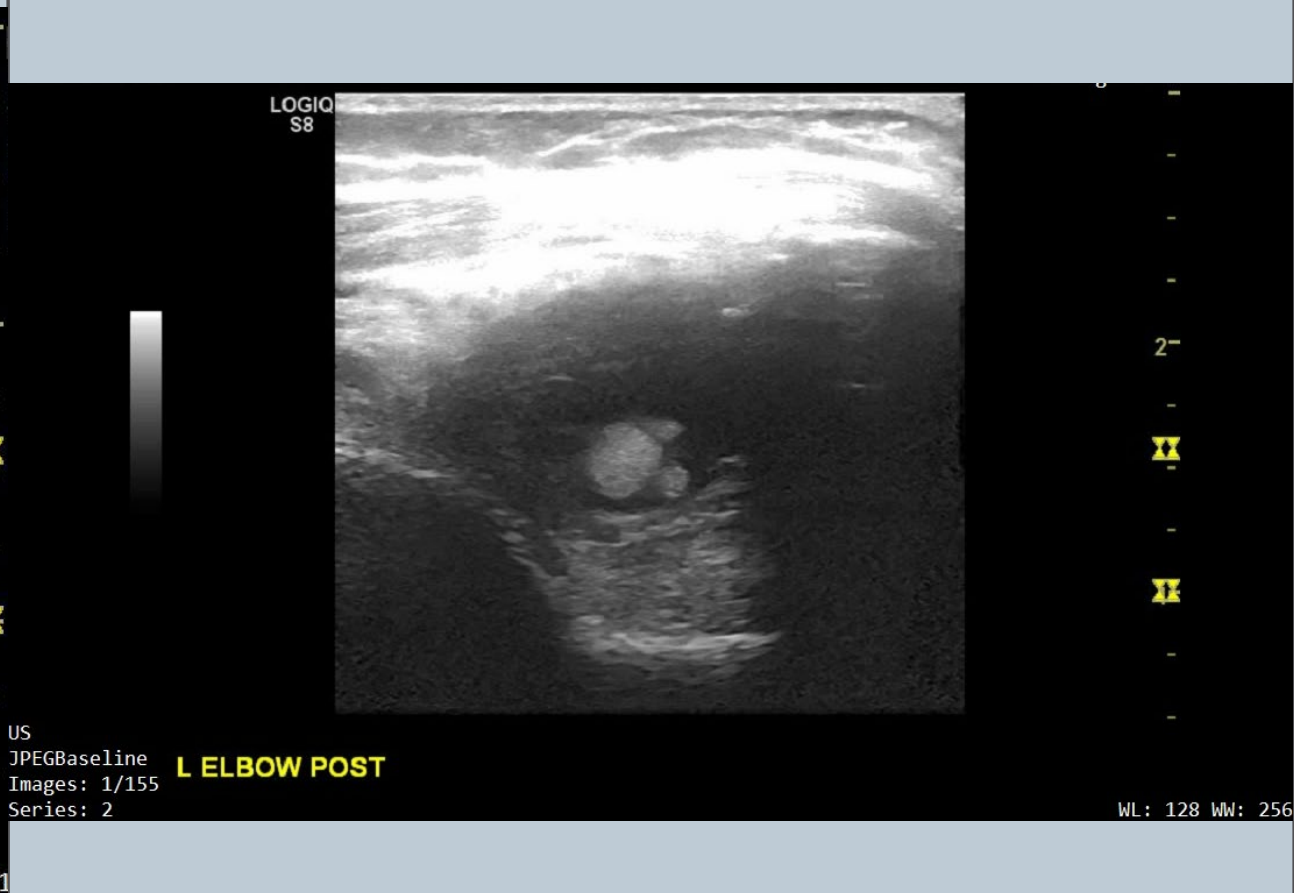
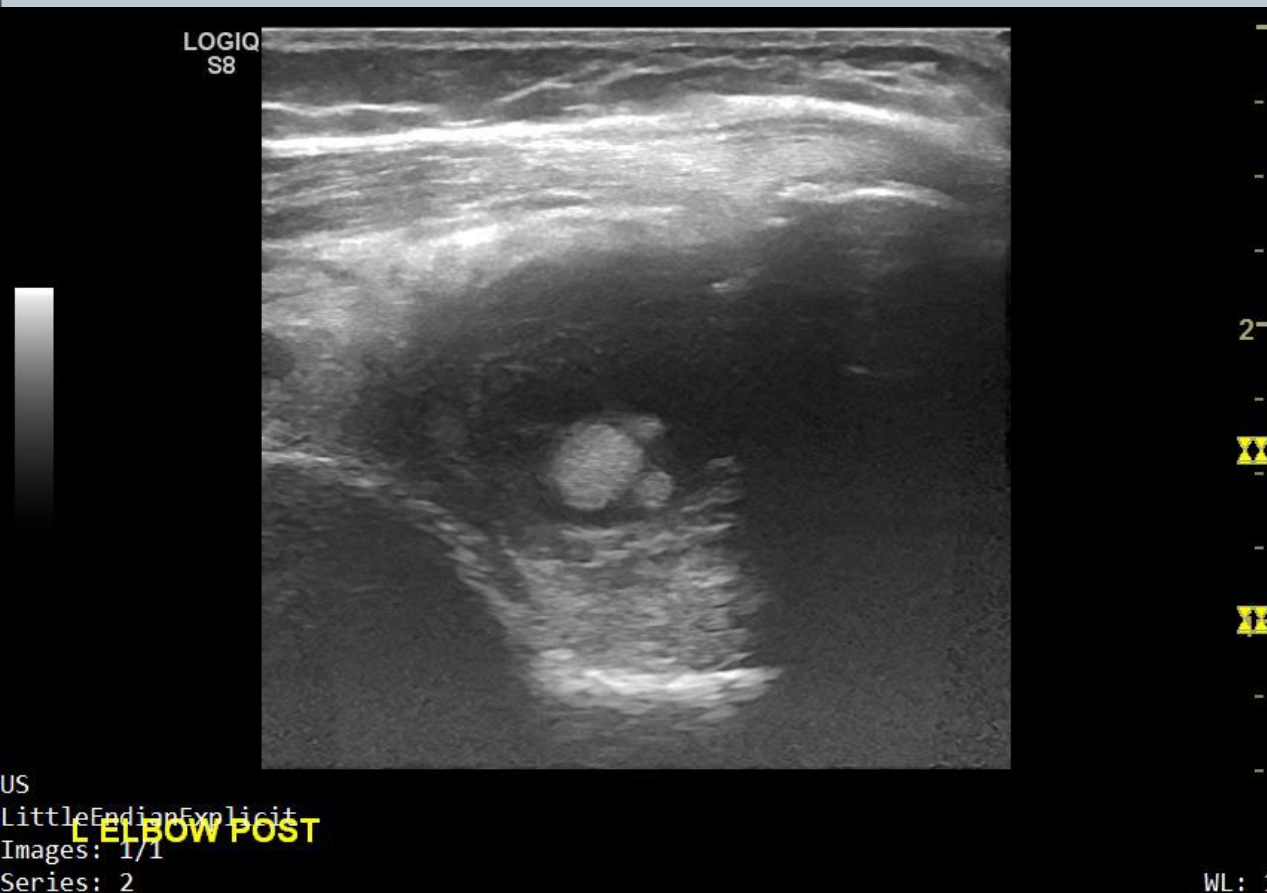
1. New patient at HTC, had been infusing PRN
2. Reports increased swelling/reduced ROM but there has not been any change in activity. Did not infuse
3. Weight lifts 3-4 days/week, works as a Physical Therapy Assistant
4. Patient reports that it did not feel like a bleed
5. Per patient, has bled into his L elbow at least 7 times per year

Patient Presentation

1. Swelling: Increased swelling without presence of warmth in the L elbow
2. Palpation: Mild TTP to lateral epicondyle, edema 1+ around posterior elbow
3. Pain: 4/10 at rest



Left Posterior Elbow LAX



Left Posterior Elbow LAX

2 Months Later

Results/Treatment Plan

Findings

1. Posterior Elbow LAX: **Anechoic simple fluid, displacement of fat pad, tendon abnormality and hyperechoic soft tissue fronds noted in the olecranon fossa**

Clinical Pearls

1. Baseline images
2. Image Optimization

Treatment

1. Prophylaxis 2x/week
2. Elastic adhesive taping
3. Patient education

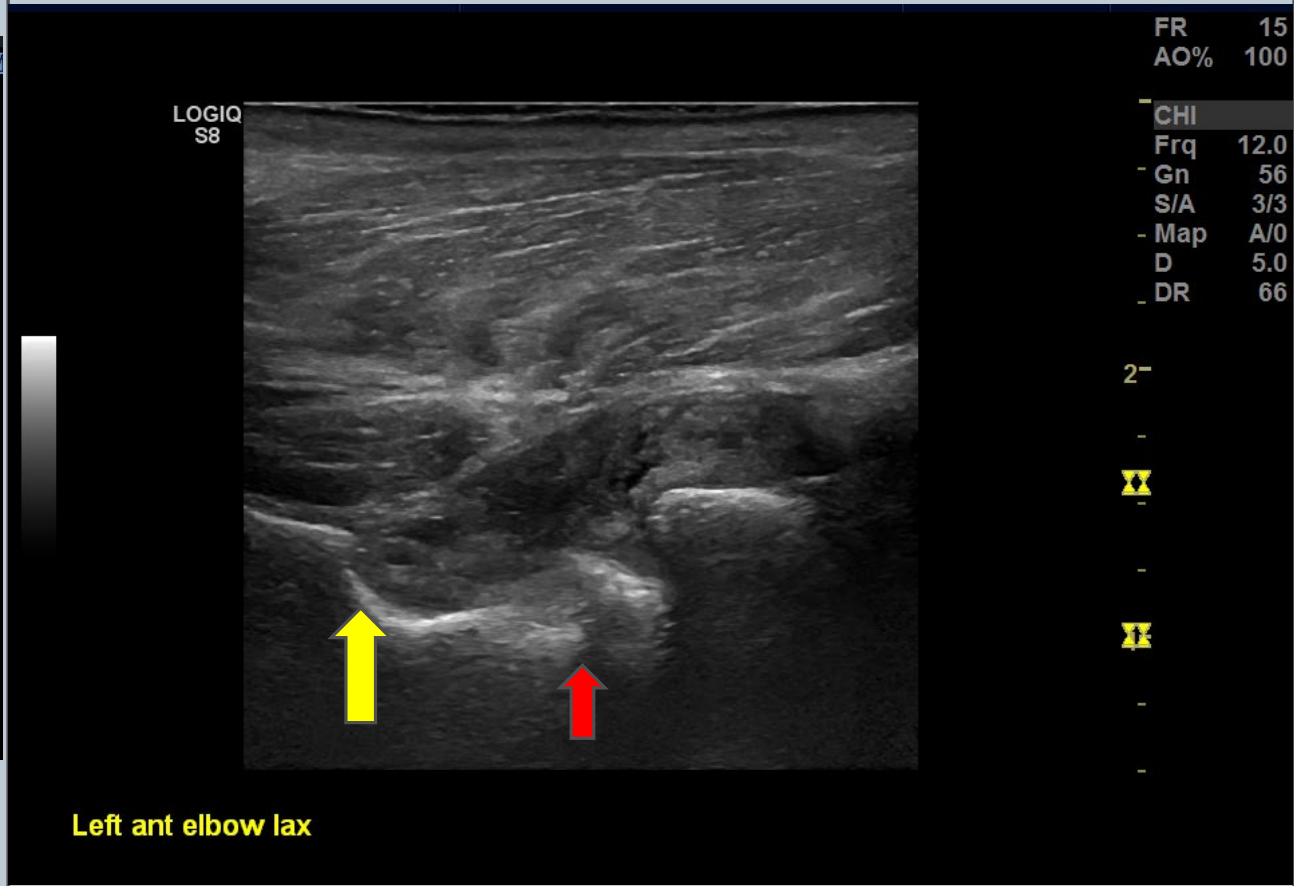
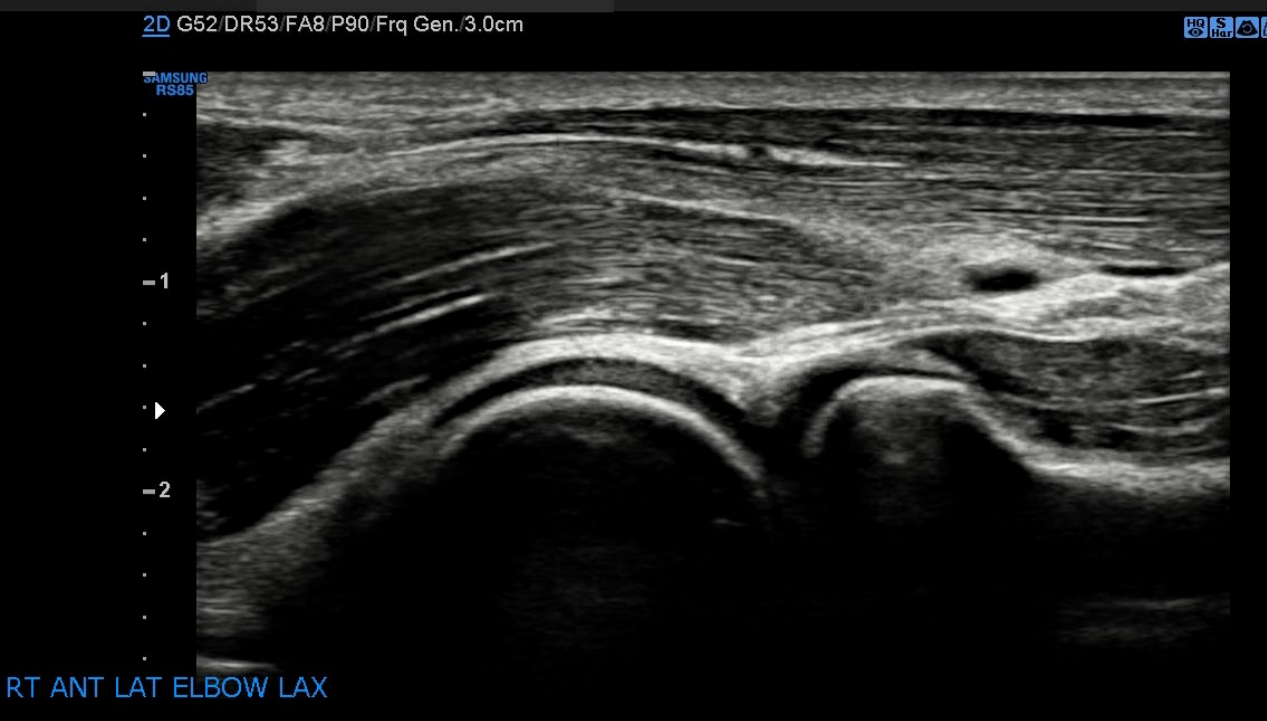Case #4: 59 y/o male with severe hemophilia B with Left elbow arthropathy

Patient History/Subjective

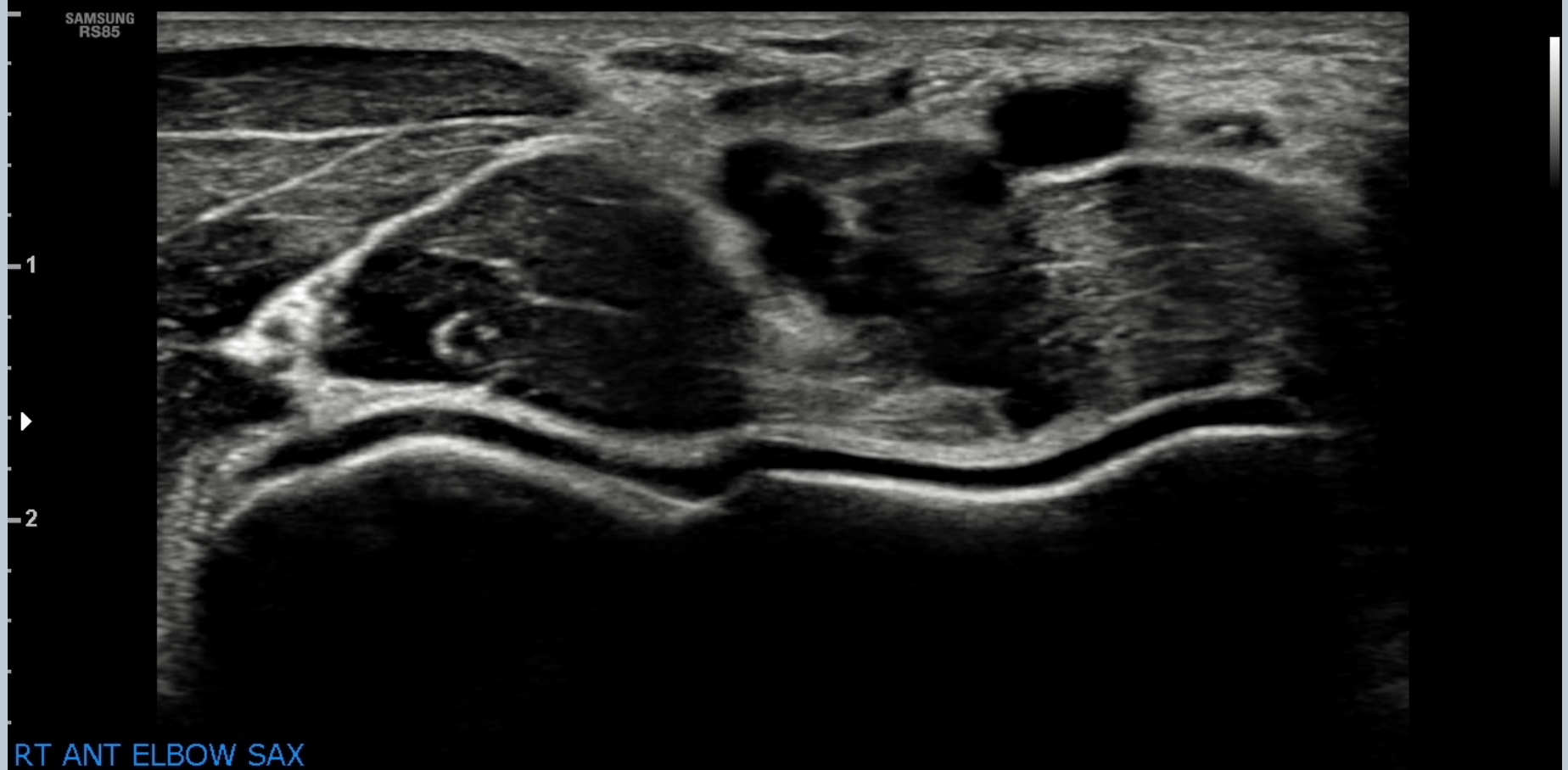
1. Patient at the clinic for a repeat baseline MSKUS
2. Left elbow considered one of the patient's "target joints"

Patient Presentation

1. ROM:
 1. Elbow flexion = 102
 2. Extension = -24
 3. Supination = 51
 4. Pronation = 78



Anterior-Lateral Elbow LAX



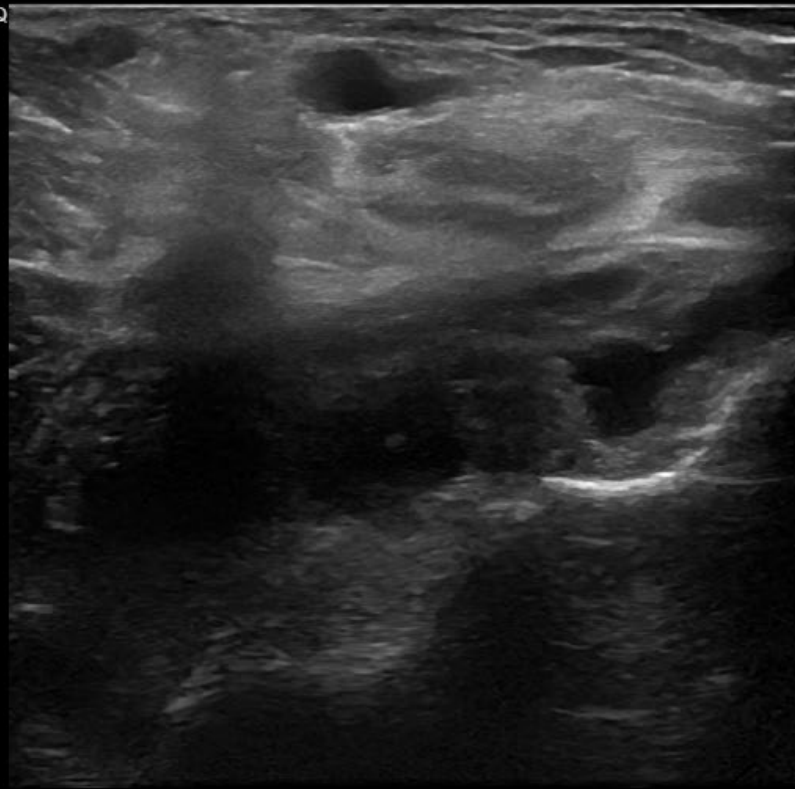
Left Anterior Elbow SAX

09/13/18

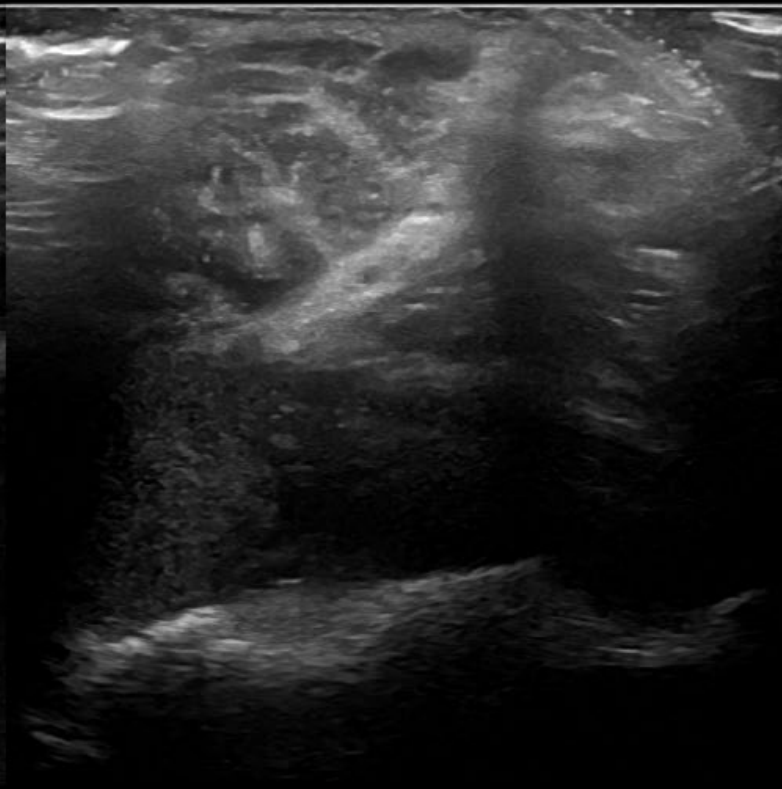
FR 15
AO% 100

LOGIQ
S8

2
II
4



Left ant elb sax



Left ant elb sax

CHI
Frq 12.0
- Gn 55
S/A 3/3
- Map A/0
D 5.0
- DR 66


2
II
4

Left Anterior Elbow SAX

Results/Treatment Plan

Clinical Pearls

1. Don't be afraid to compress ("Heel-Toe" or "Rocking")
2. Work within the patient's ROM
3. Use Real-Time imaging to find Joint line or appropriate acoustic window



<https://www.youtube.com/watch?v=RskrEsAGzec&t=3s>

Tibio-talar imaging complexities

NAVIGATING SEVERE OSSEOUS
IRREGULARITIES IN A 65 YEAR OLD MALE
WITH MODERATE TYPE A HEMOPHILIA

Bruno U.K. Steiner, PT, DPT, LMT, RMSK

Washington Center for Bleeding Disorders, Seattle, WA

Physical Therapy and MSKUS Program Manager

Instructor, UCSD: MSKUS in Hemophilia

Clinical Instructor: UW Department of Rehabilitation Medicine

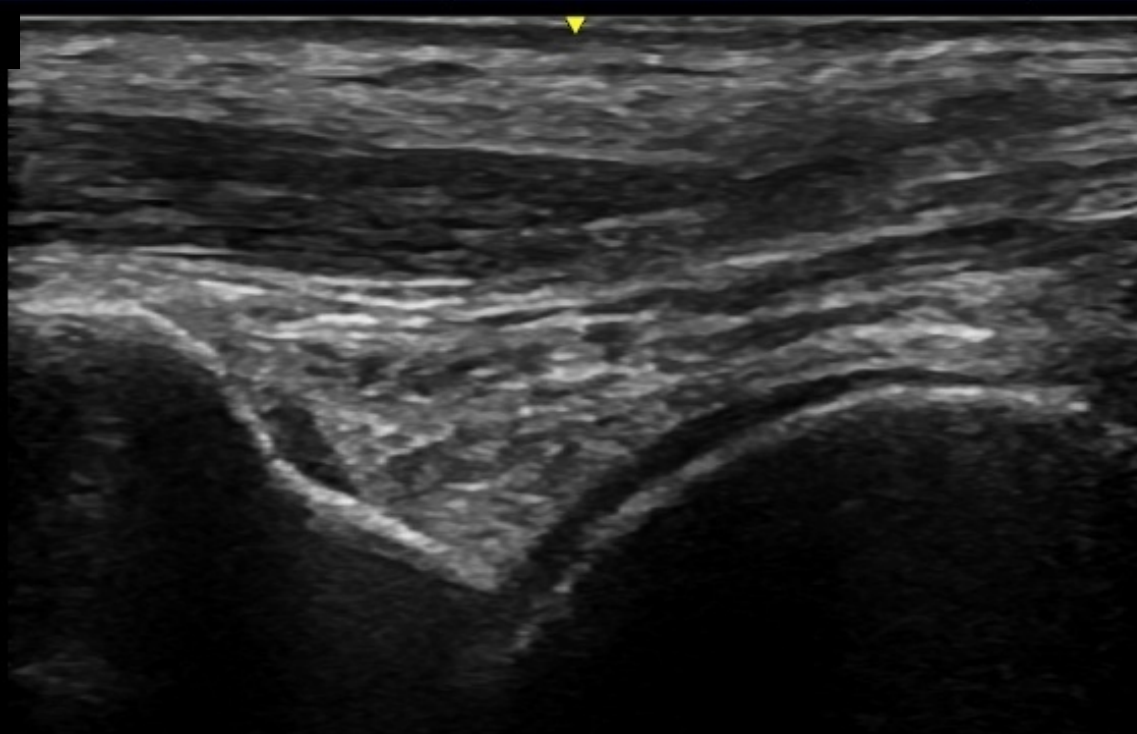
65 y/o male with moderate hemophilia A with L ankle pain

Patient History/Subjective

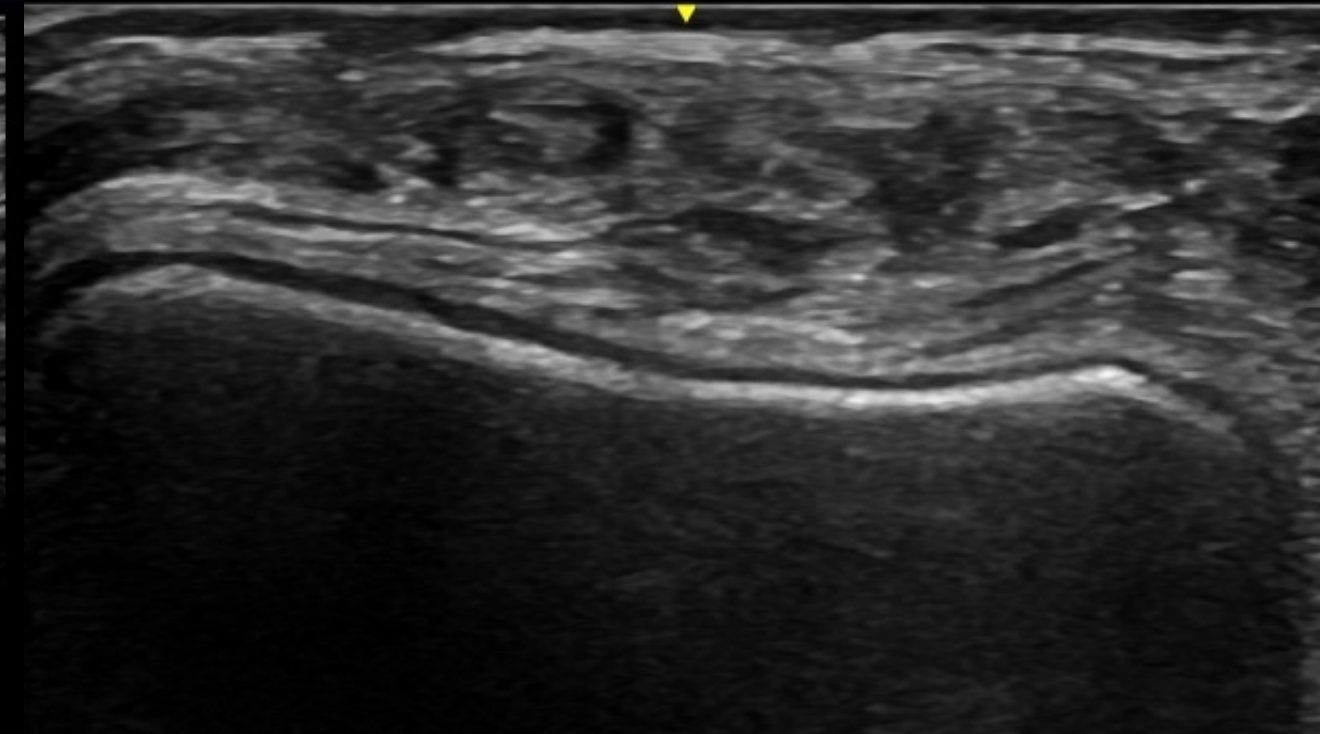
1. Advanced bilateral ankle hemarthropathy
2. Painful catching of left ankle along anterior joint line
3. Chronic complaint of stiffness and ache
4. Doesn't necessarily feel he's suffering hemarthrosis but unsure
5. Interferes with prolonged ambulation
6. Very stiff when he begins motion

Patient Presentation

1. ROM Left ankle: Dorsiflexion 0; plantarflexion 20 (worse than right)
2. Swelling: moderate but diffuse and obscures bony landmarks
3. Gait: compensated and swing phase is affected by lack of dorsiflexion
4. Palpation: TTP to anterior talo-tibial joint line
5. Special tests: manual distraction provides relief
6. Strength: impaired by pain and marked ROM deficit

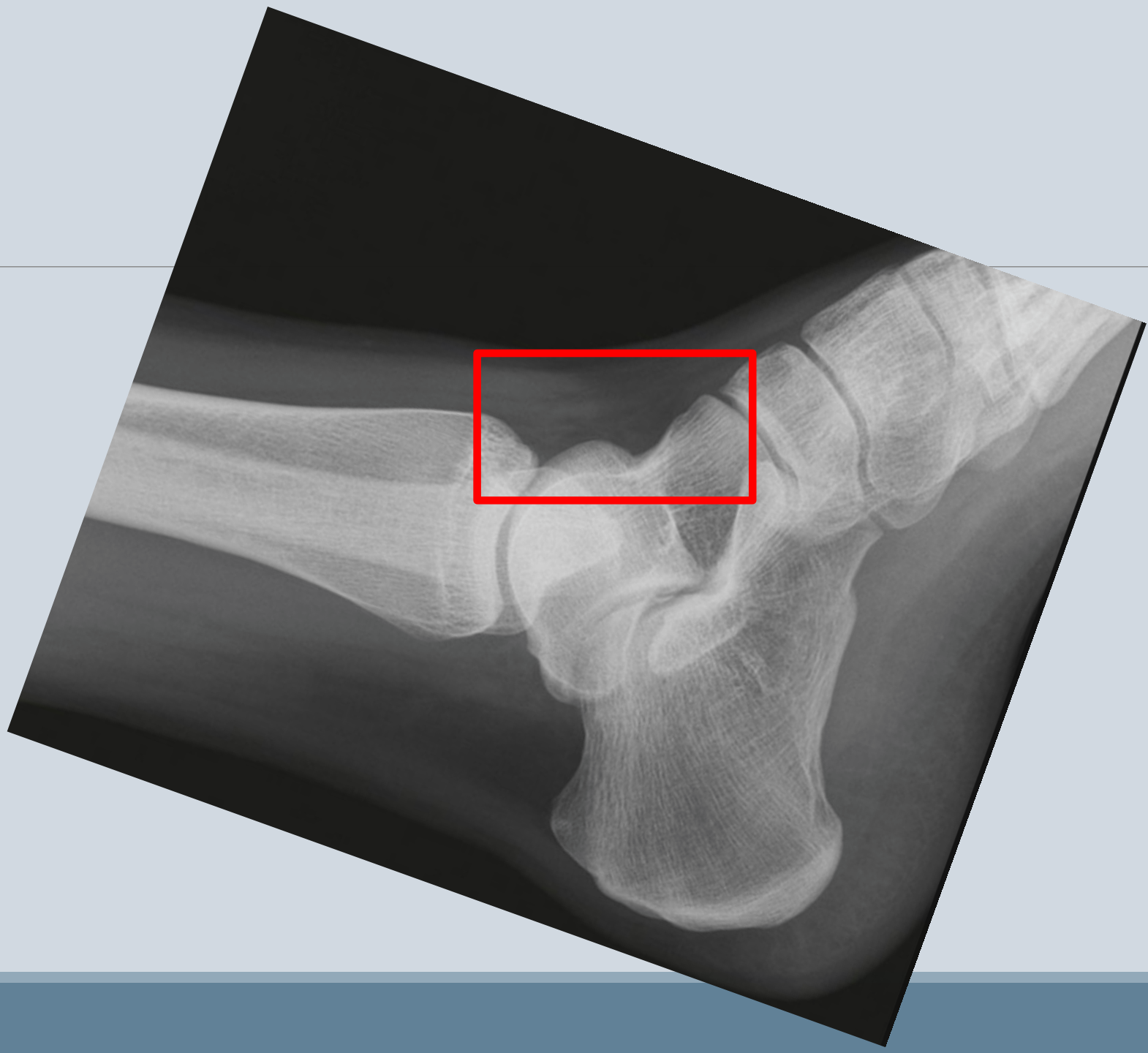


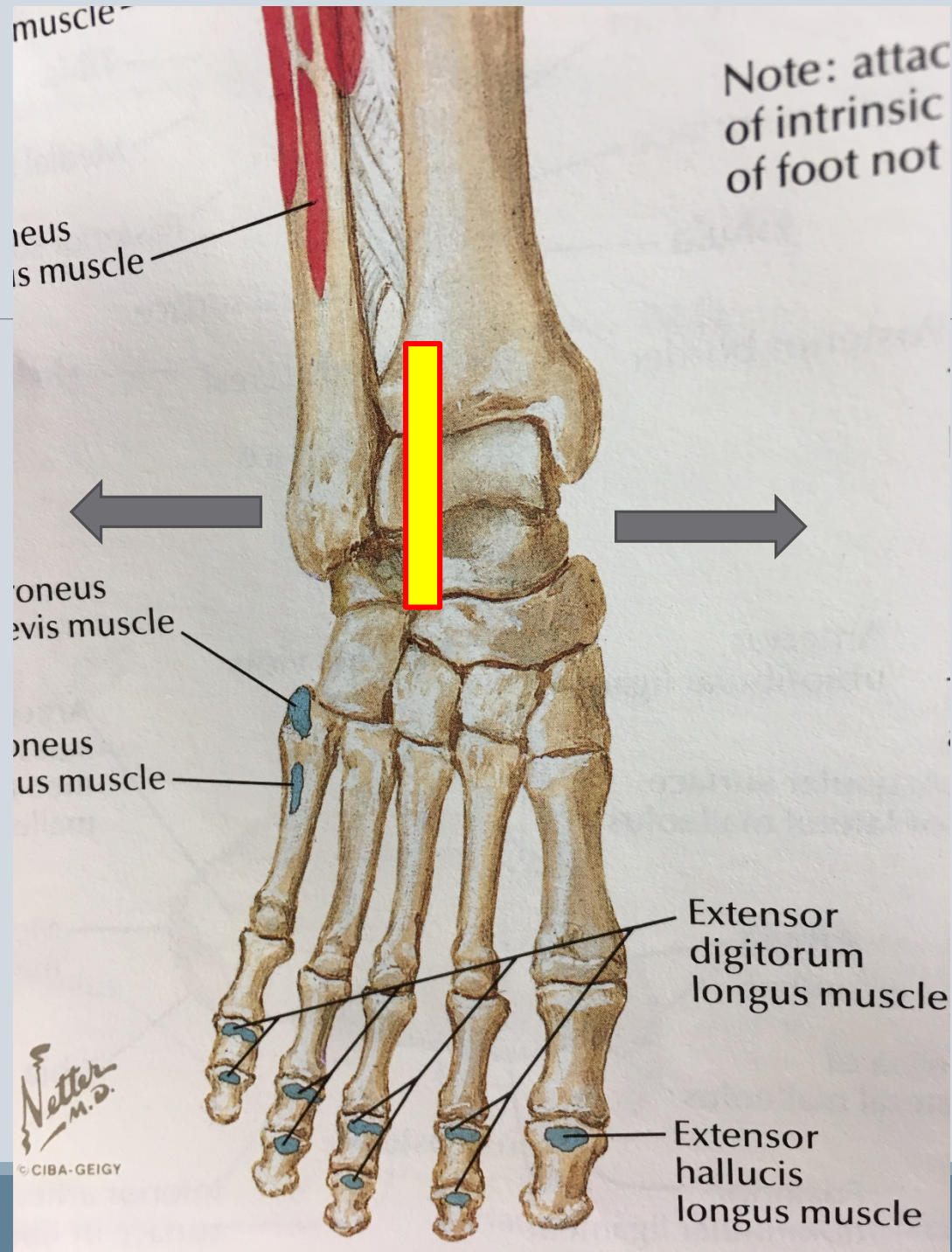
Anterior Ankle LAX

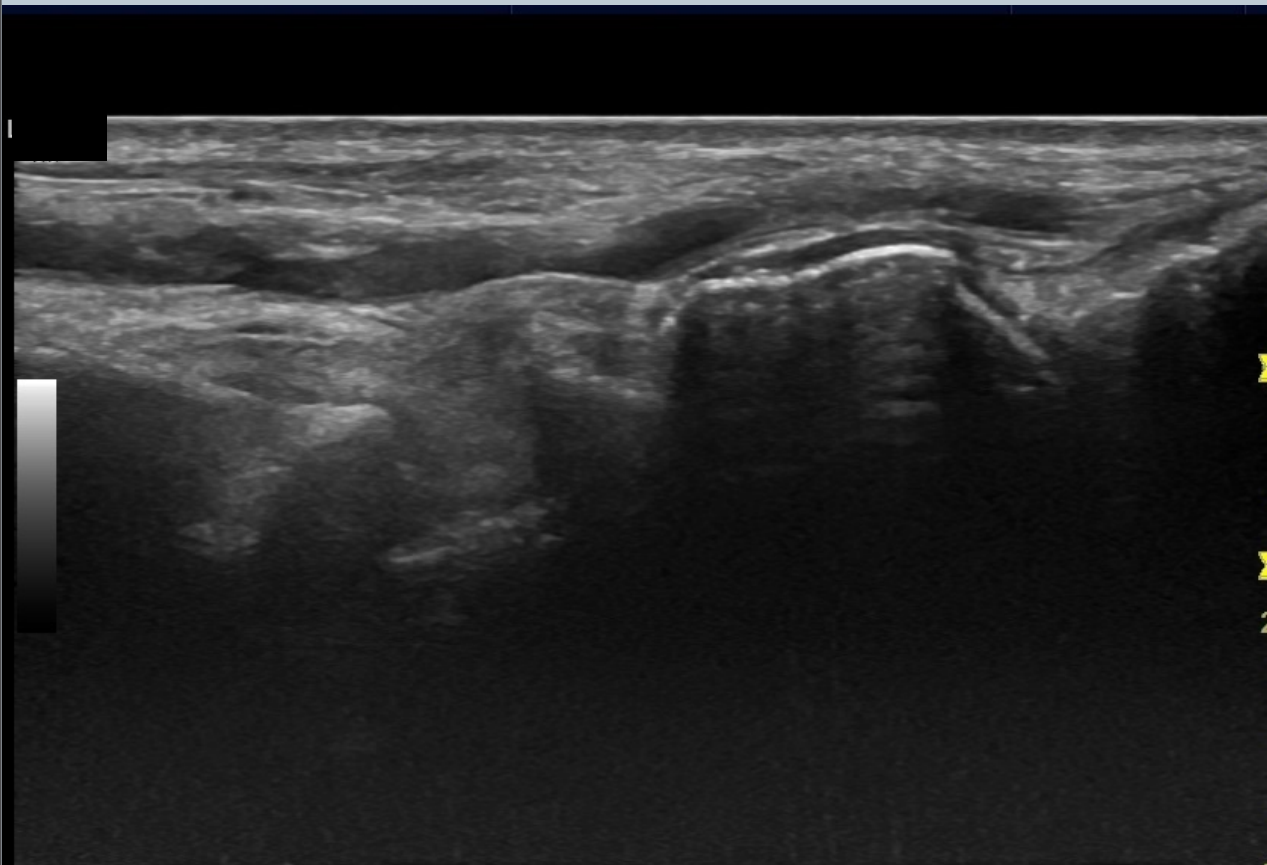


Anterior Ankle SAX

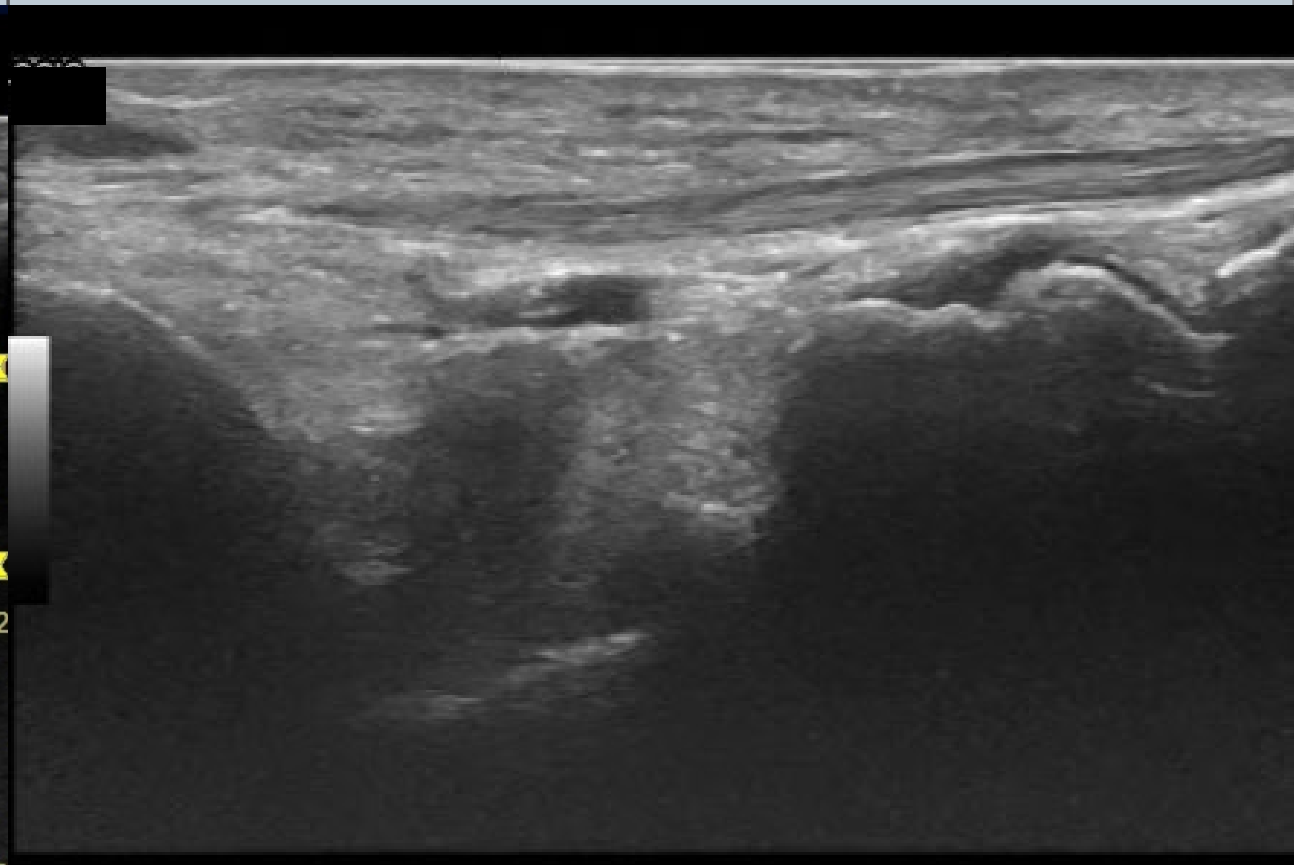
Anterior Ankle Views in LAX and SAX





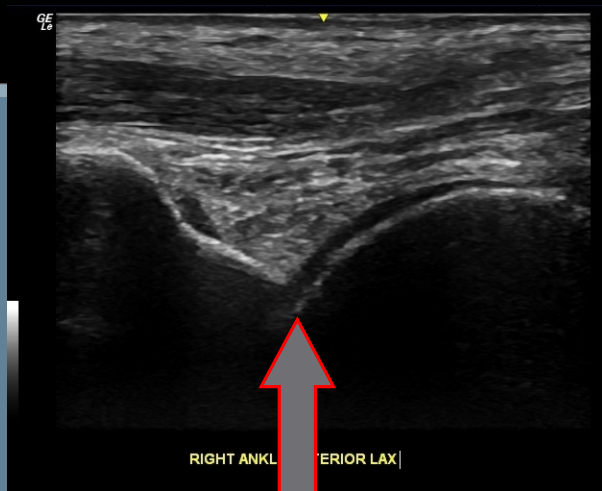


LEFT ANKLE LAX



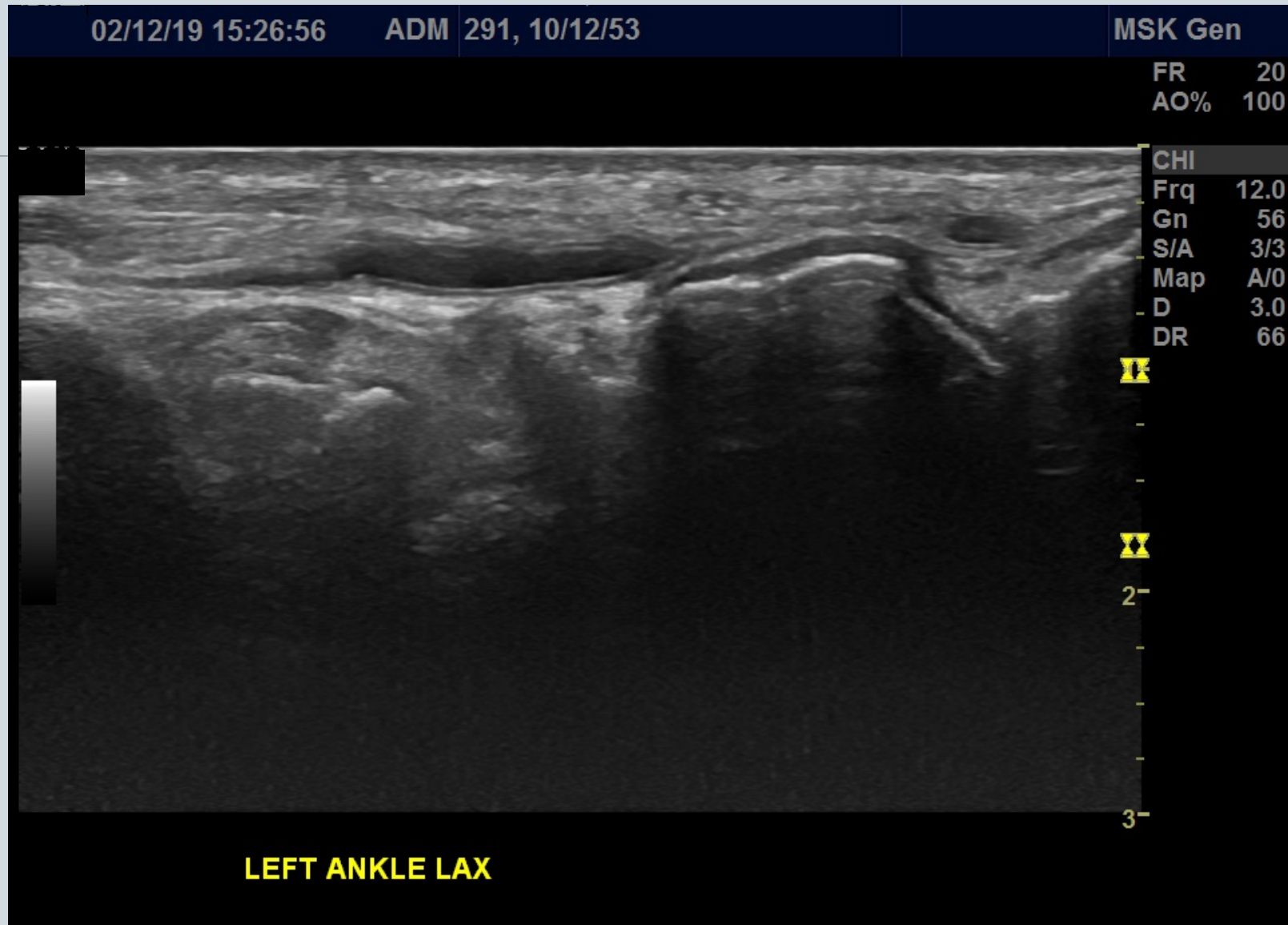RIGHT ANKLE LAX

Bilateral Anterior Ankle LAX



RIGHT ANKLE ANTERIOR LAX

Anterior Ankle LAX



Where's the Ankle joint line/recess?

02/12/19 15:28:13 ADM 291, 10/12/53 MSK Gen



FR 20
AO% 100

CHI
Frq 12.0
Gn 56
S/A 3/0
Map A/0
D 3.0
DR 66

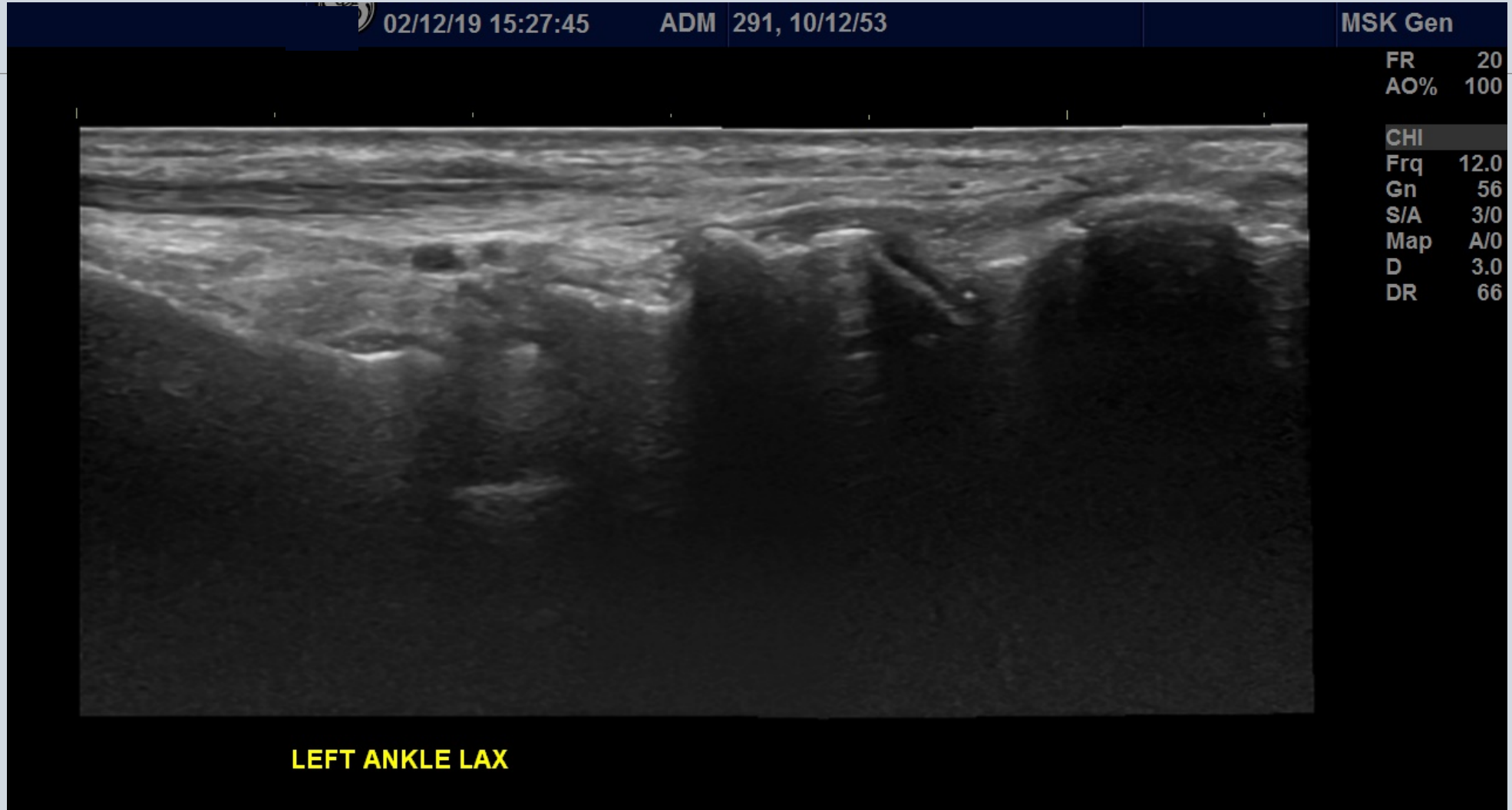II

2-

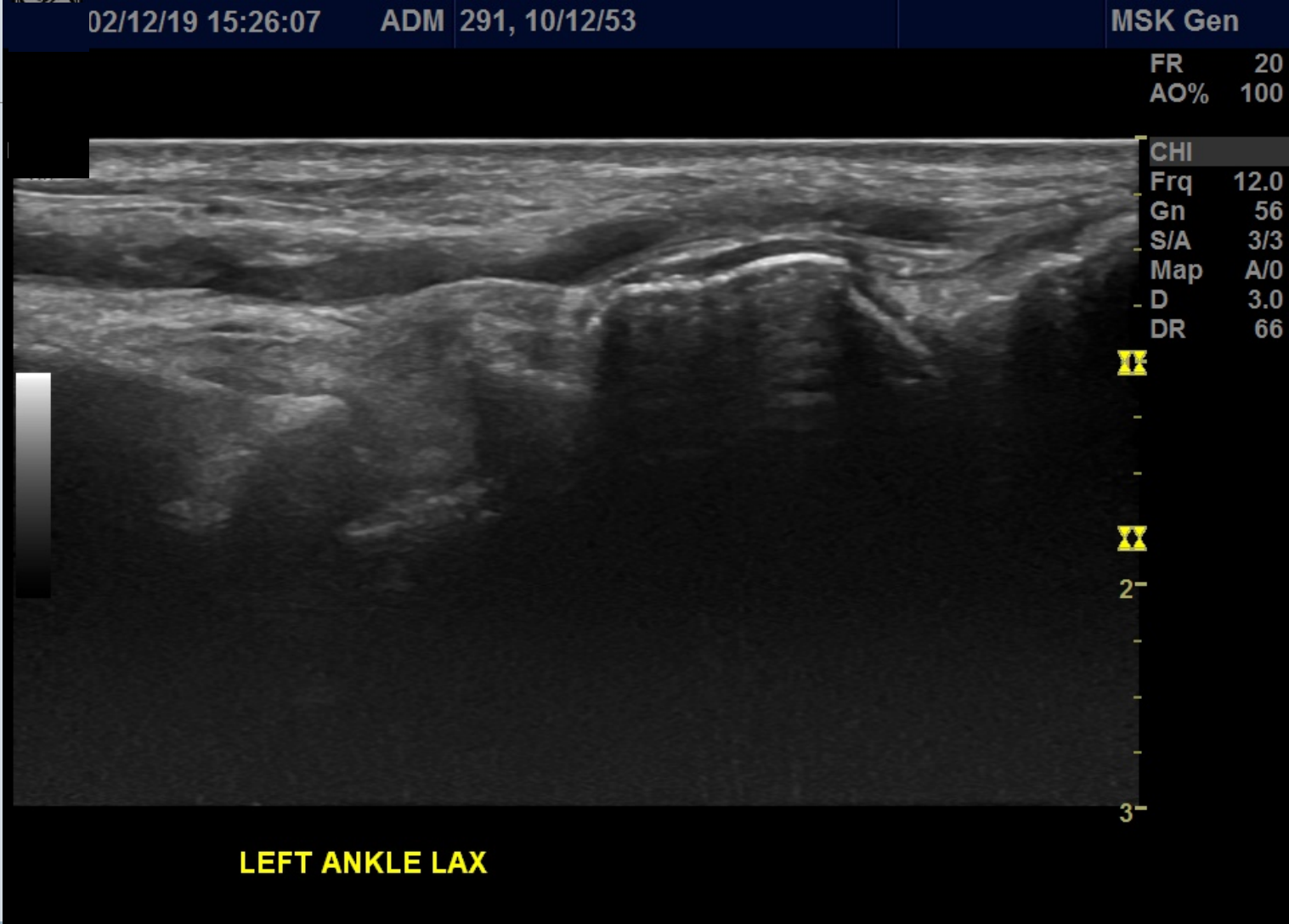3-

LEFT ANKLE LAX

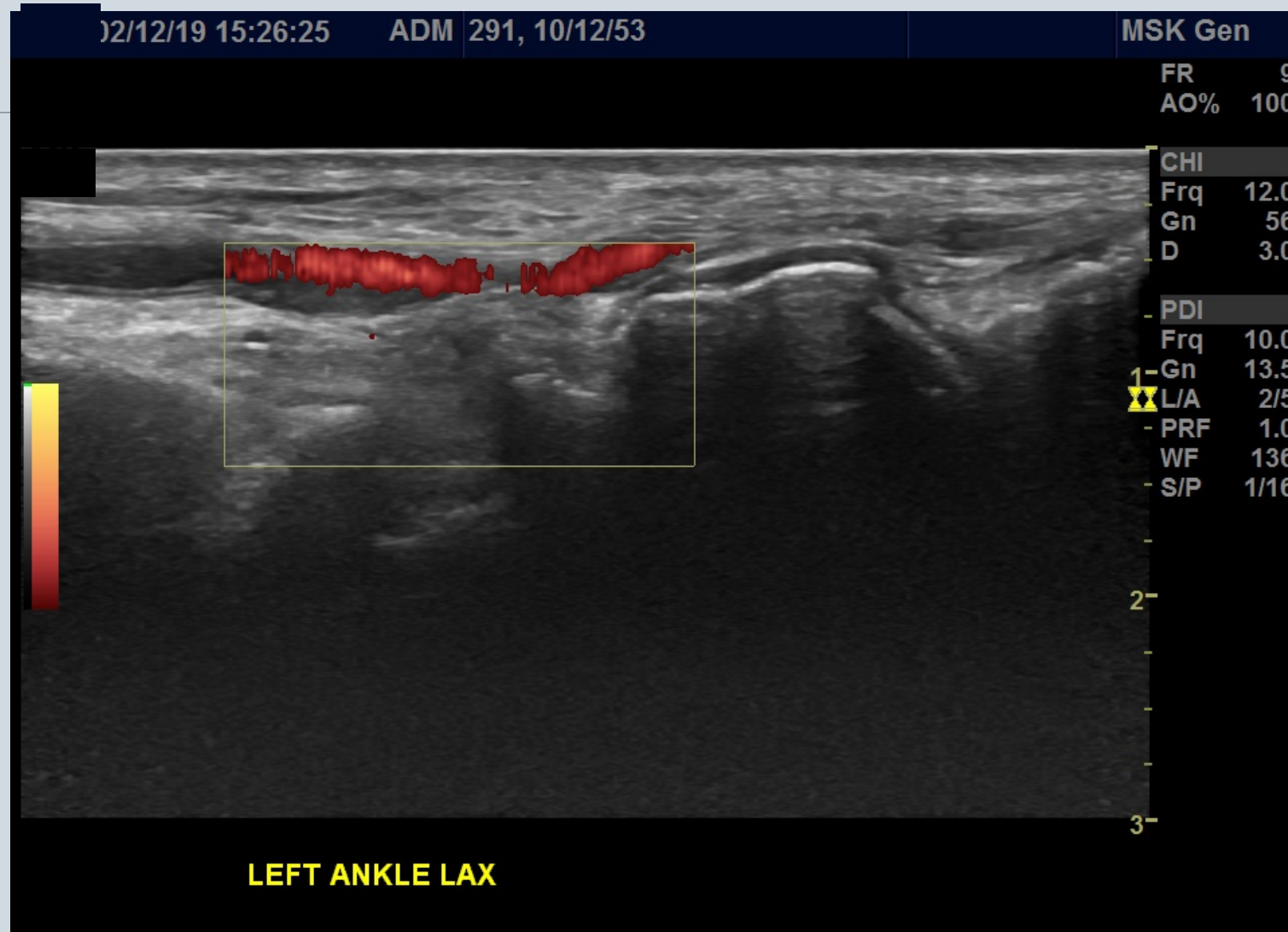
Panorama view Anterior Ankle LAX



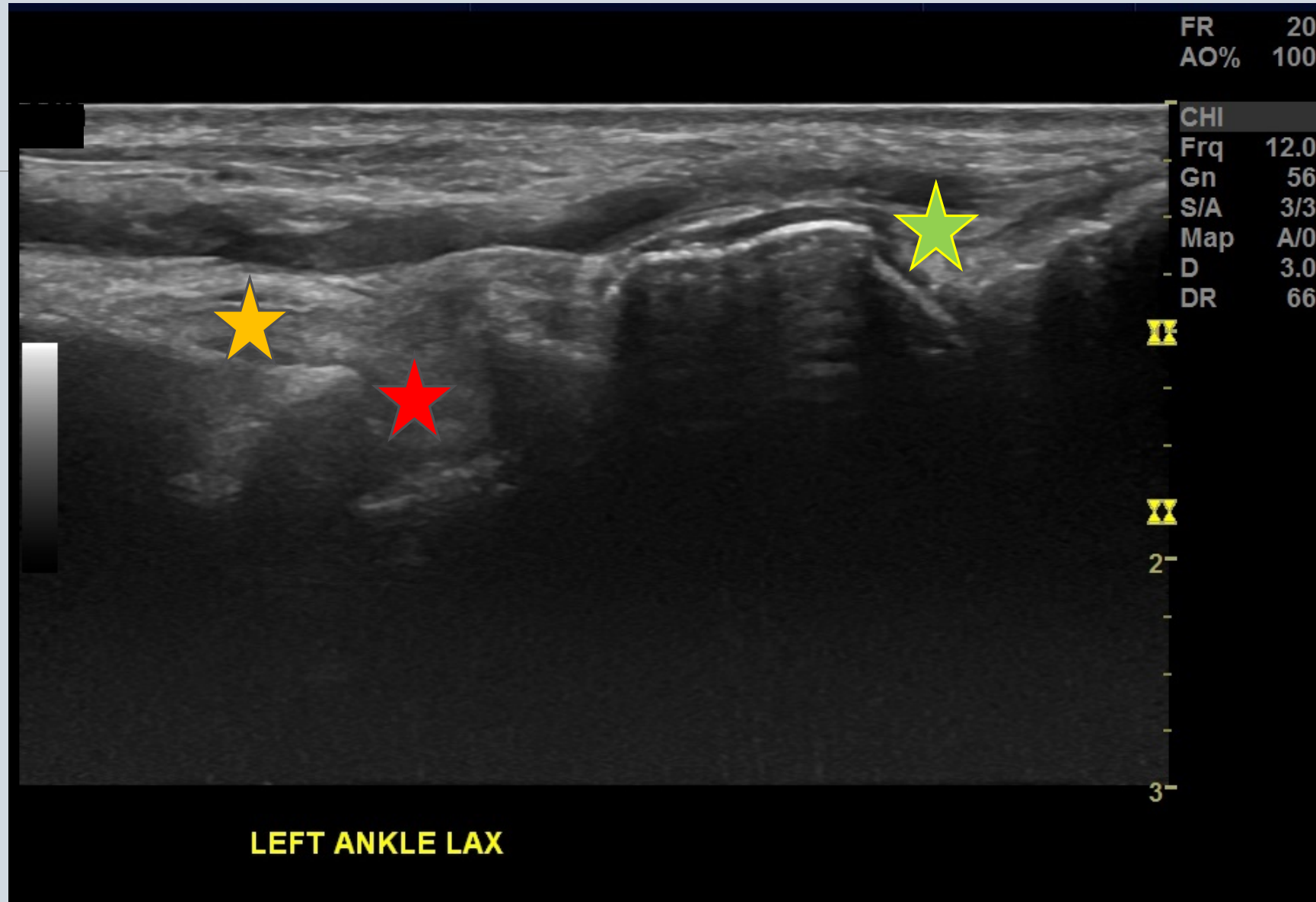
Panorama of Anterior Left Ankle LAX



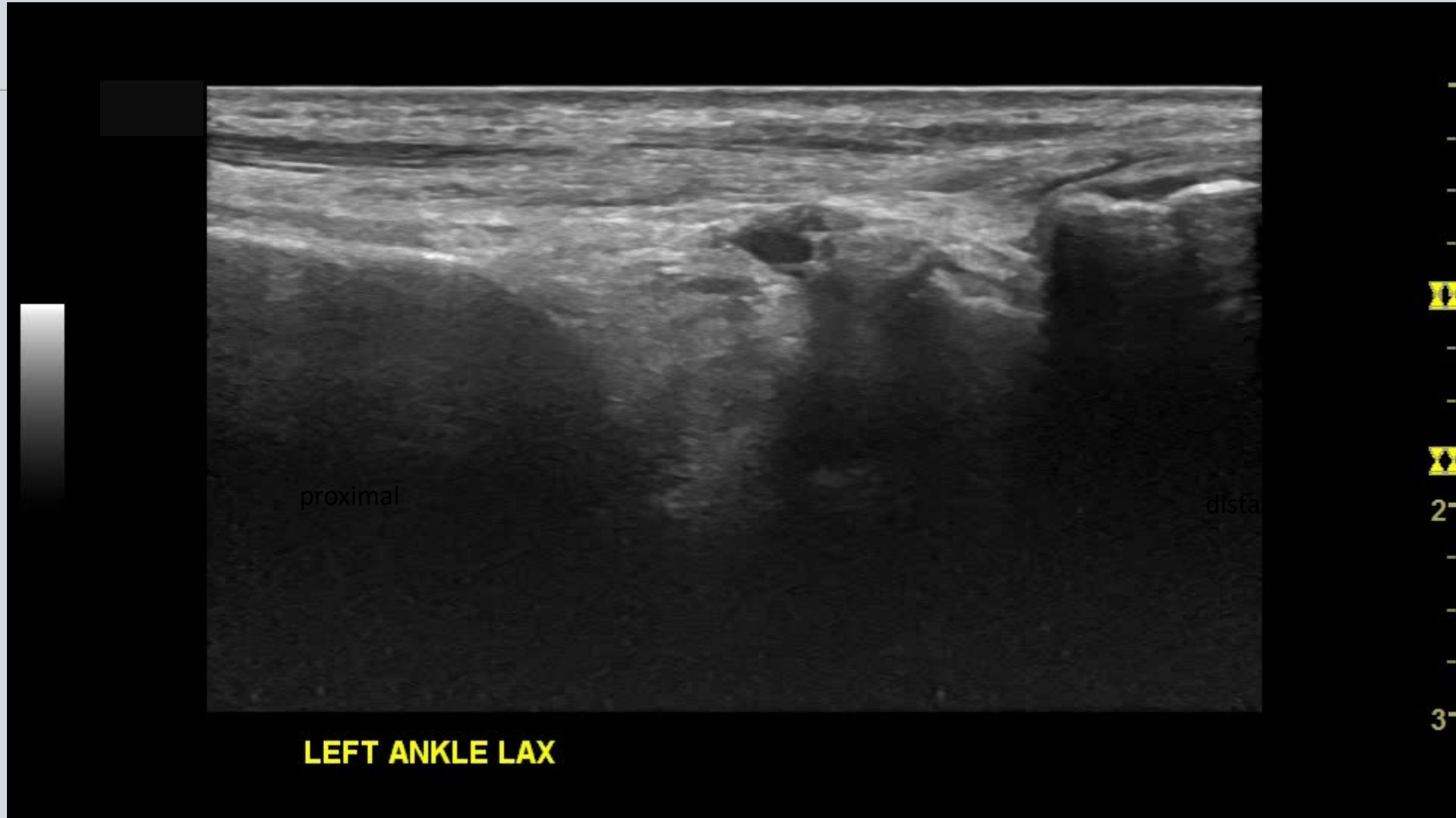
Panorama of Anterior Left Ankle LAX



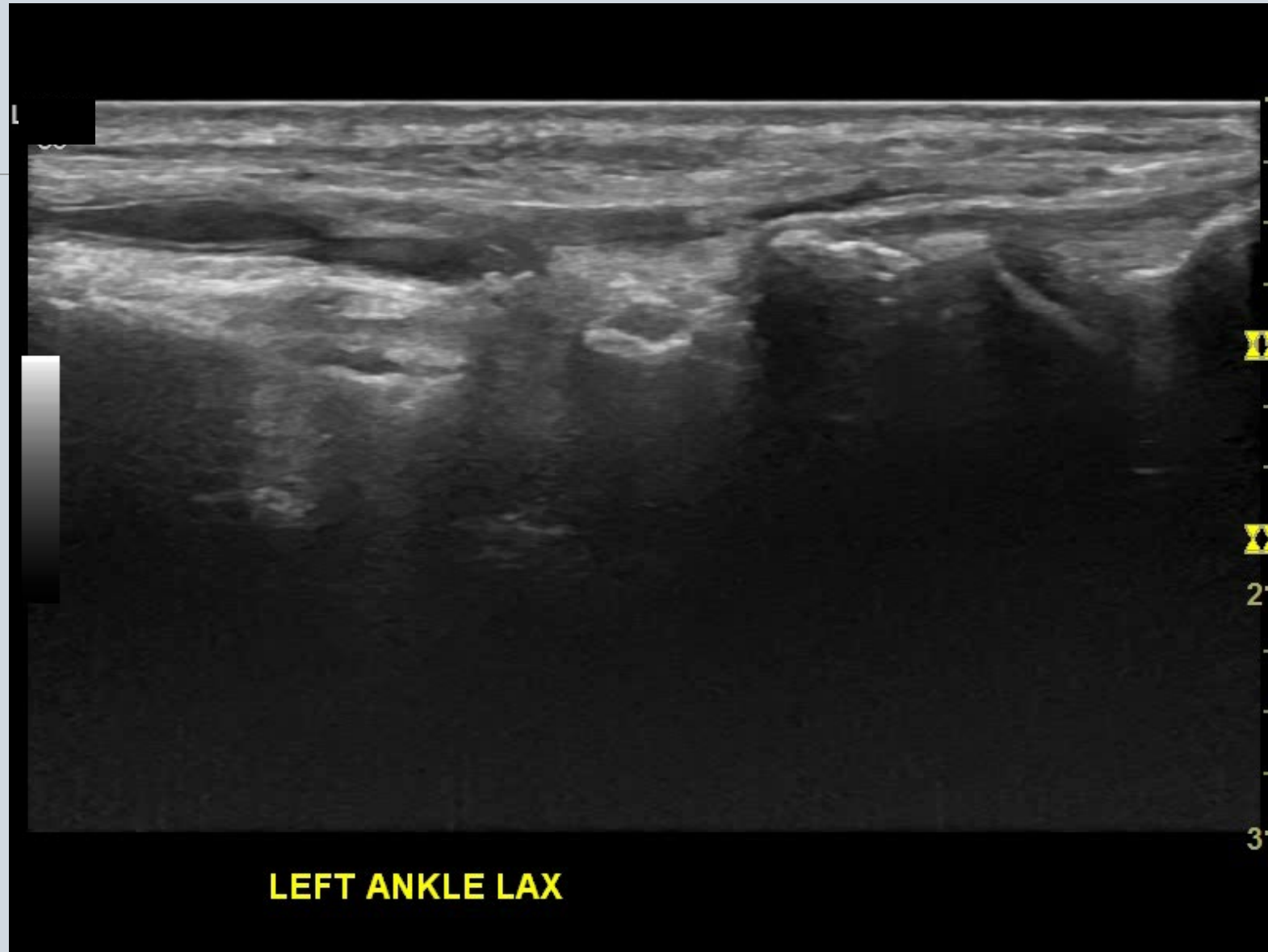
Anterior Ankle LAX Panorama



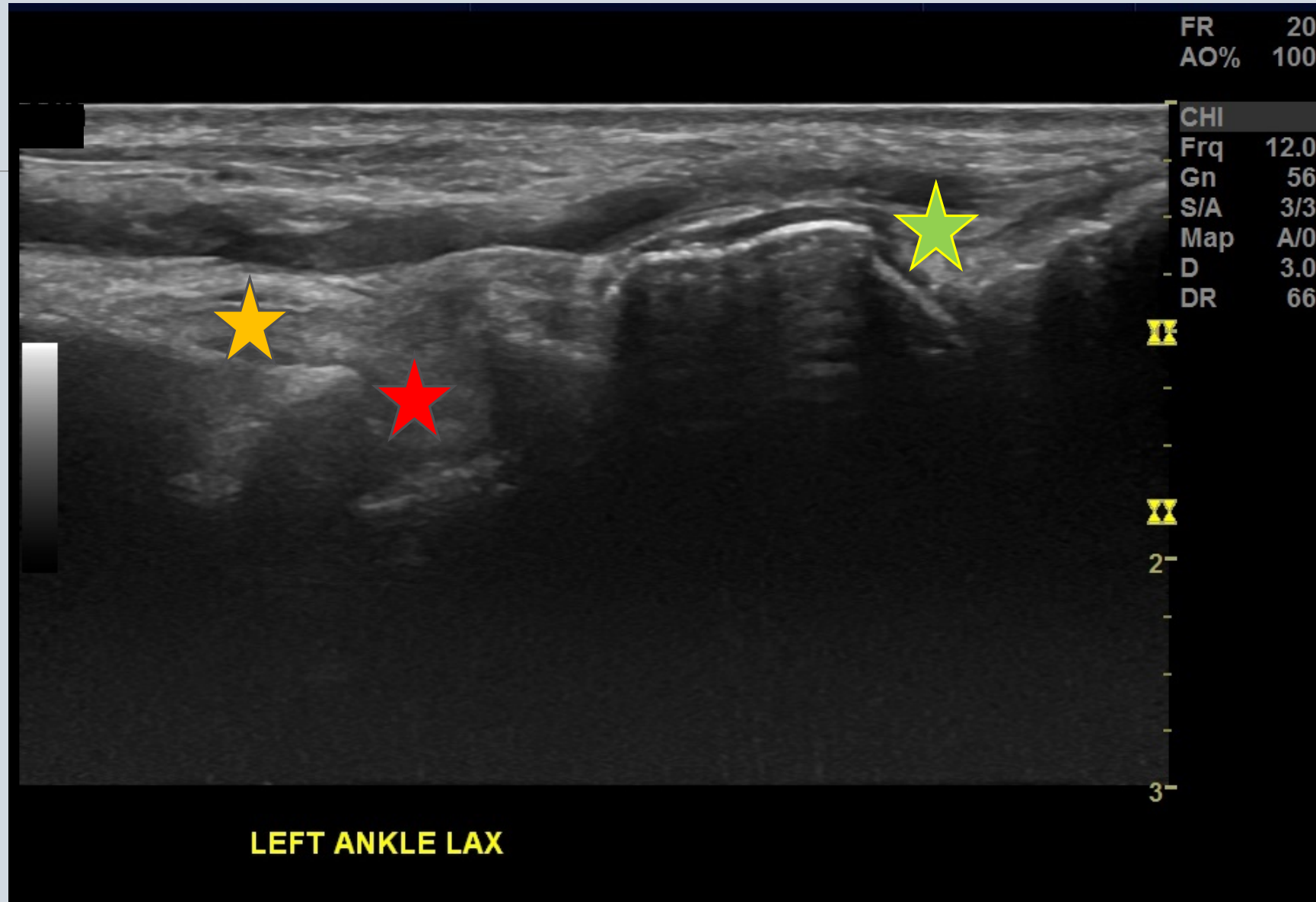
Introduce Dorsi/Plantarflexion to differentiate



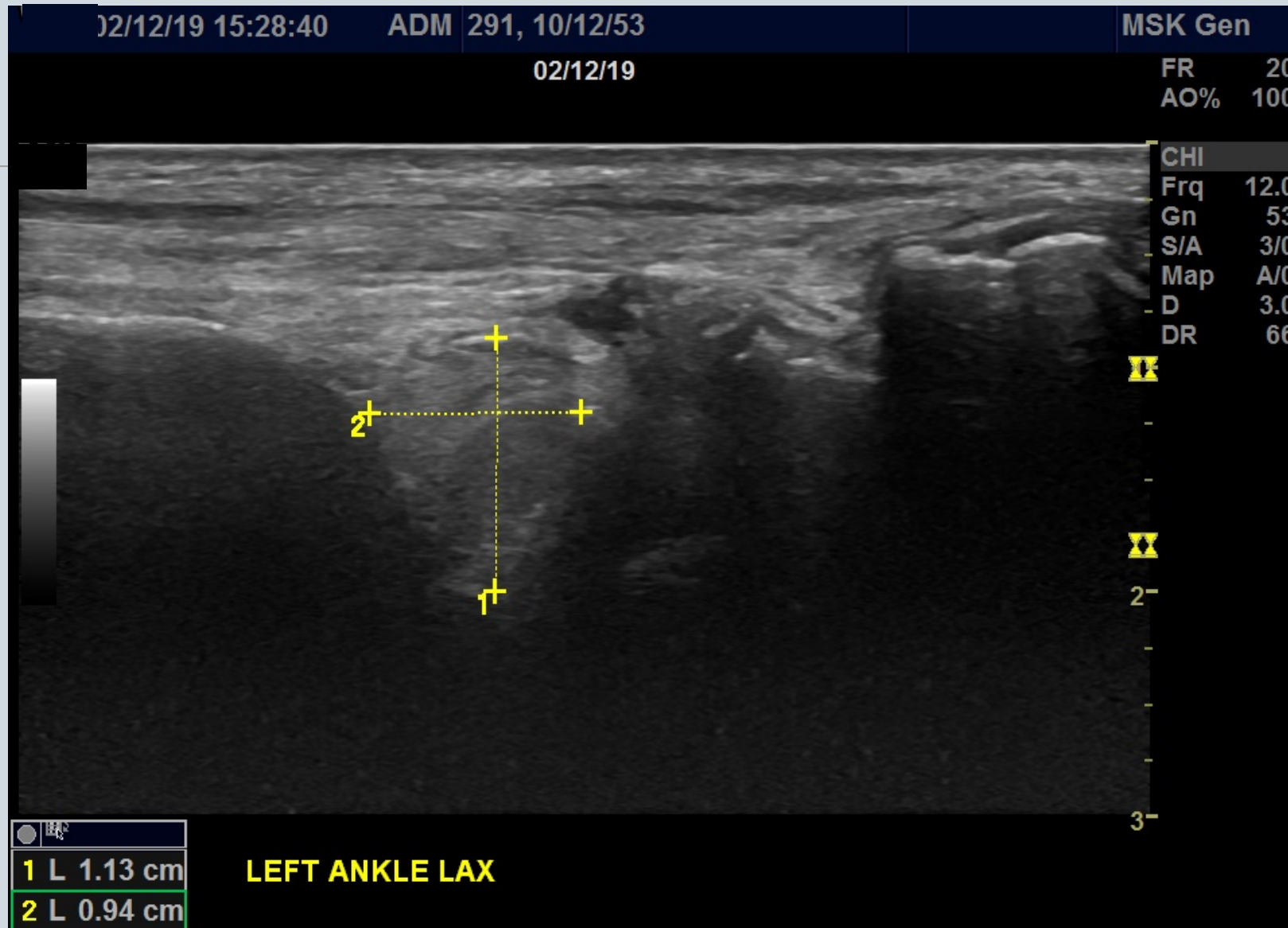
Active Dorsiflexion



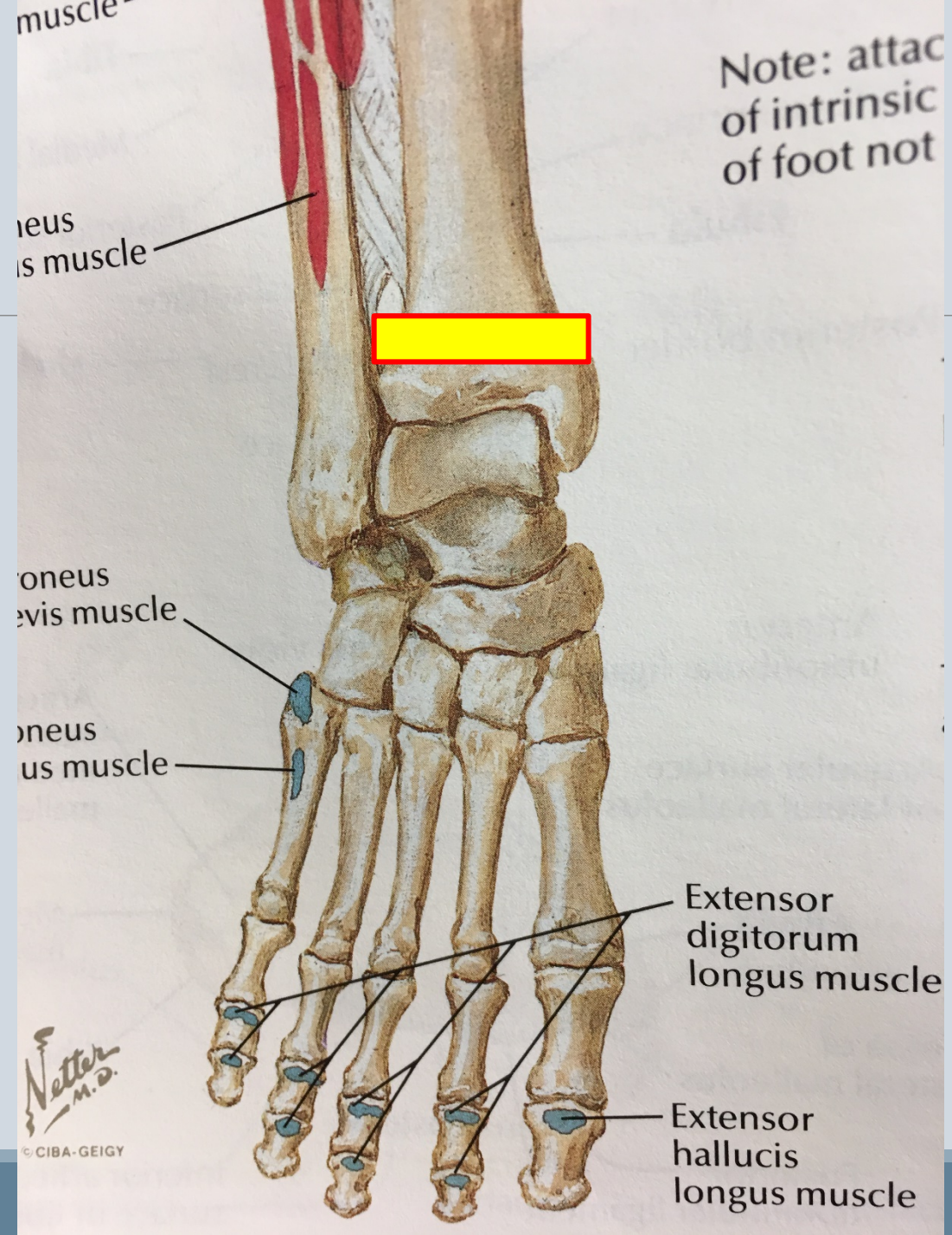
Anterior Ankle LAX Panorama



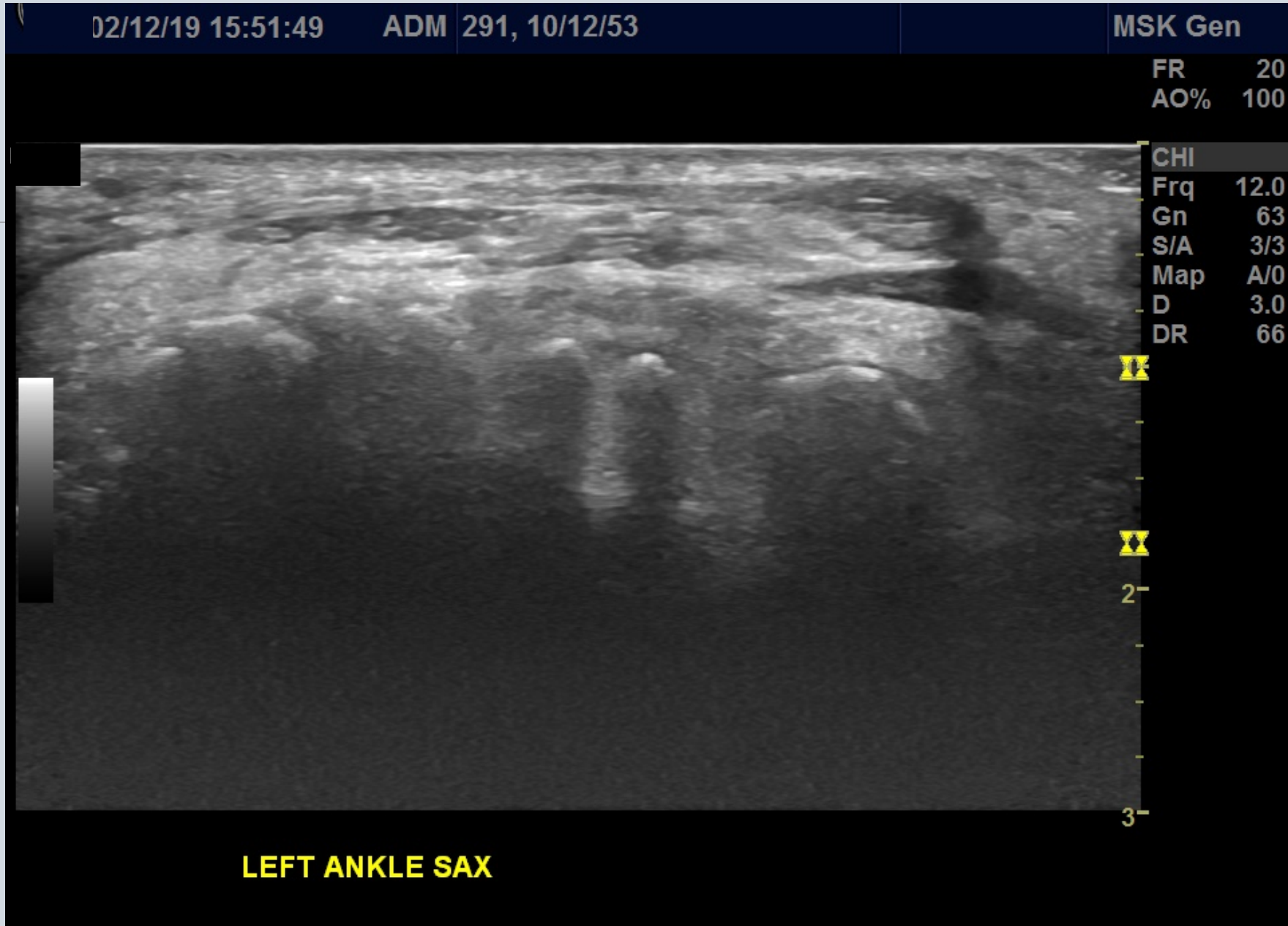
Distal Tibial Erosion



V



Distal
Tibia
SAX



02/12/19 15:30:06

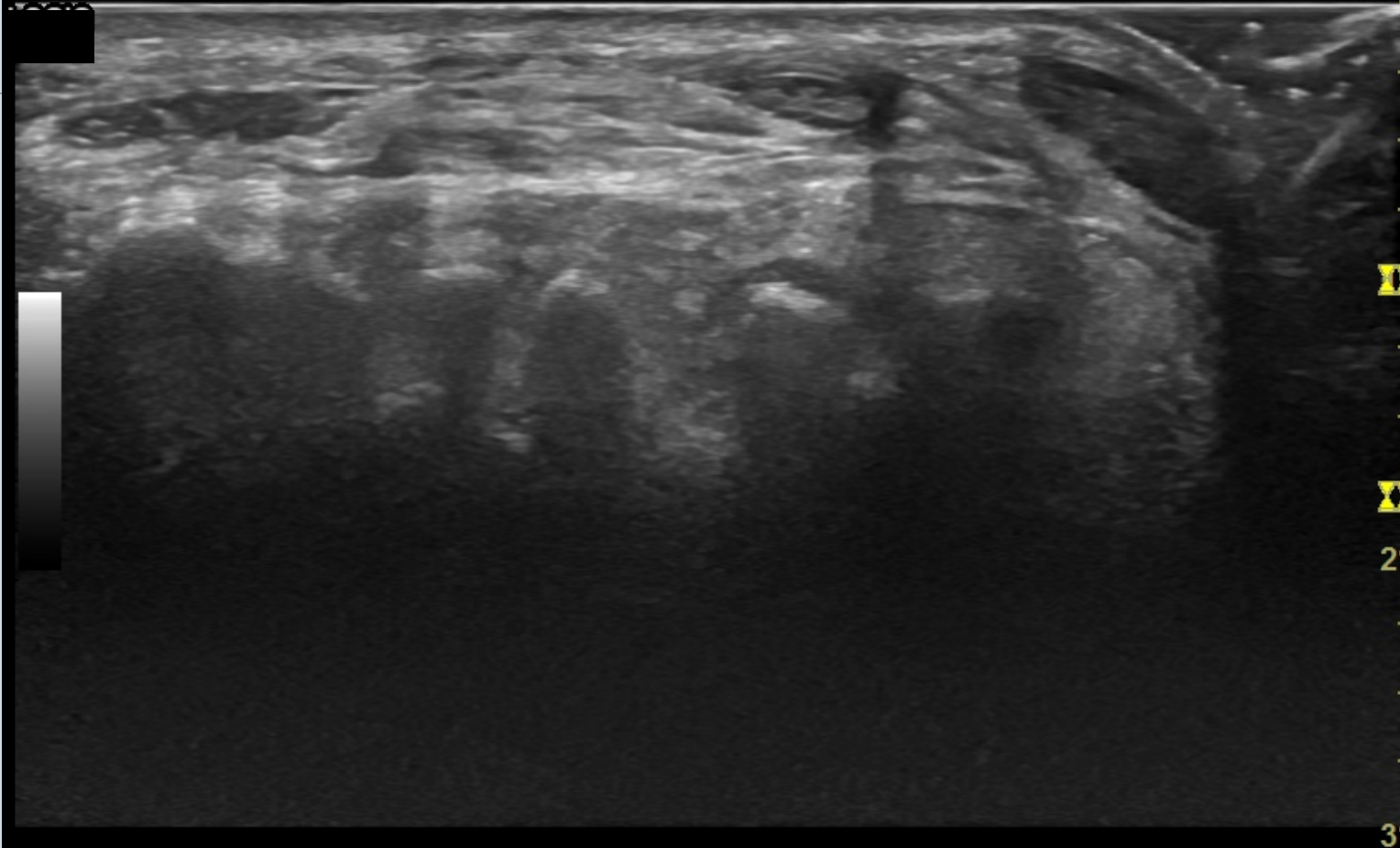
ADM 291, 10/12/53

MSK Gen

FR 20
AO% 100

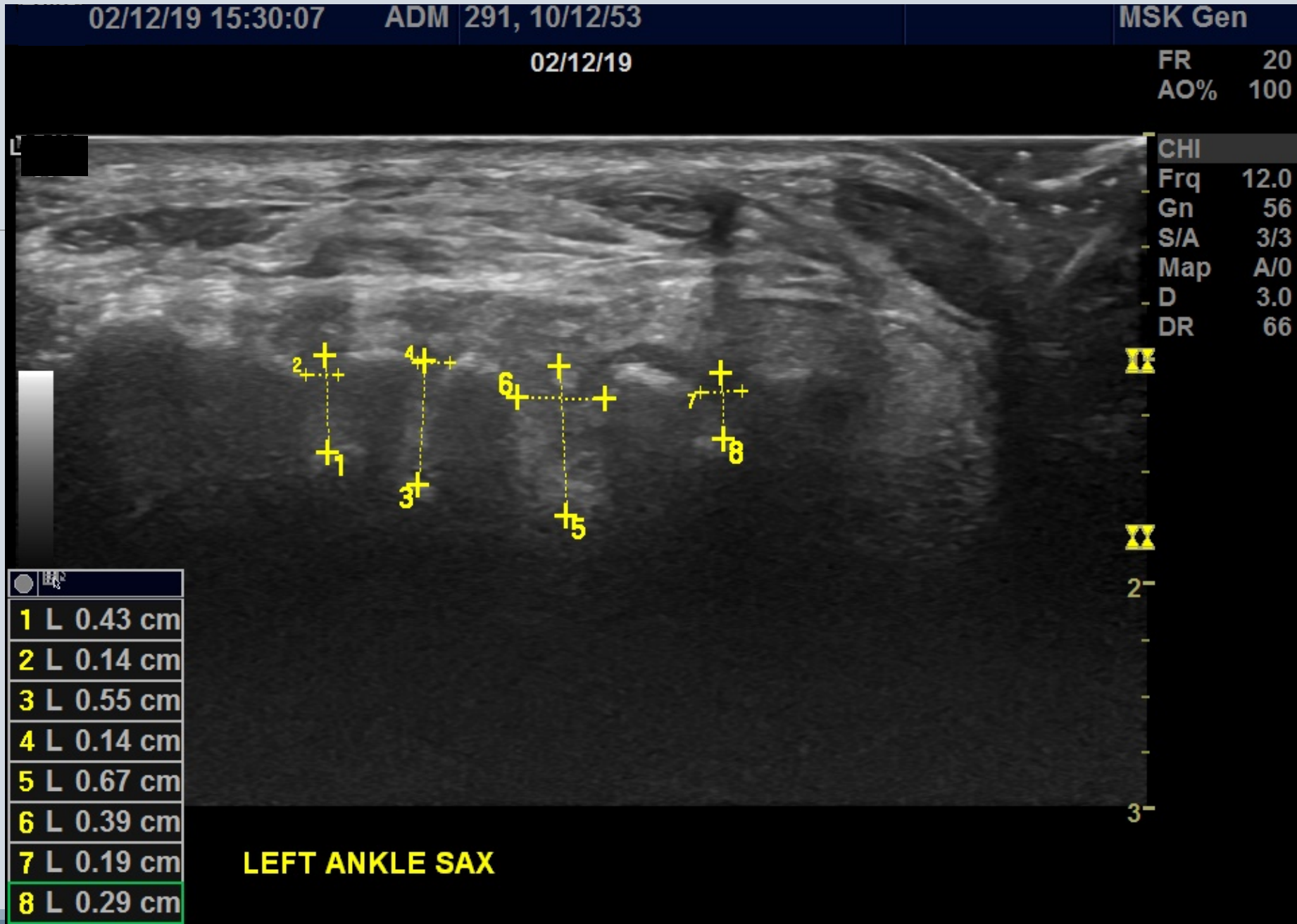
CHI
Frq 12.0
Gn 56
S/A 3/3
Map A/0
D 3.0
DR 66

Distal
Tibia
SAX

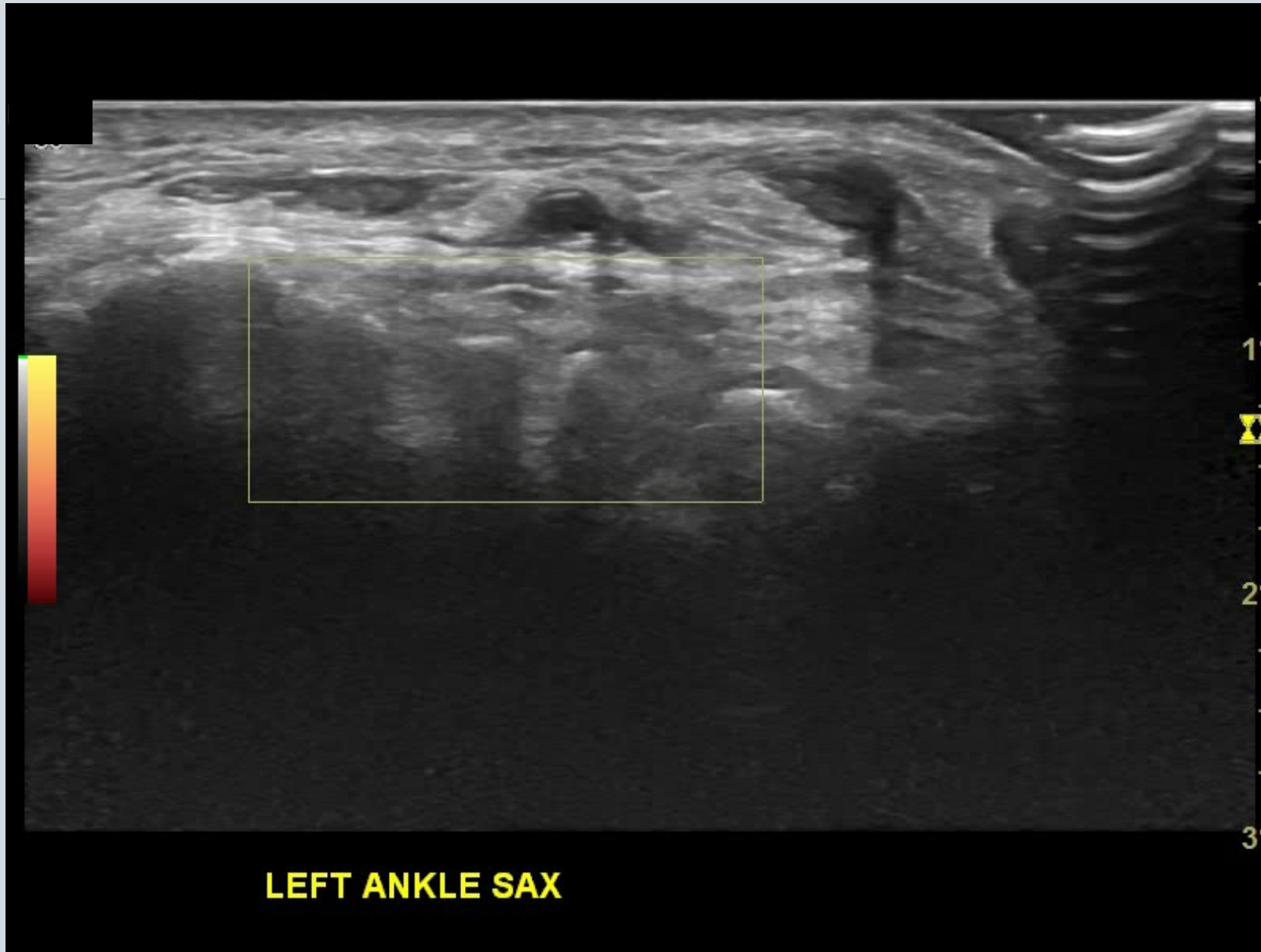

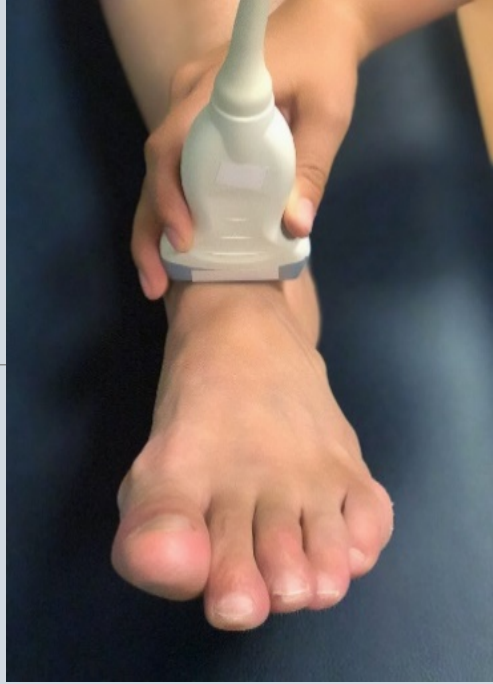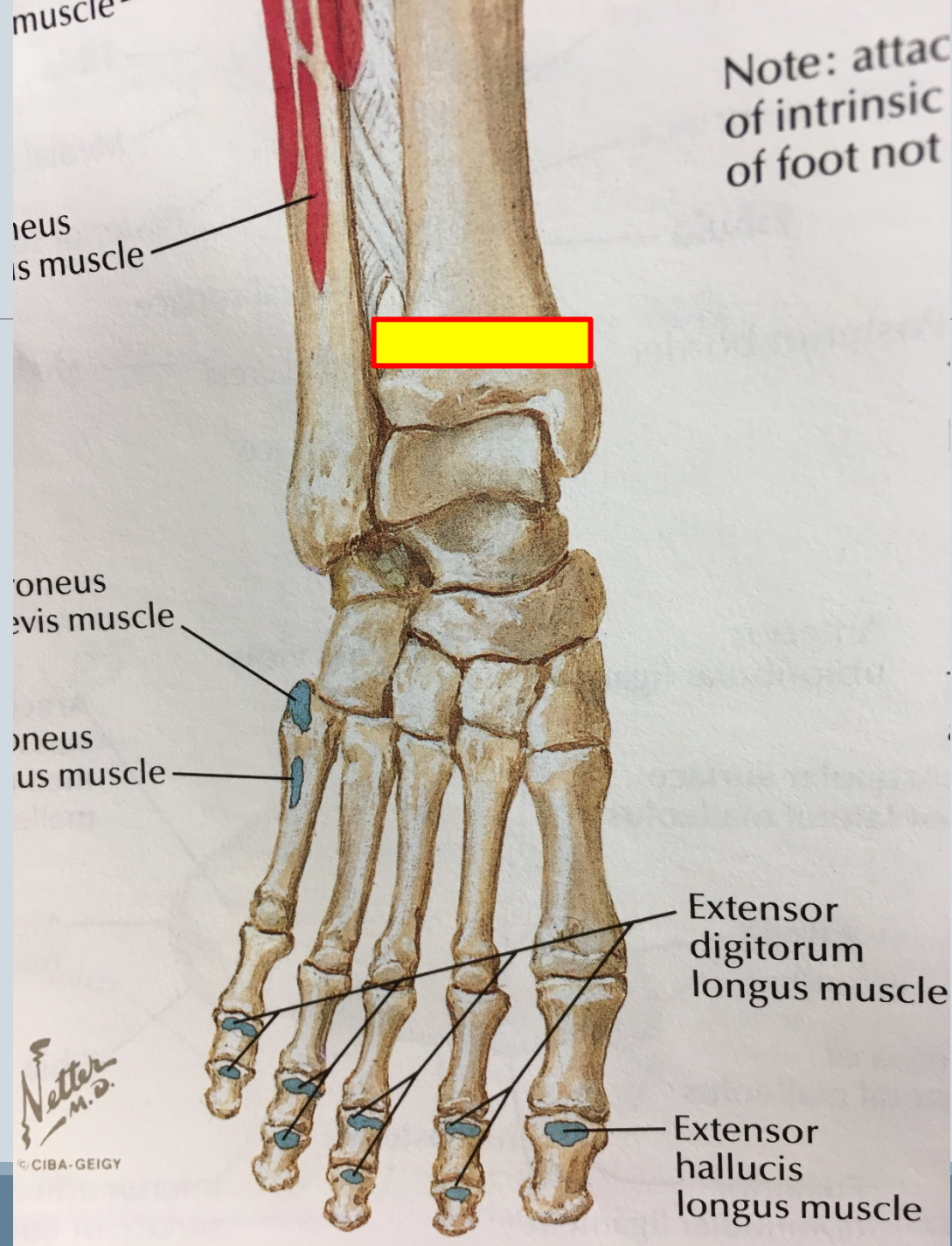
LEFT ANKLE SAX

Distal Tibia Tibia SAX

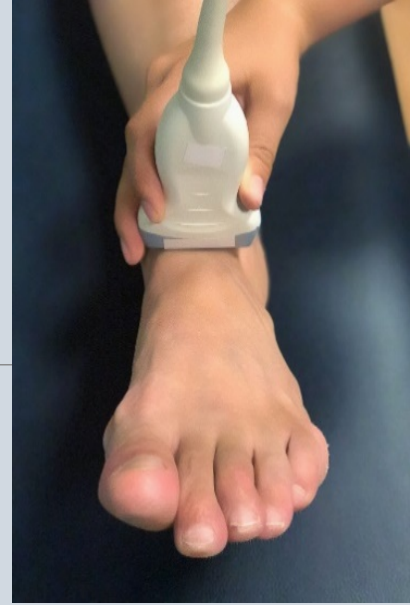
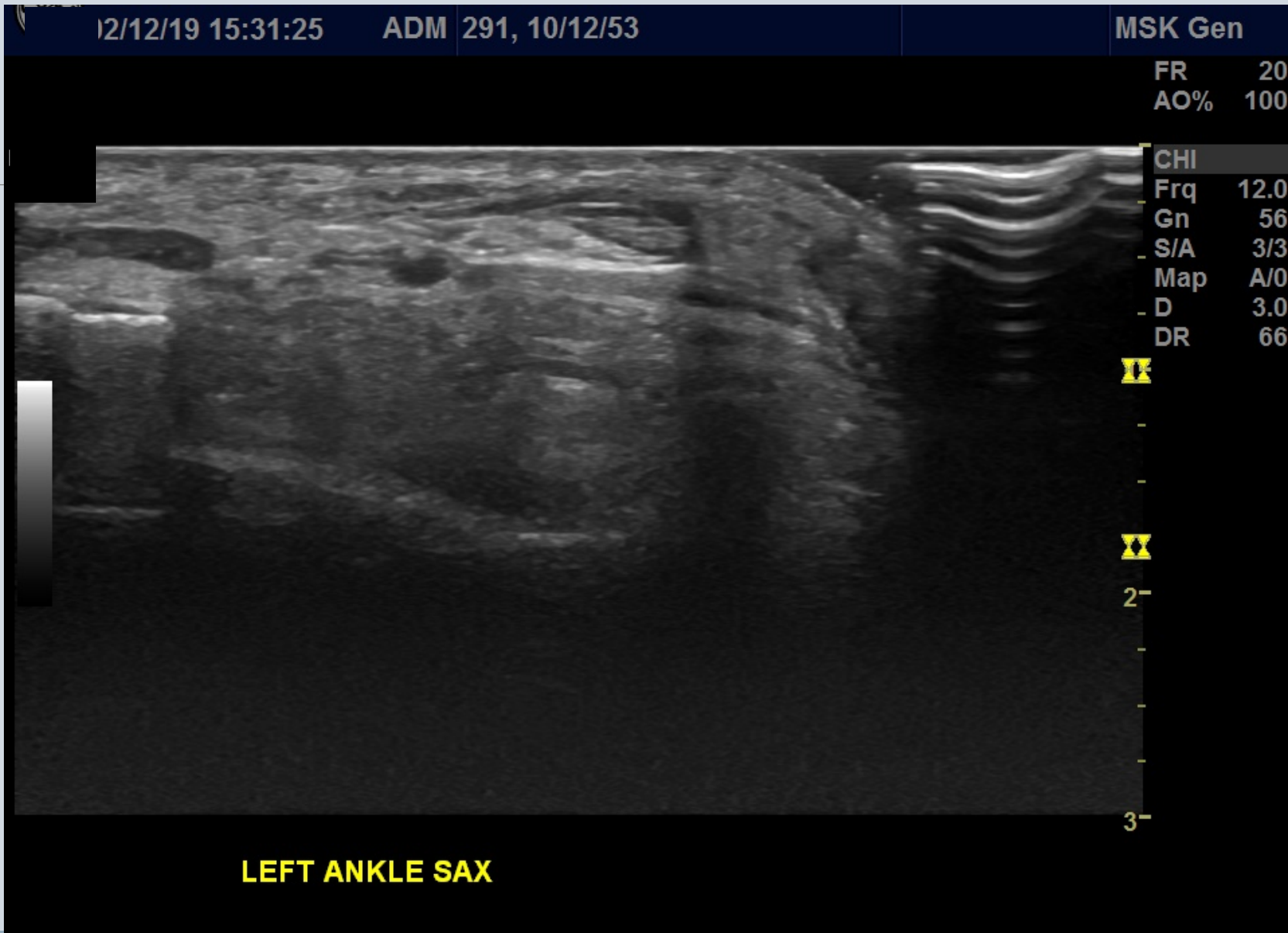
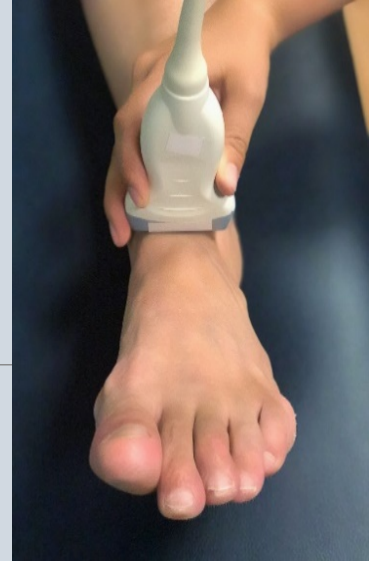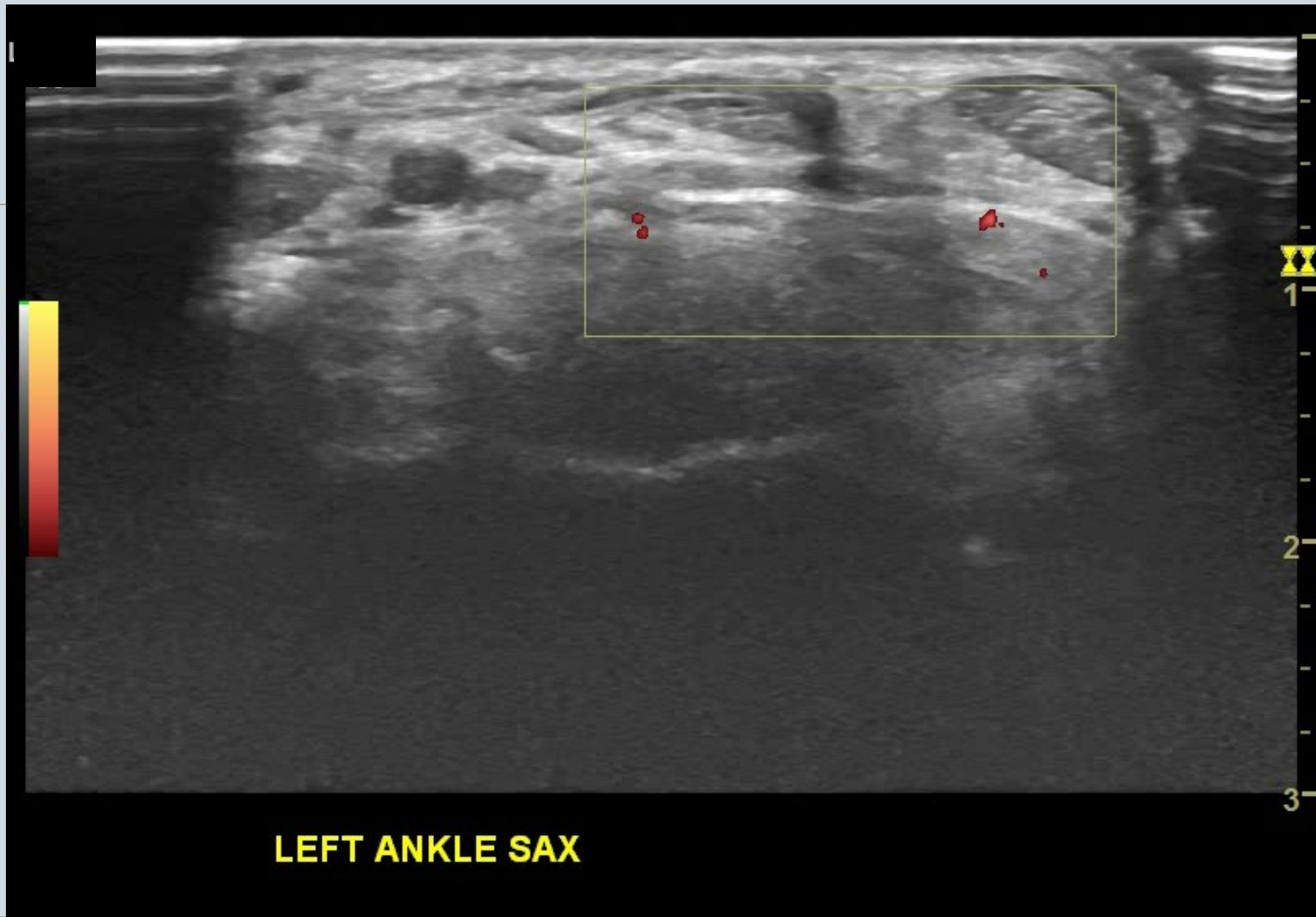
Distal
Tibia
SAX





Left Ankle
SAX
Talus





02/12/19 15:31:25

ADM 291, 10/12/53

MSK Ge

FR
AO%

CHI
Frq
Gn
S/A
Map
D
DR

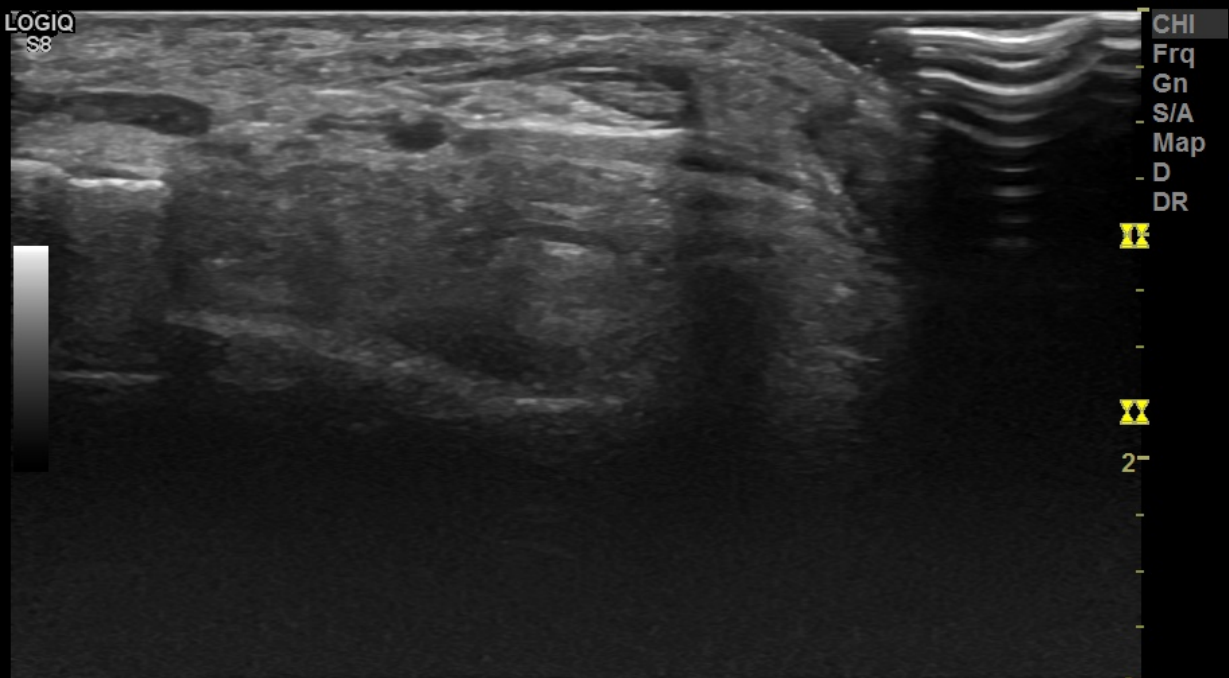
II

II

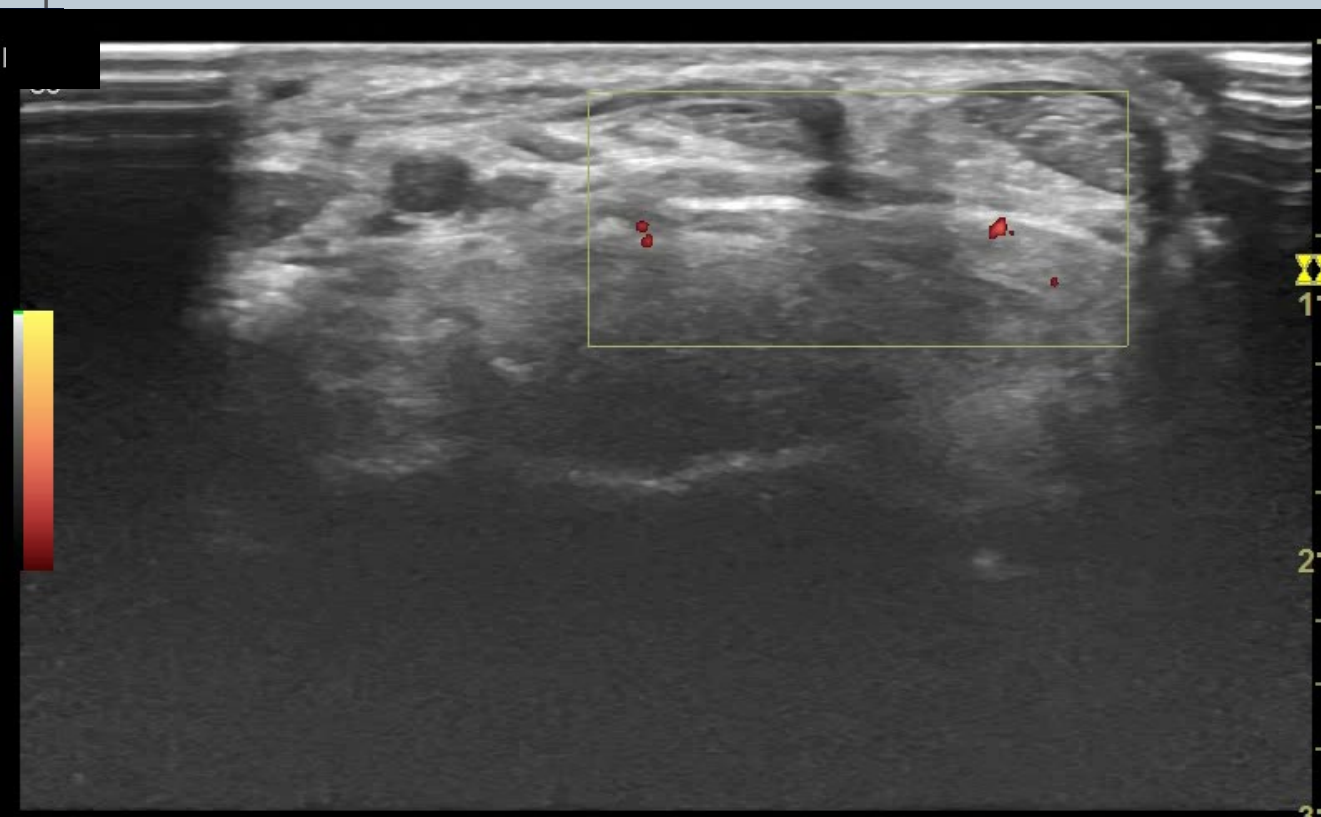
2-

3-

LOGIQ
S8



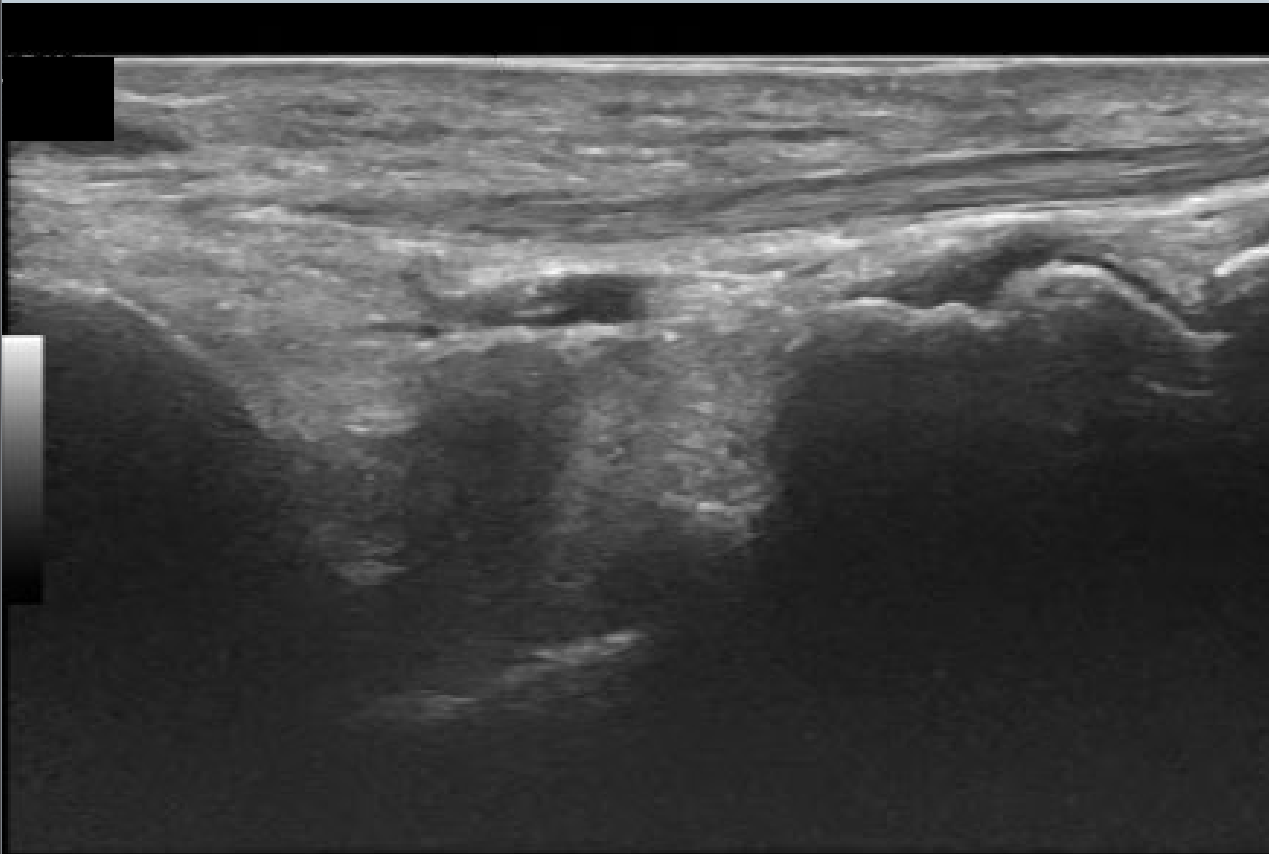
LEFT ANKLE SAX



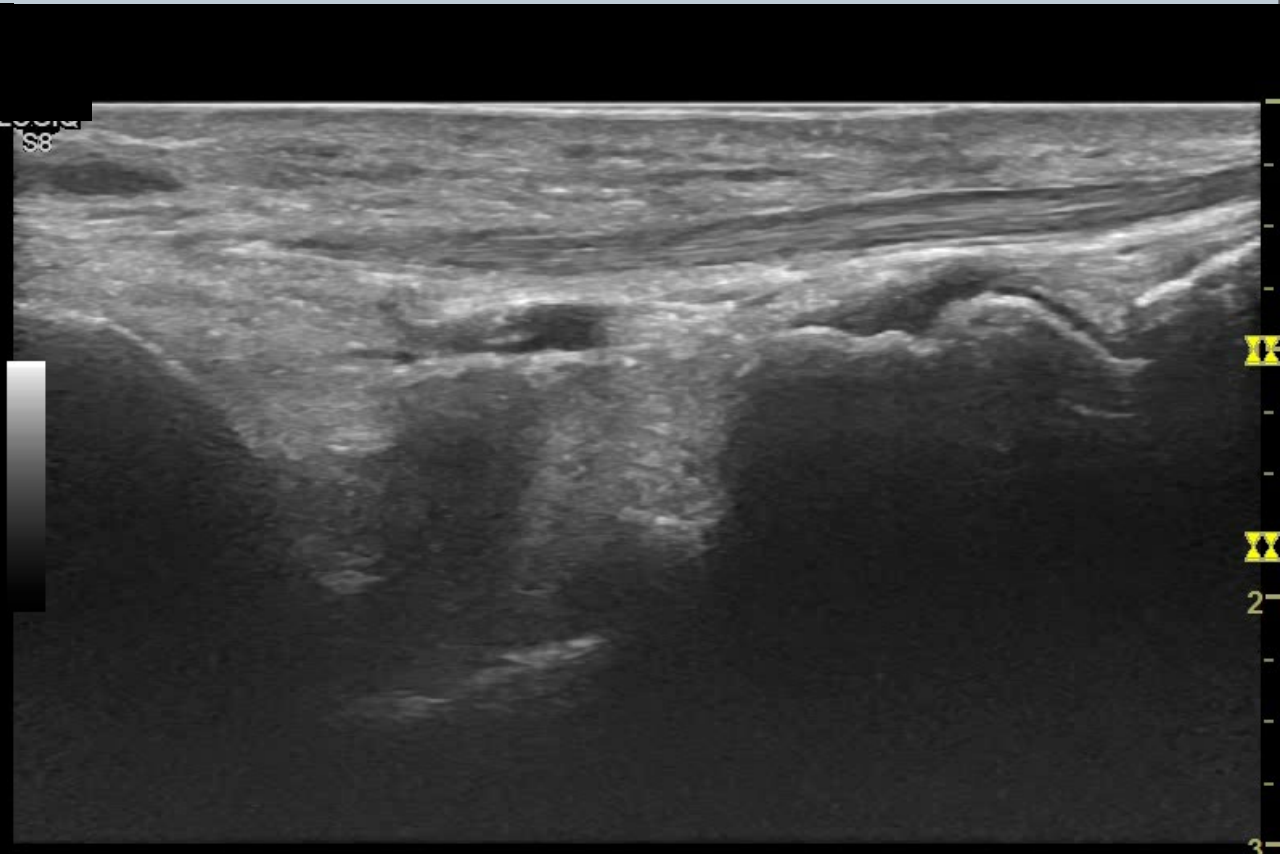
LEFT ANKLE SAX

Left Ankle Talus SAX

Right Ankle Comparison Contralateral



RIGHT ANKLE LAX

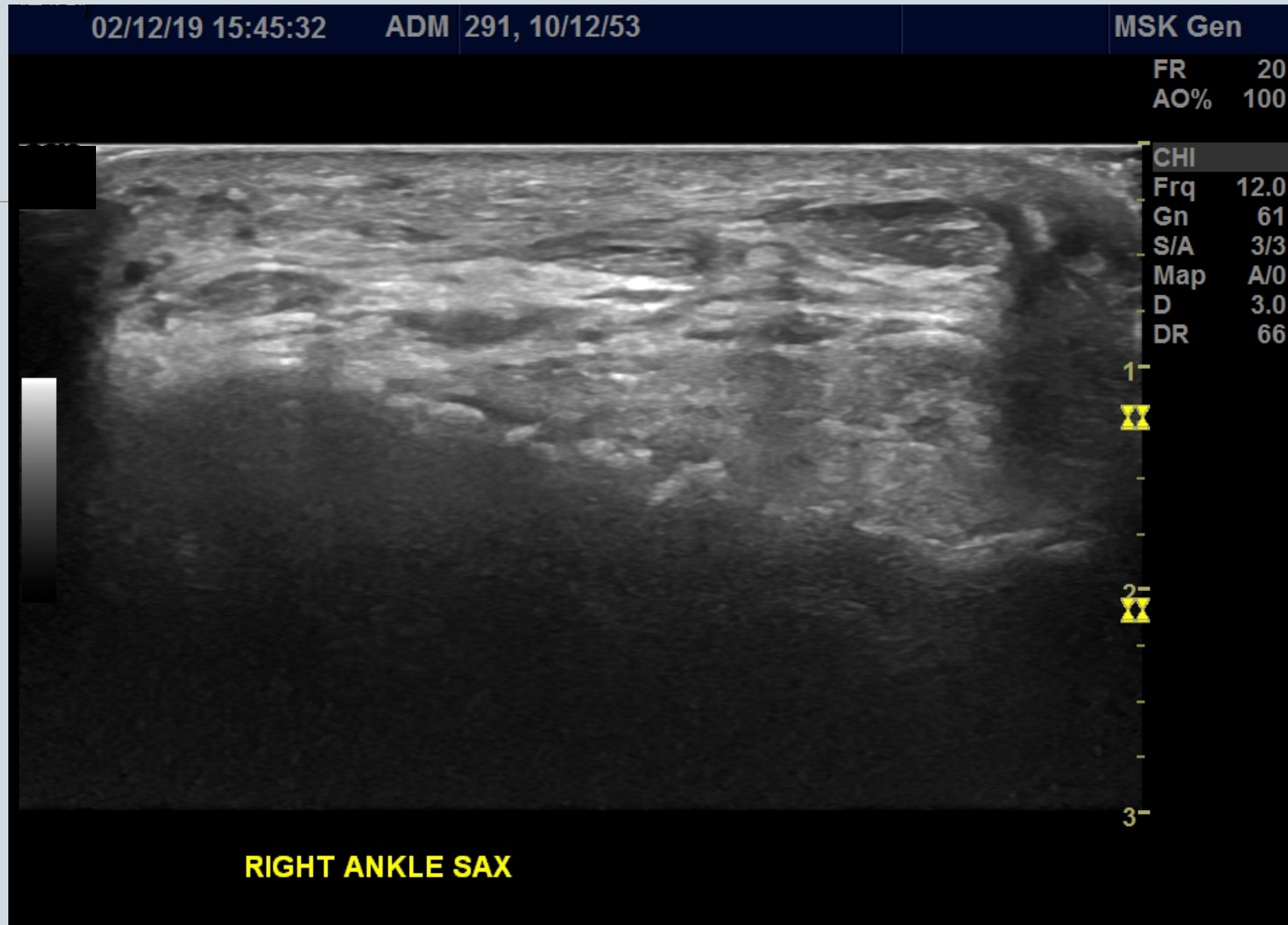

RIGHT ANKLE LAX

Right Ankle LAX

Use Dorsiflexion and plantarflexion motion to locate joint line and to move intra-articular soft tissue expansion and fluid

Distal
Tibia
SAX



Right Distal Tibia SAX

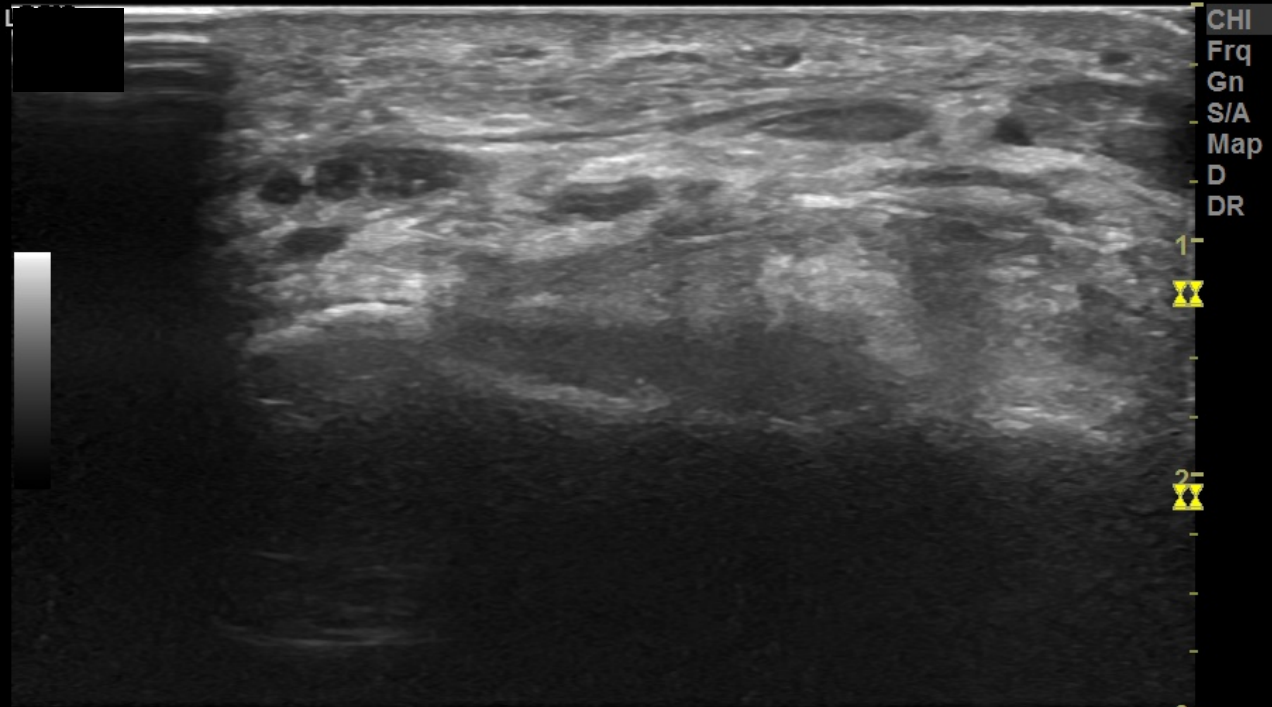
FR
AO%

CHI
Frq
Gn
S/A
Map
D
DR

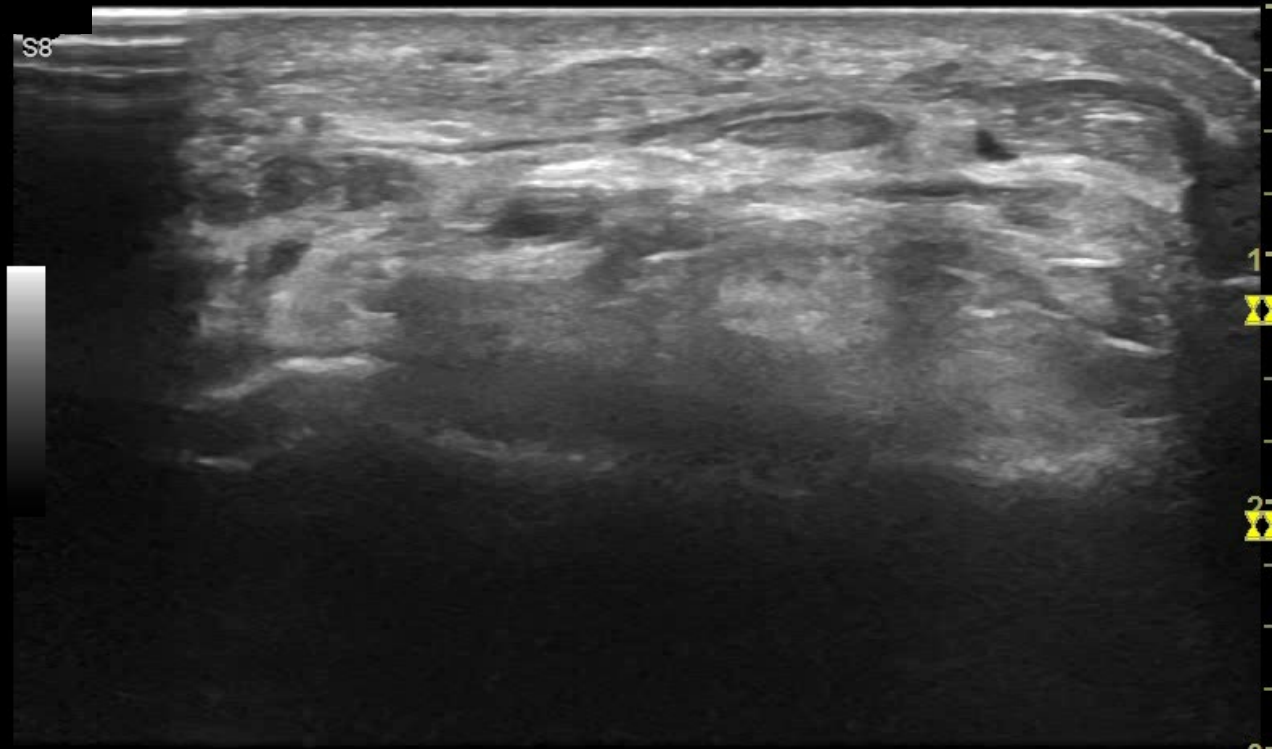
1-



3-



RIGHT ANKLE SAX



RIGHT ANKLE SAX

Right Ankle SAX of Talus

Use Compression real-time technique, and locate Dorsalis Pedis

Results/Treatment Plan

Findings

1. Severe left anterior ankle ROM limiting impingement
2. Severe talar dome destruction
3. Severe distal Tibial bone erosion
4. Bilateral intra-articular soft tissue expansion
5. Absence of acute hemarthrosis

Treatment suggestions

1. Bracing/higher heel
2. PT
3. IASI
4. Referral to Orthopedics/Podiatry for surgical options including articular debridement.

Clinical Pearls

1. Mobilize the articulation to verify joint line
2. Do not force ROM beyond bony impingements
3. Acknowledge impingement vs. hemarthrosis in MSK differential screening
4. Sweep translation from proximal to distal in SAX
5. Sweep translation from lateral to medial in LAX
6. Check contralateral limb
7. Consider using Panorama view across the ankle from the tibia to the talonavicular joint
8. Locate Dorsalis Pedis to ascertain the upper margin of the combined synovium/fat/fibrous capsule interface

Case Vignettes and Clinical Pearls

LENA VOLLAND PT, DPT

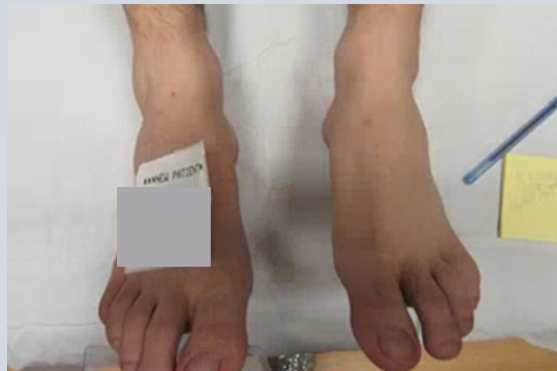Case: 21 y/o male with severe hemophilia A with R ankle pain

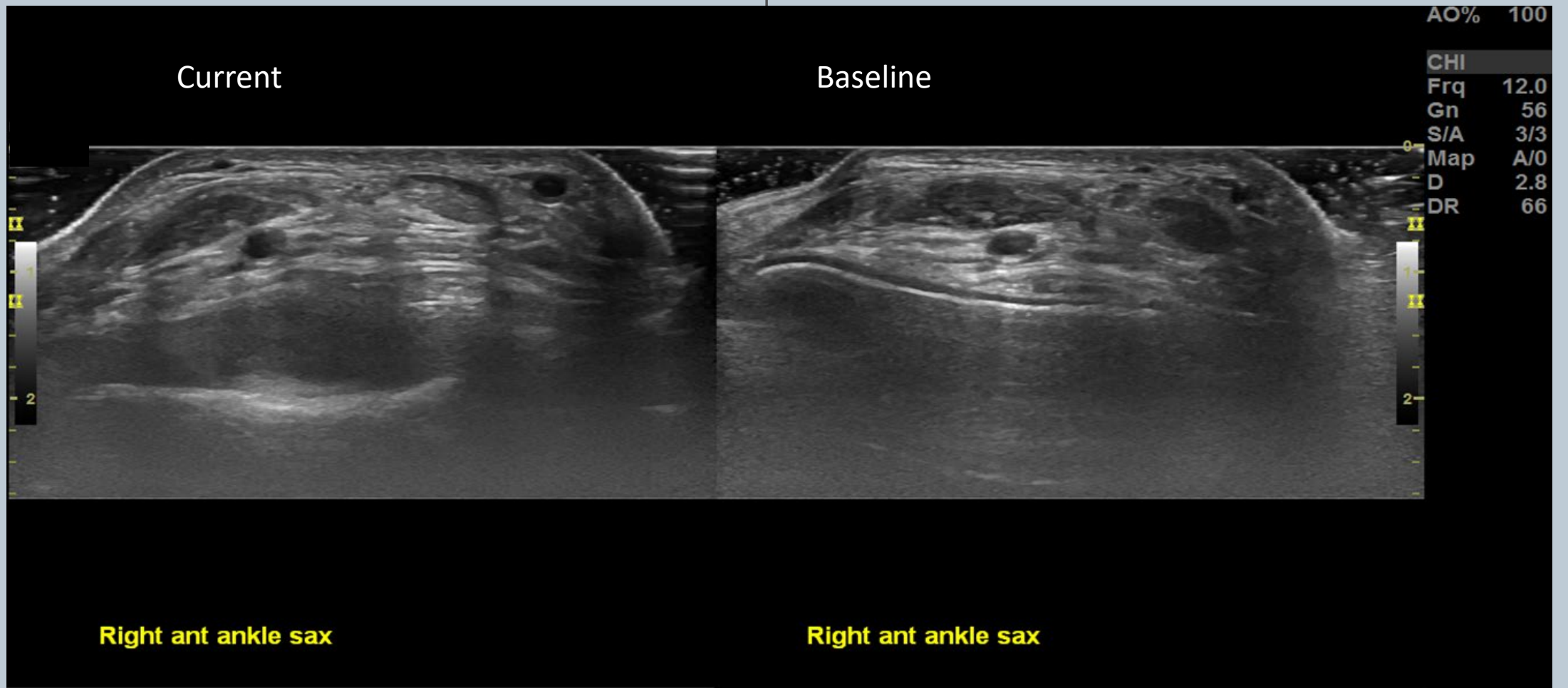
Patient History/Subjective

1. Spontaneous onset of R ankle pain in the morning
2. Prophylaxis
3. Infused 45 minutes before arriving at the clinic

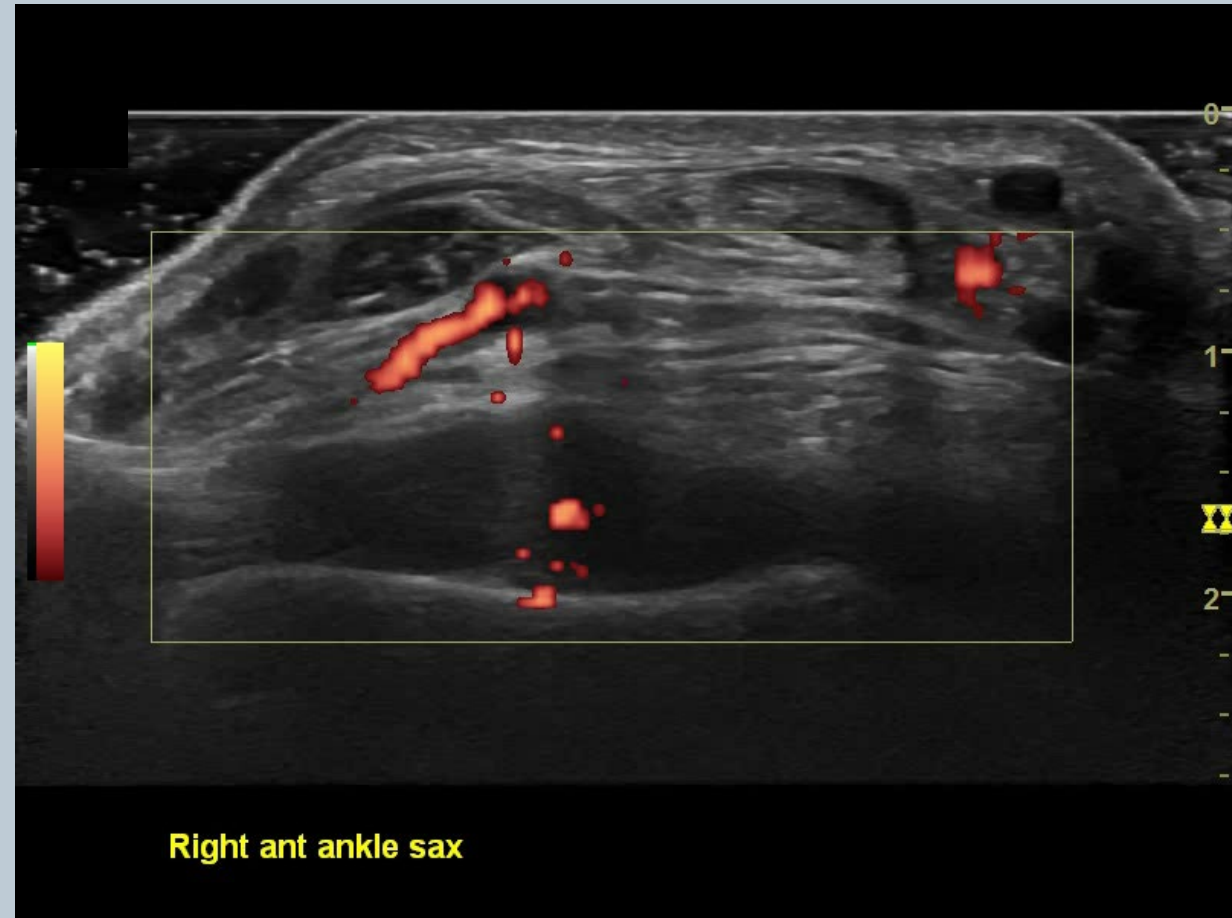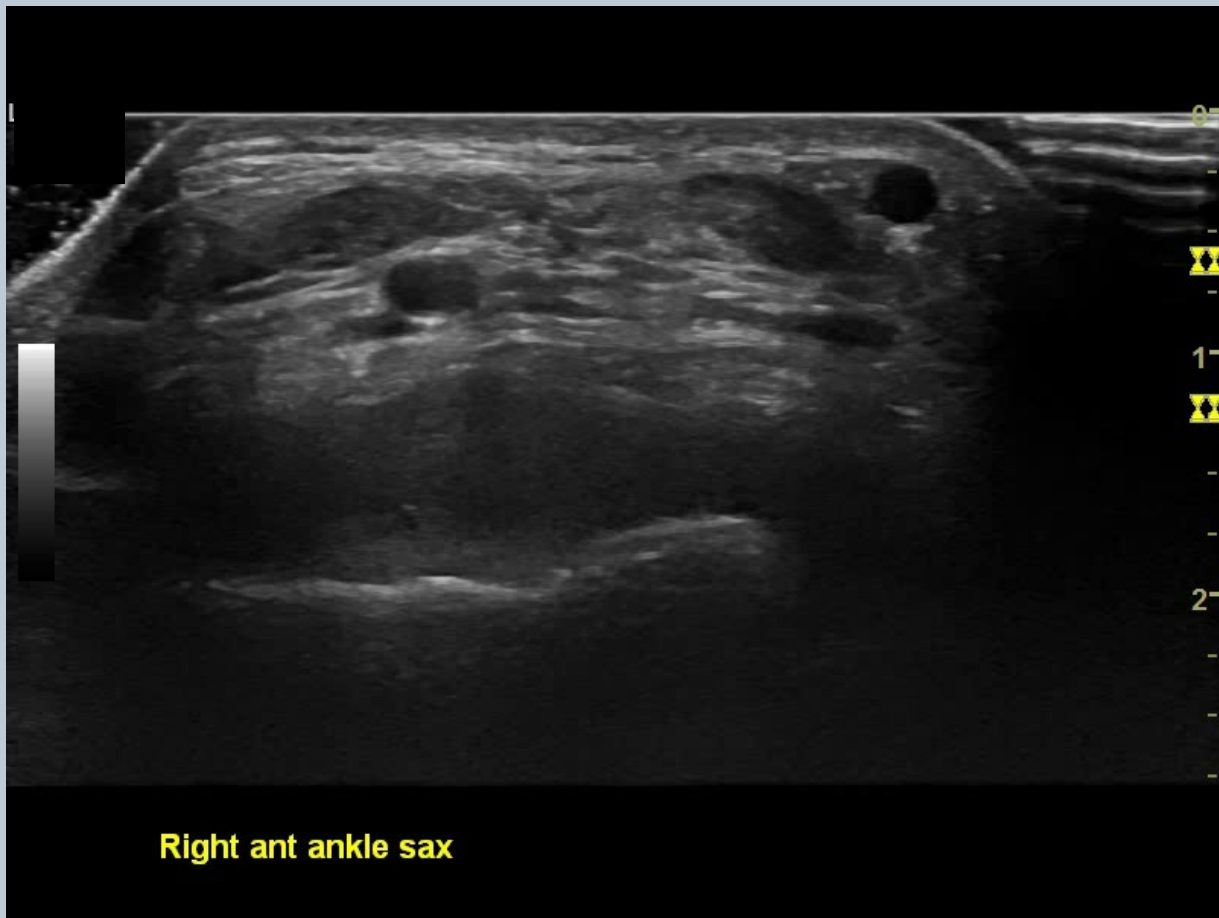
Patient Presentation

1. ROM limited in all direction by pain
2. Tender to palpation on anterior aspect of right tibiotalar joint and right ATFL region
3. Very mild palpable swelling over R ATFL
4. Decreased ability to tolerate WB

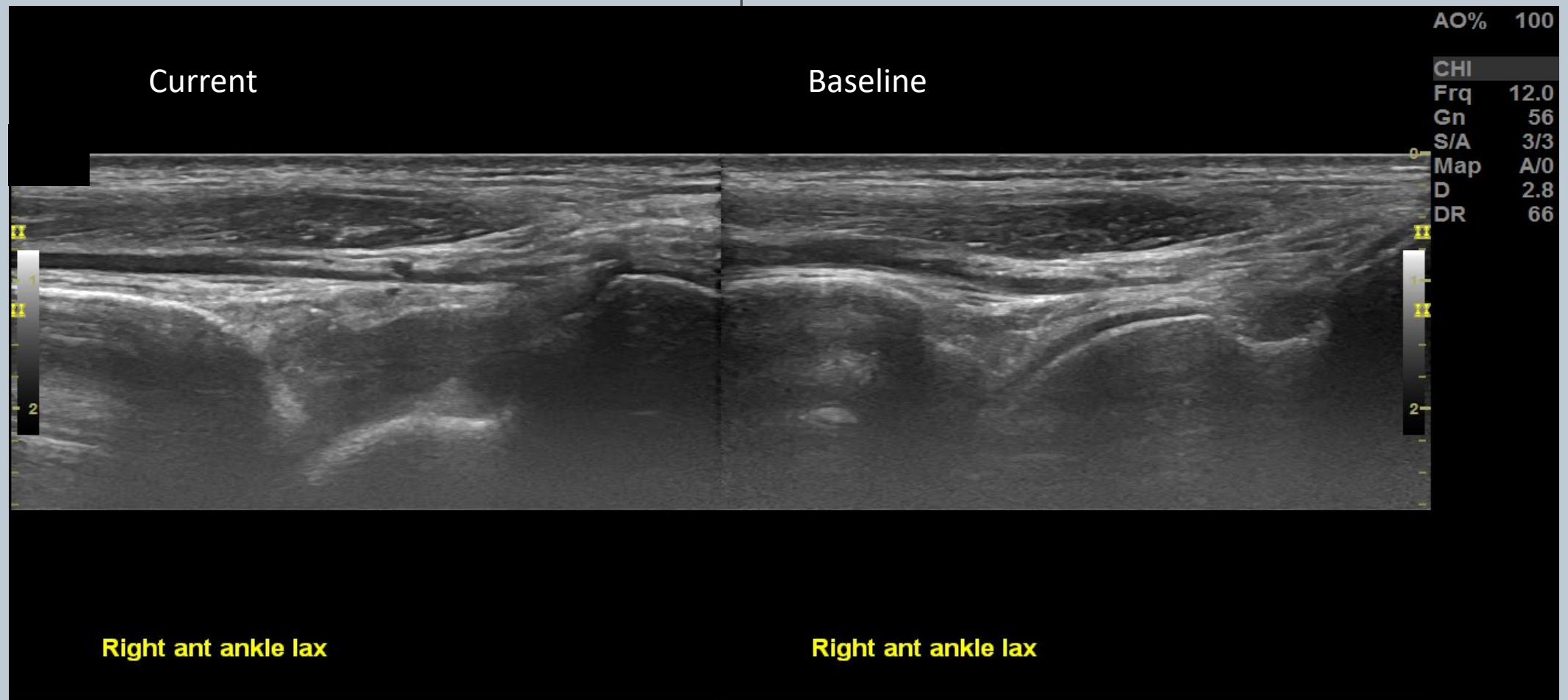




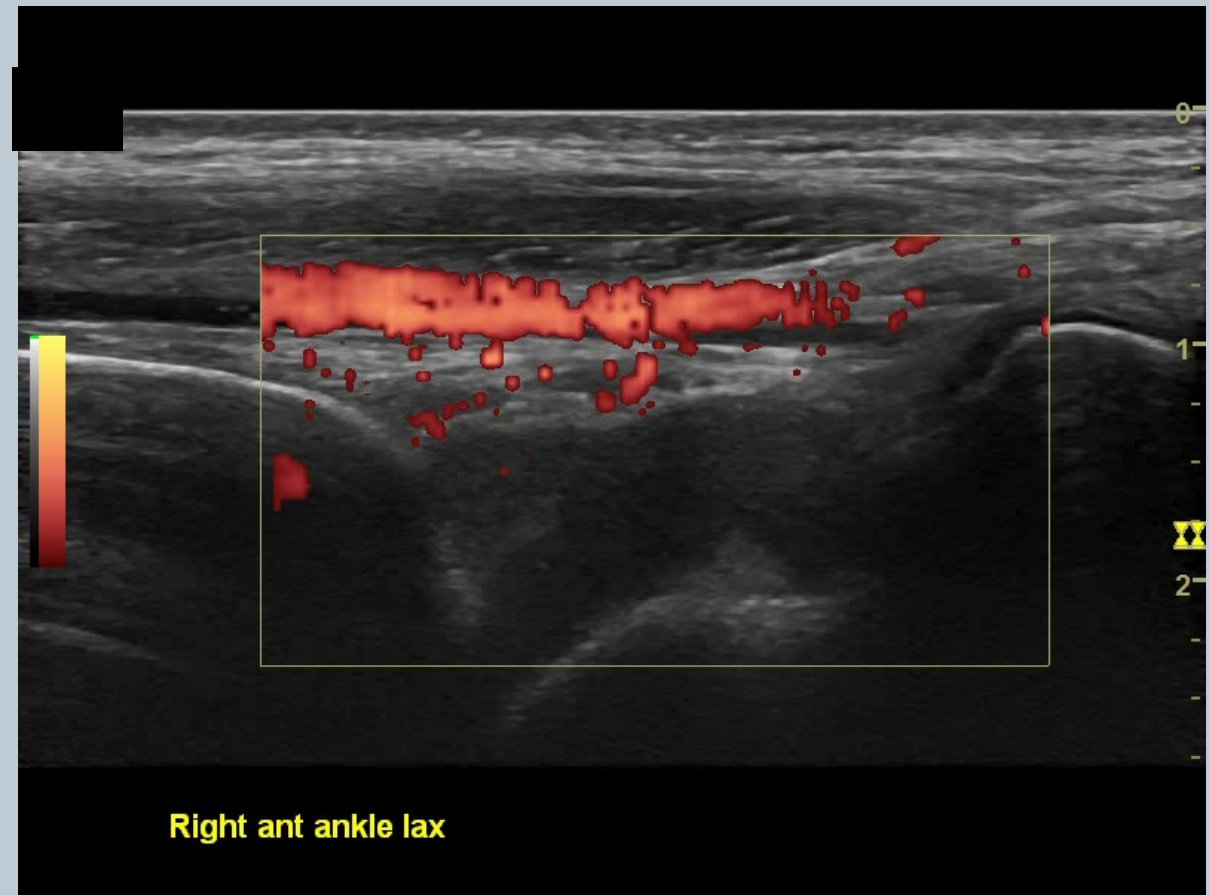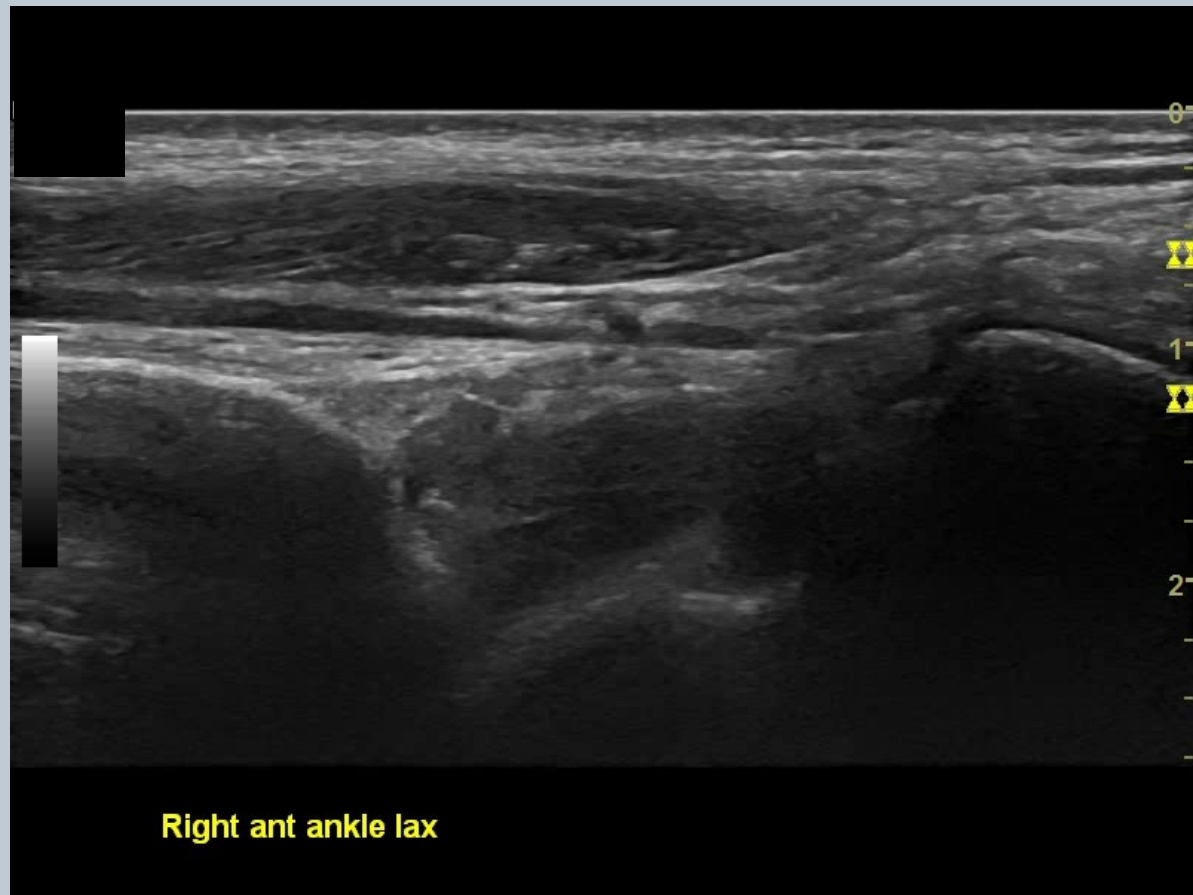
Right Anterior Ankle SAX



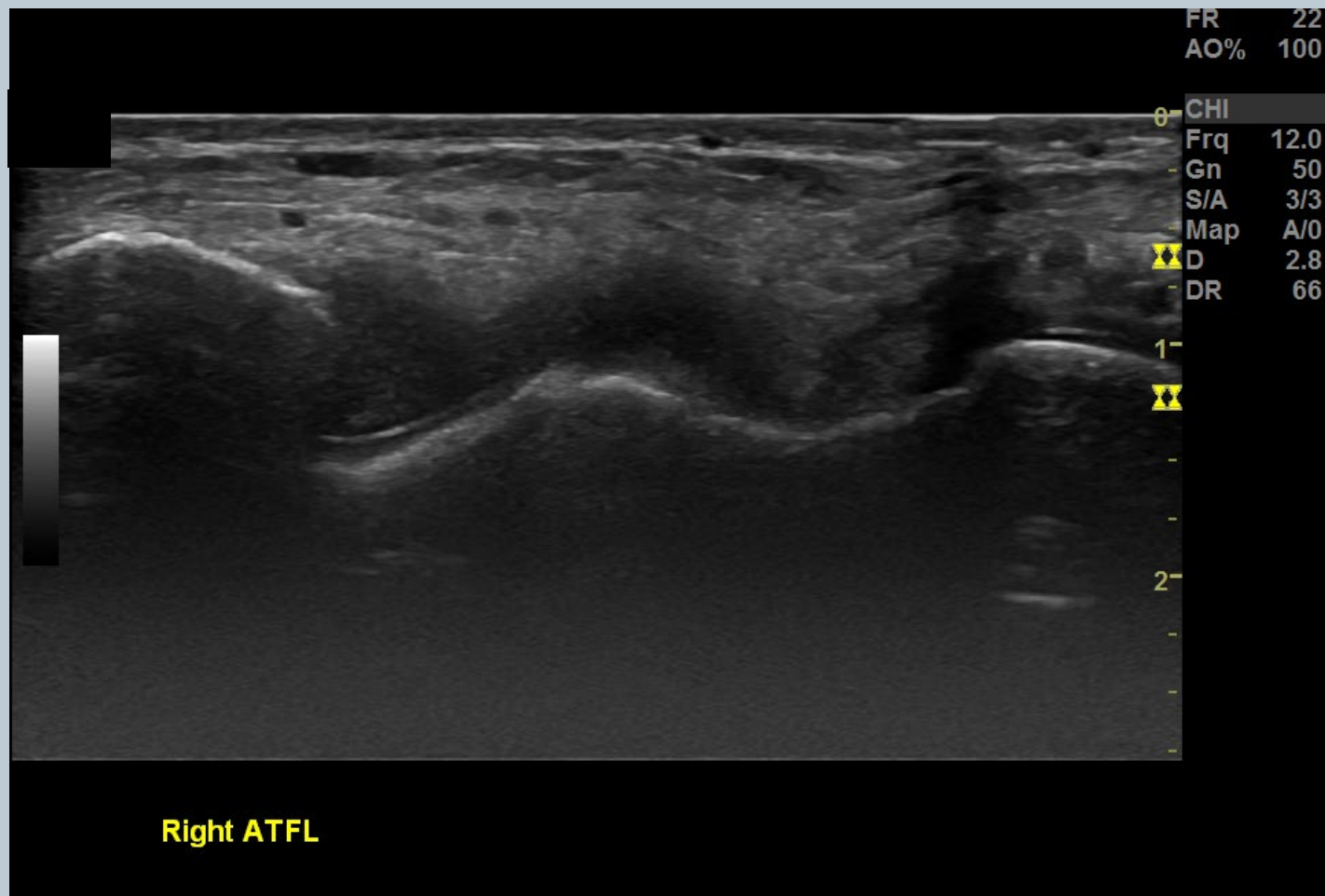
Right Anterior Ankle SAX



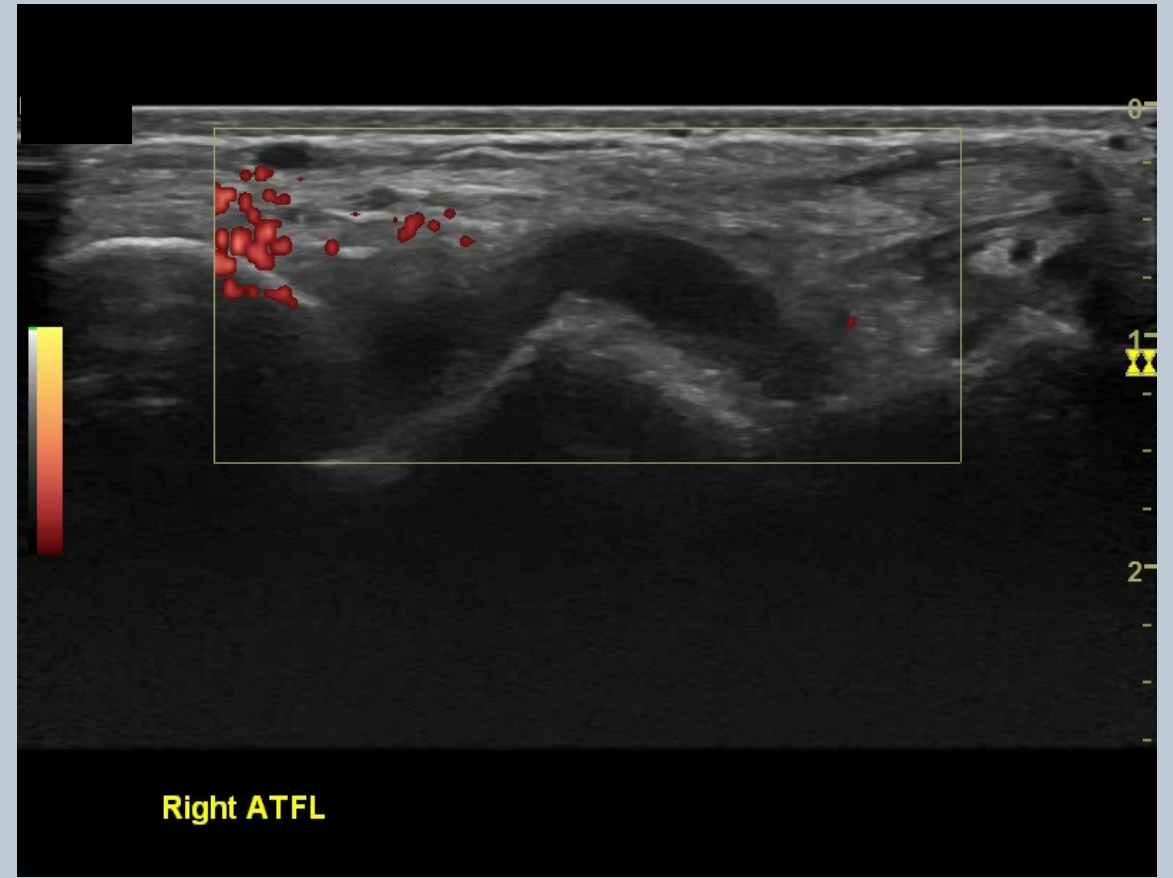
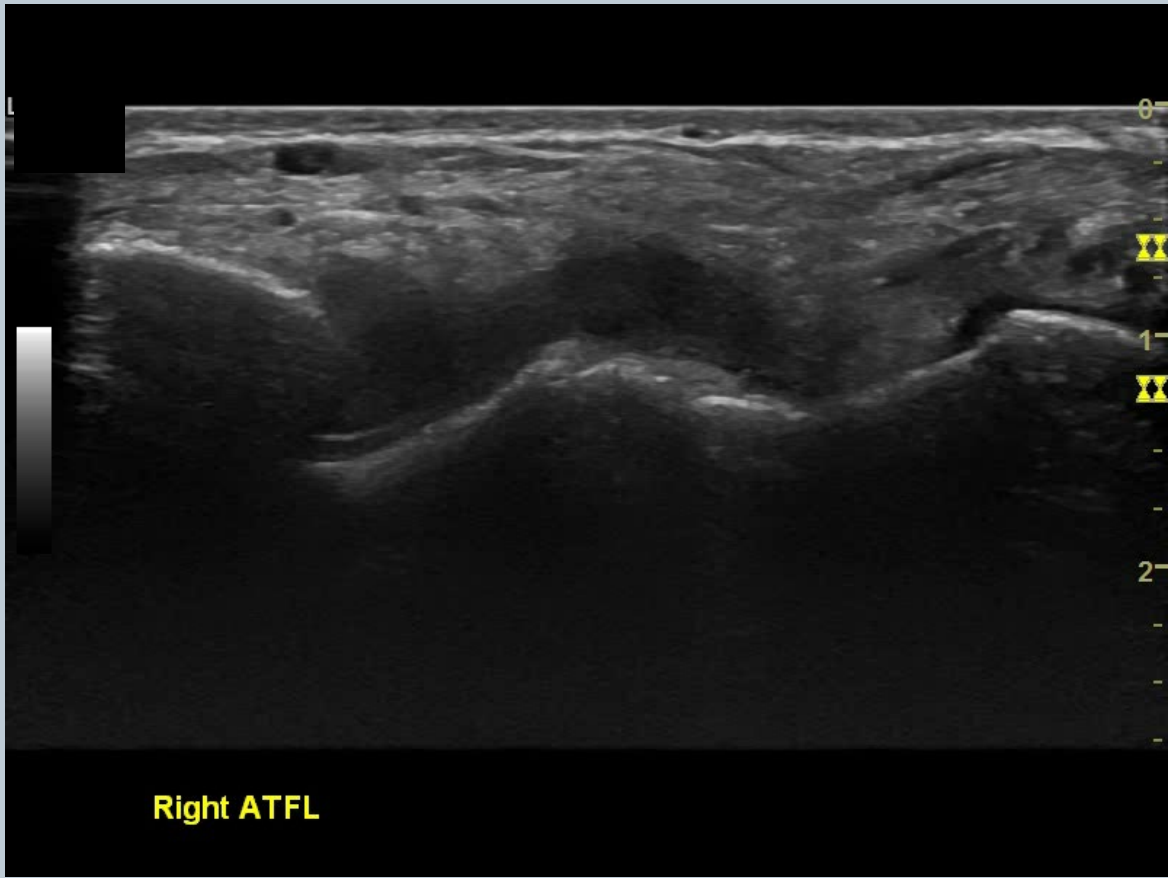
Right Anterior Ankle LAX



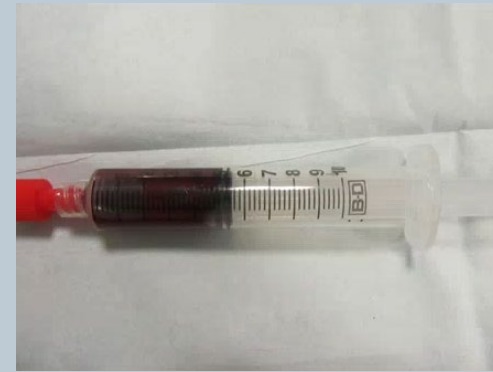
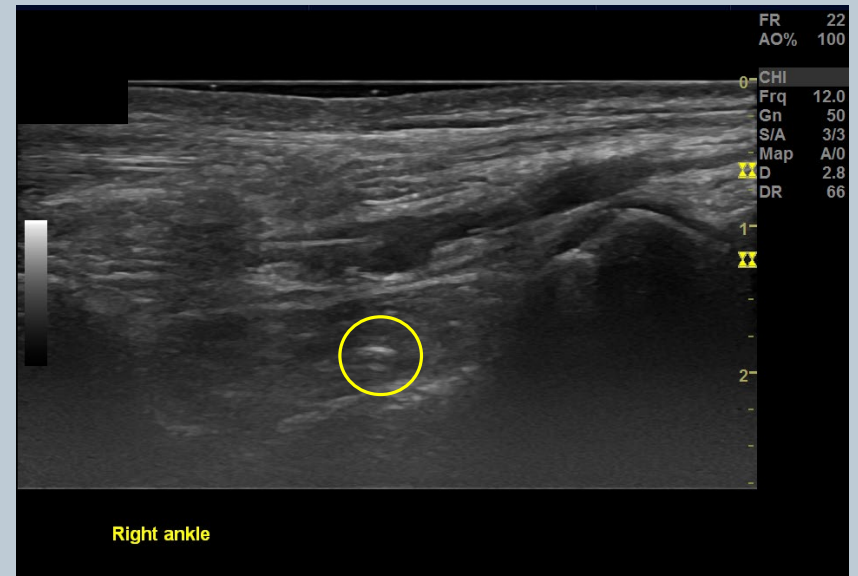
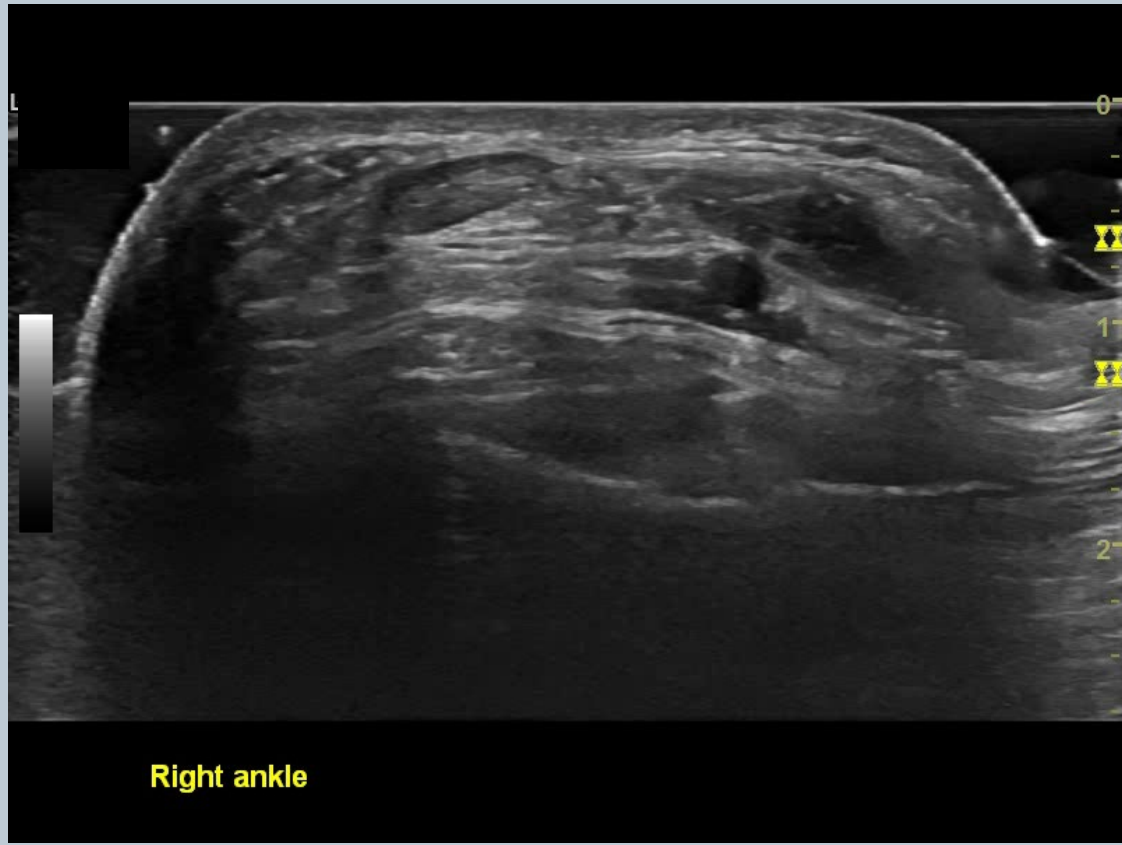
Right Anterior Ankle LAX



Right ATFL

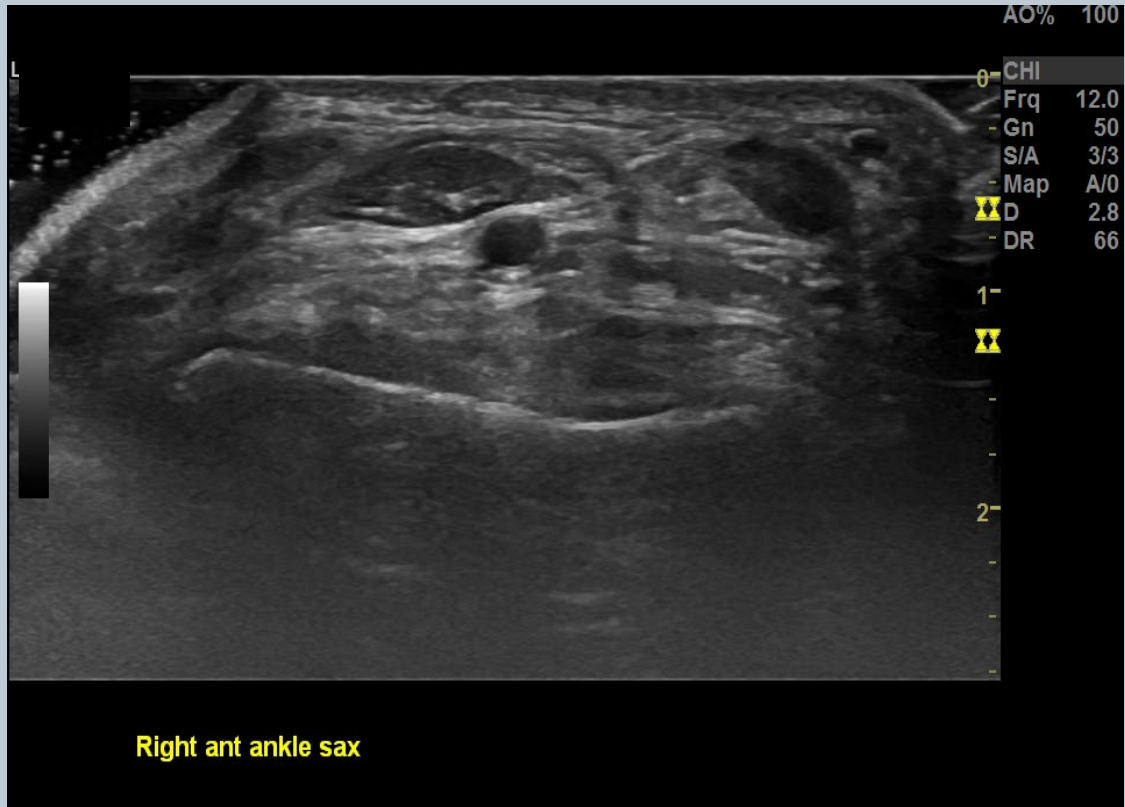

Right ATFL

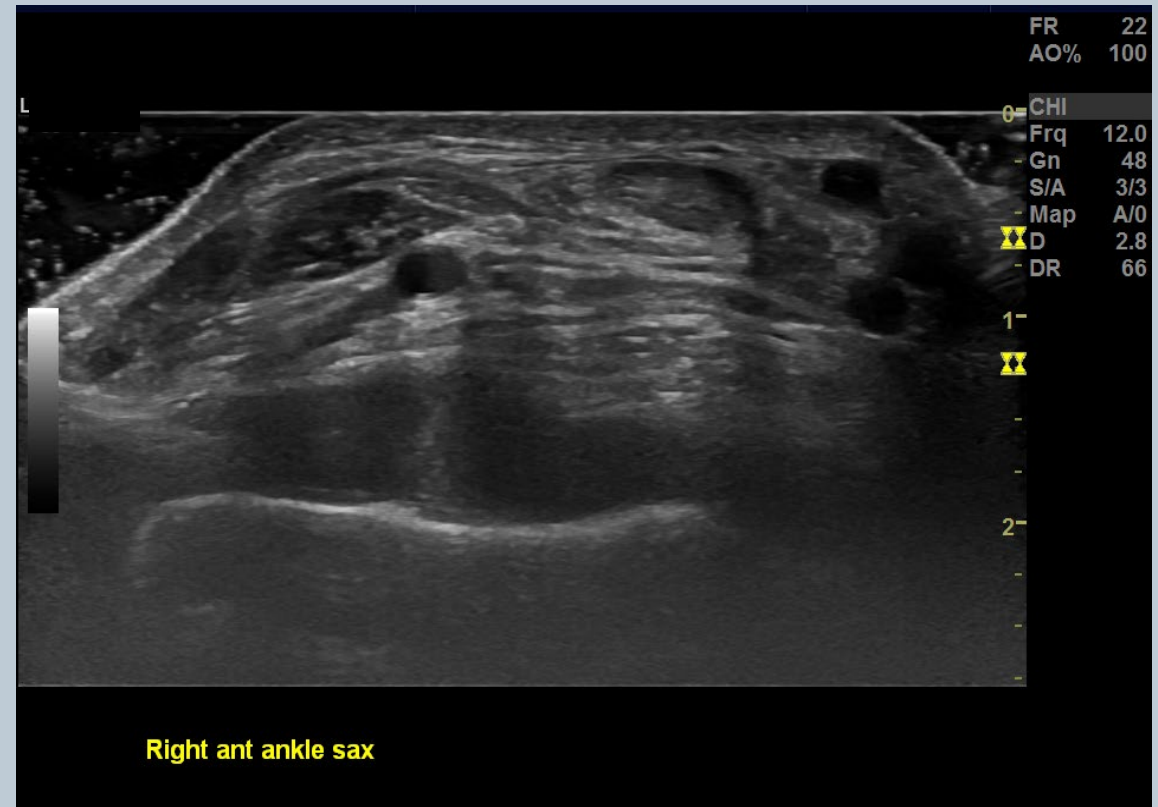


Aspiration

Post Aspiration

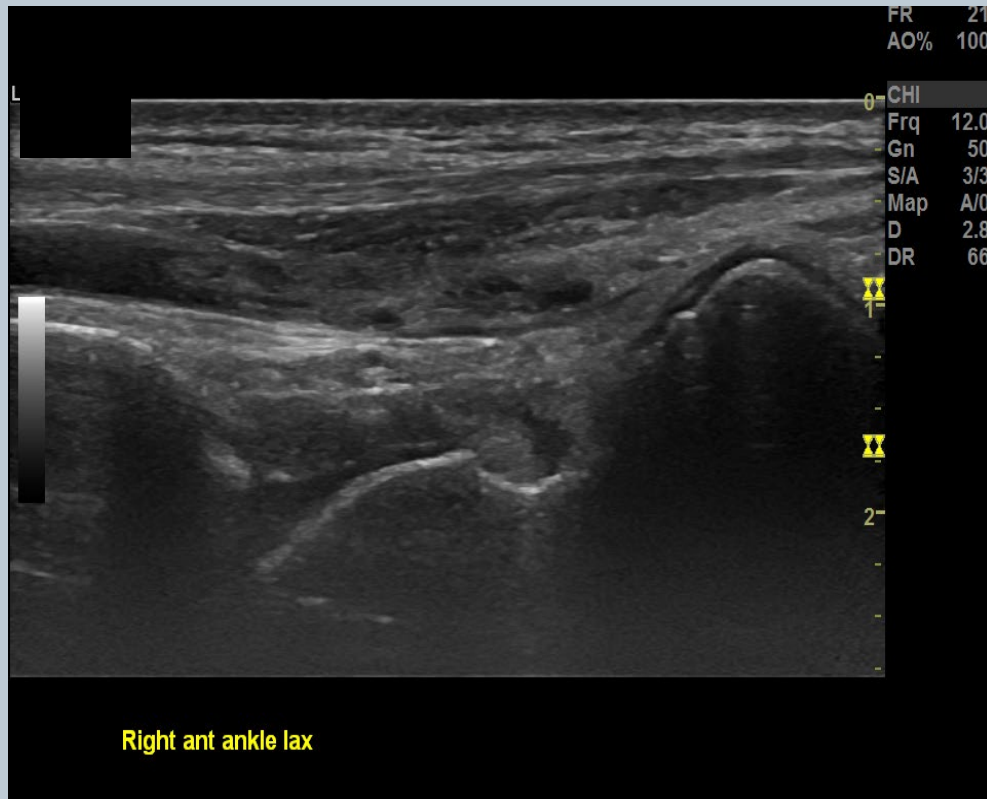


Pre Aspiration

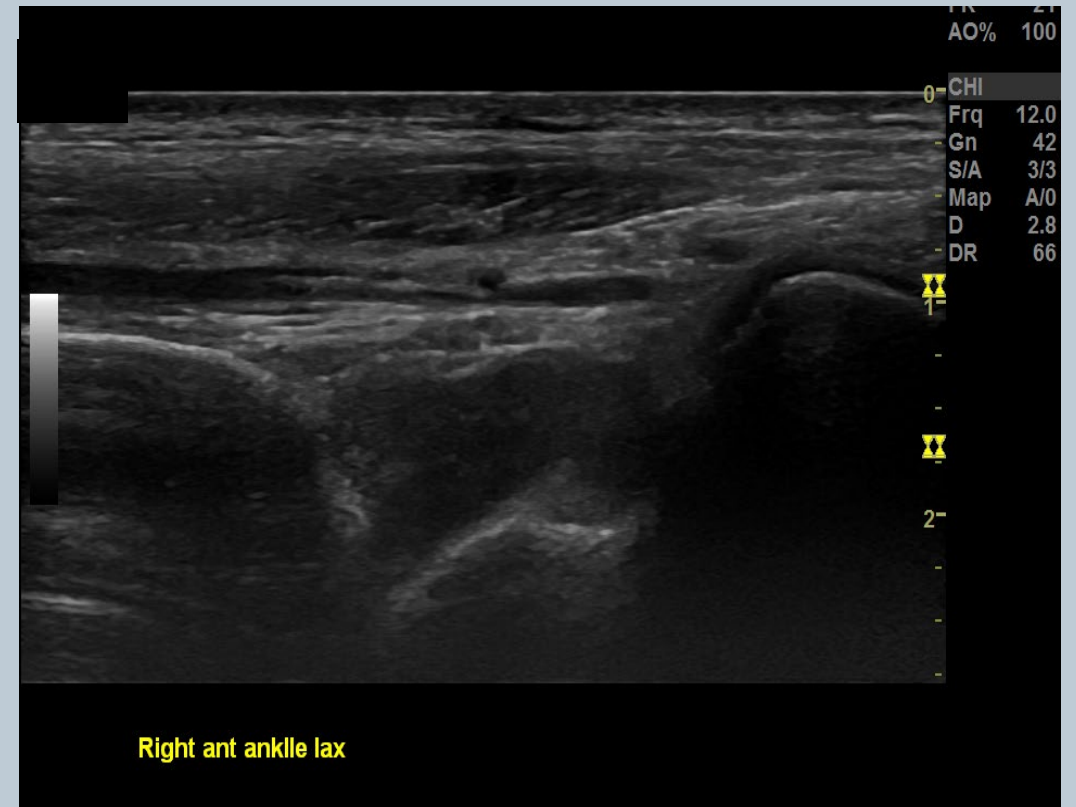


Right Anterior Ankle SAX

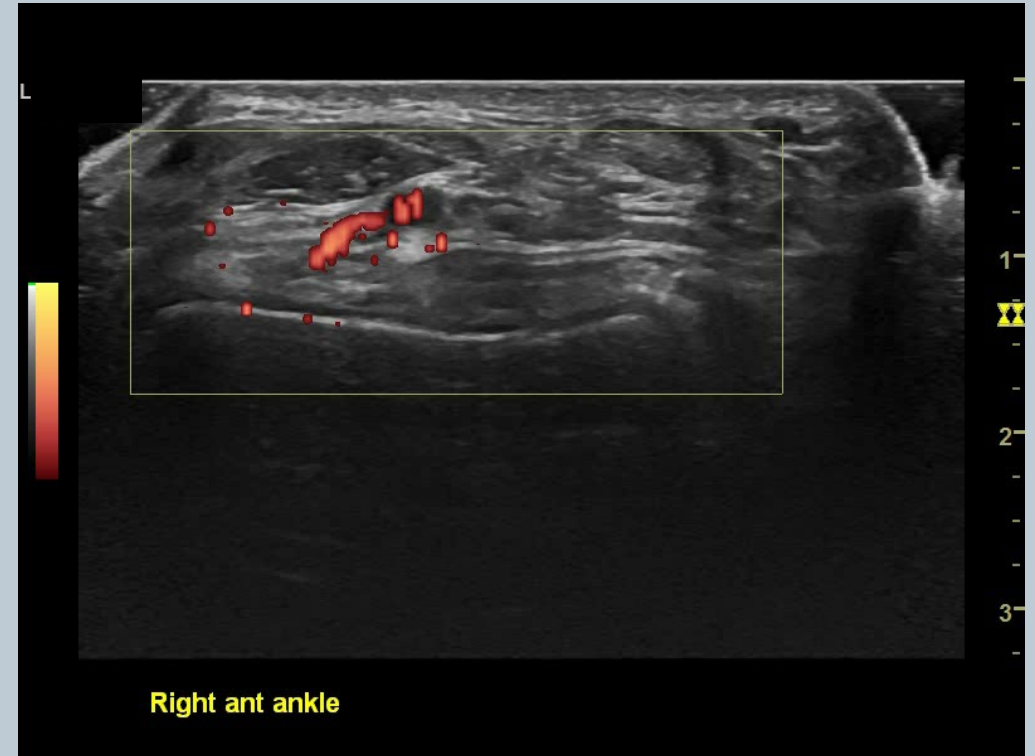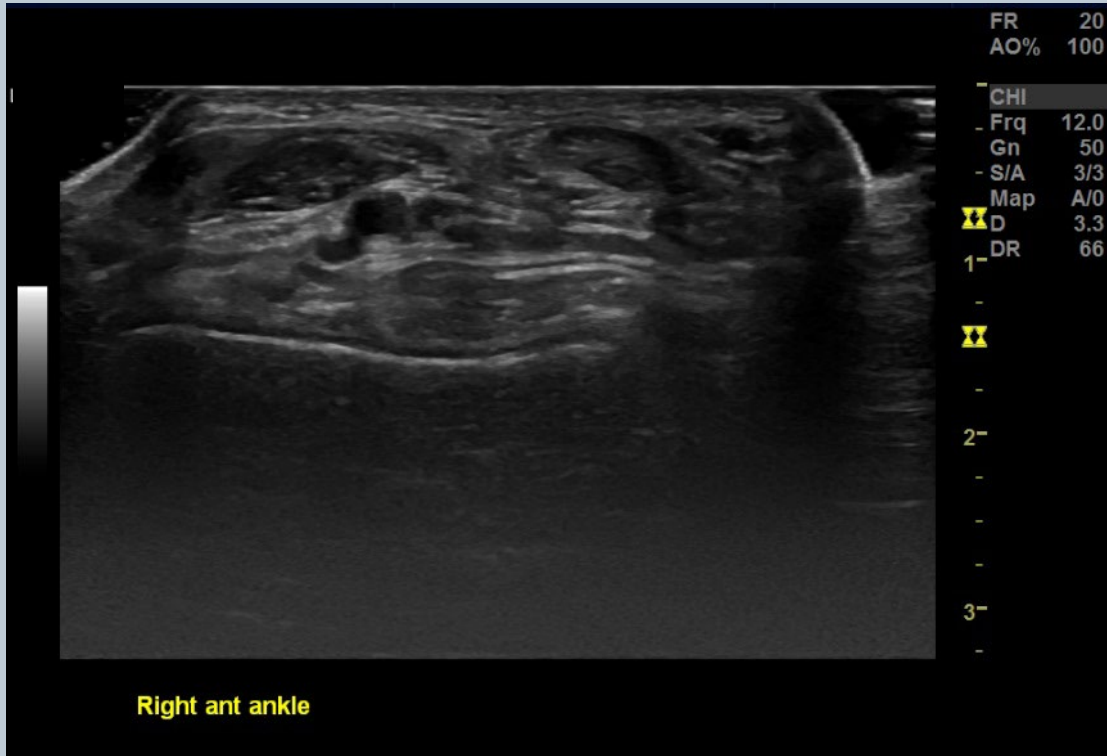
Post Aspiration



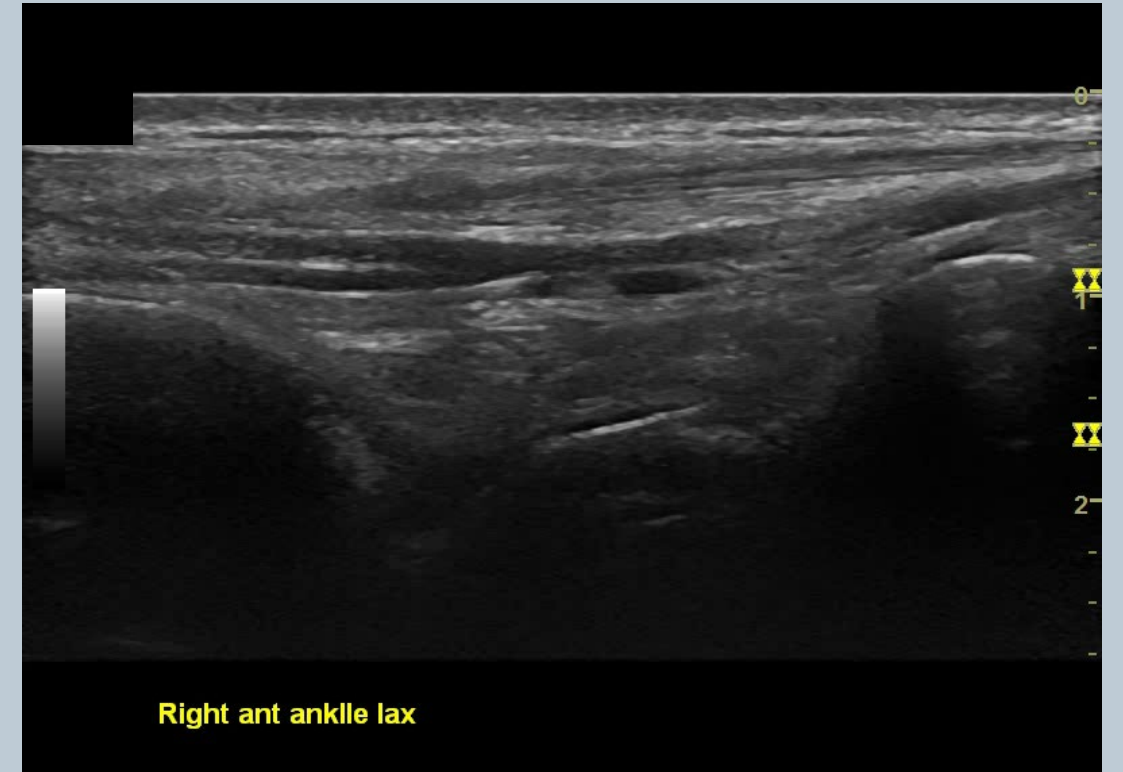
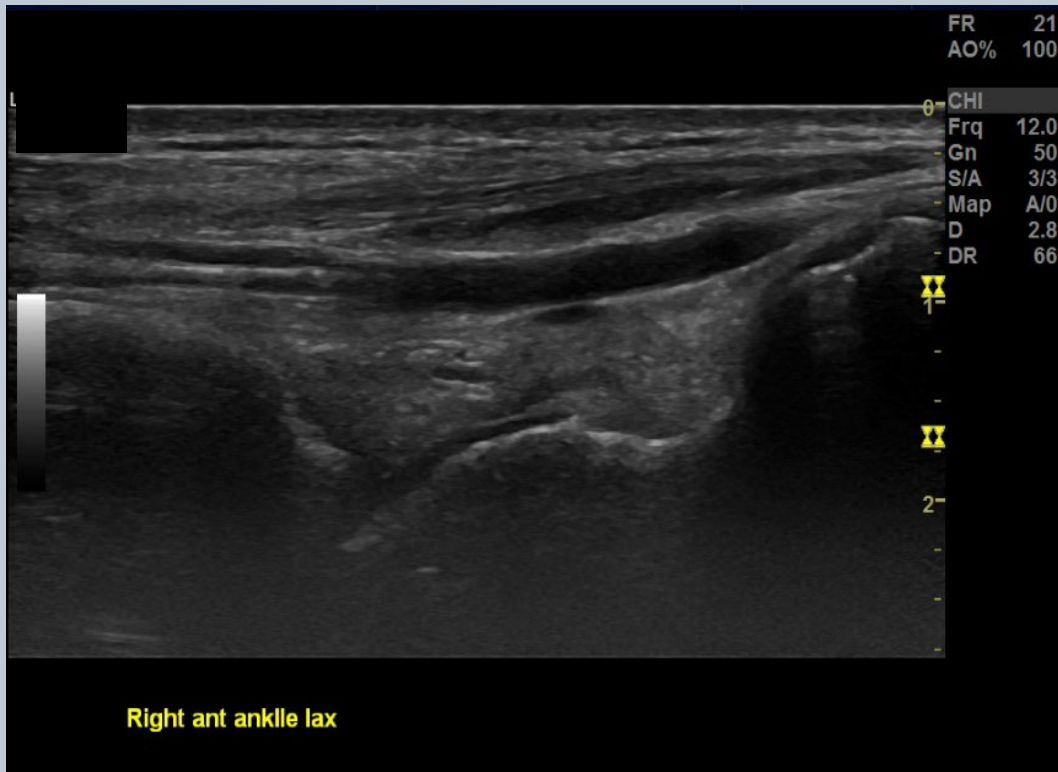
Pre Aspiration



Right Anterior Ankle LAX



Right Anterior Ankle SAX – 1 week later



Right Anterior Ankle LAX – 1 week later

Results/Treatment Plan

Findings

1. Hypoechoic complex effusion visible in anterior ankle LAX and SAX

Treatment

1. Aspiration
2. Daily factor
3. PT rehabilitation once bleed had resolved

Clinical Pearls

1. Visual inspection alone is not reliable in detecting bleeds or assessing the extend of a hemarthrosis
2. MSKUS supplements the clinical examination
3. Comparison to baseline images is beneficial
4. MSKUS supports procedure accuracy
5. Follow up imaging directly post aspiration and a week later assist in visualization of the treatment effect

Acute joint pain in a patient with mild VWD

Can it be joint bleeding

?

ANNETTE VON DRYGALSKI, MD, PHARM.D, RMSK

PROFESSOR OF CLINICAL MEDICINE

DIRECTOR, HEMOPHILIA & THROMBOSIS TREATMENT CENTER

UNIVERSITY OF CALIFORNIA SAN DIEGO

Case : 48 y/o male with mild VWD (40% VWF activity)

Presentation

Felt a snap in his ankle when stepping down from a bike

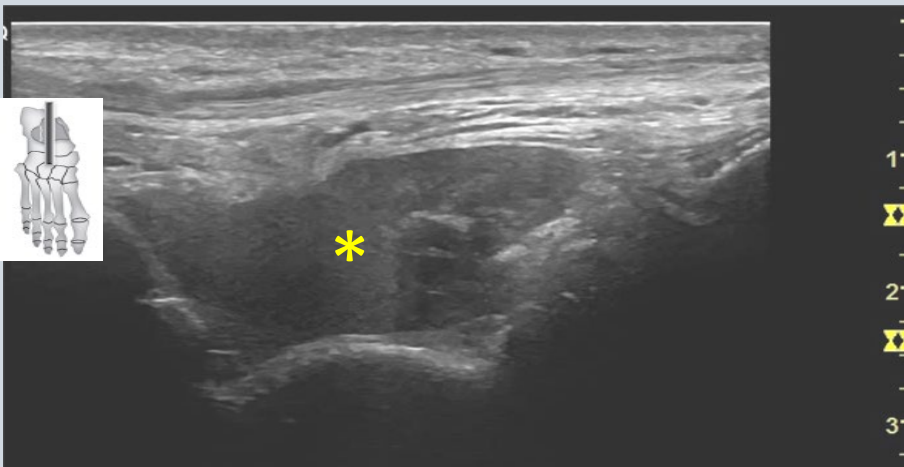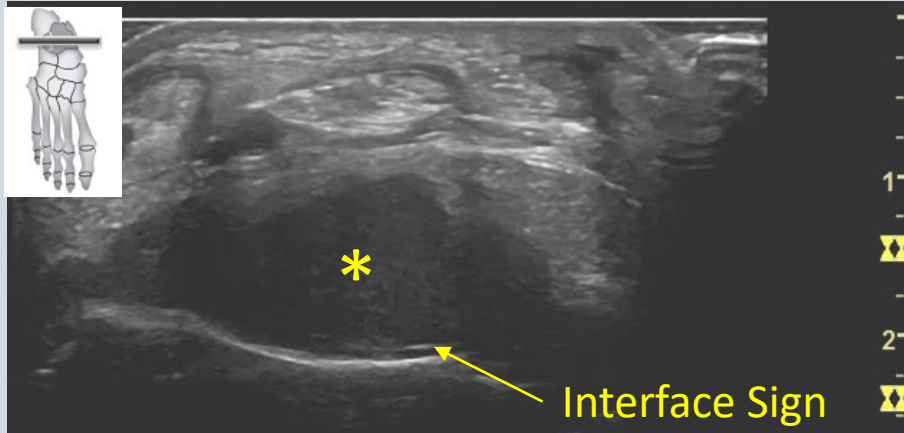
Ankle swelling and pain

The patient wishes to undergo MSKUS to determine if he suffered from a joint bleed

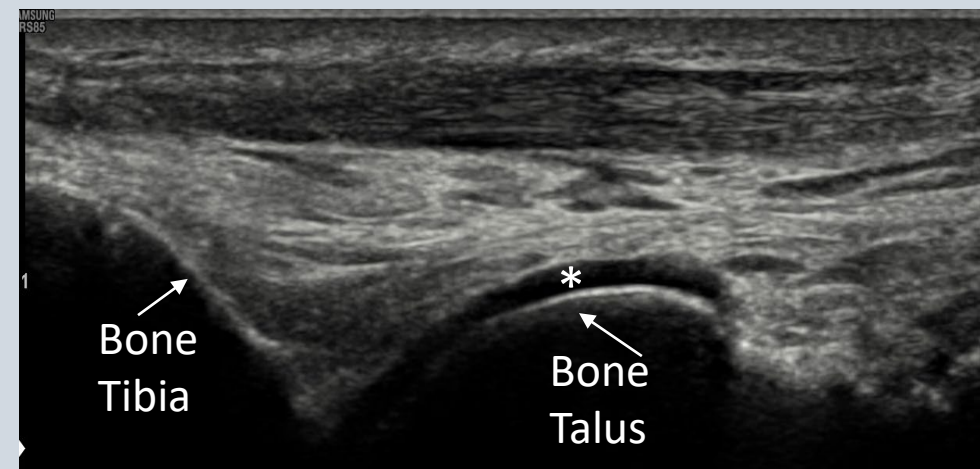
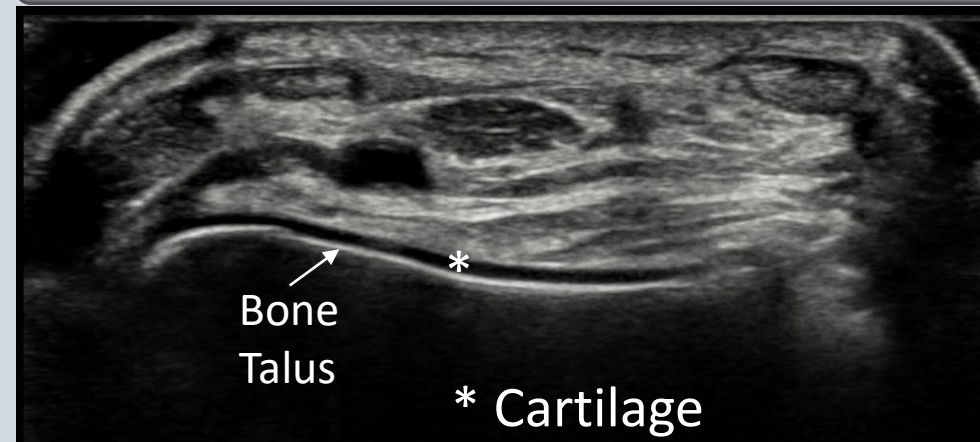
Our suspicion is low due to the mild nature of the bleeding disorder and a lack of bleeding history in this patient

Clinical question: Bleeding or not ?

Acute Presentation



Normal

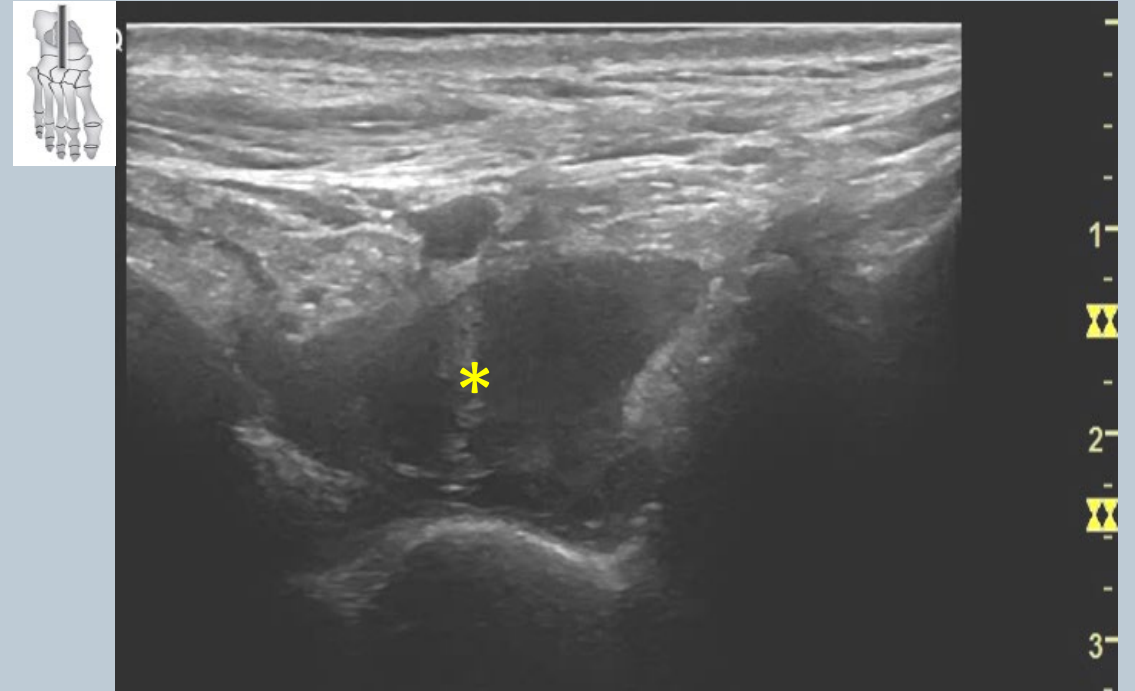
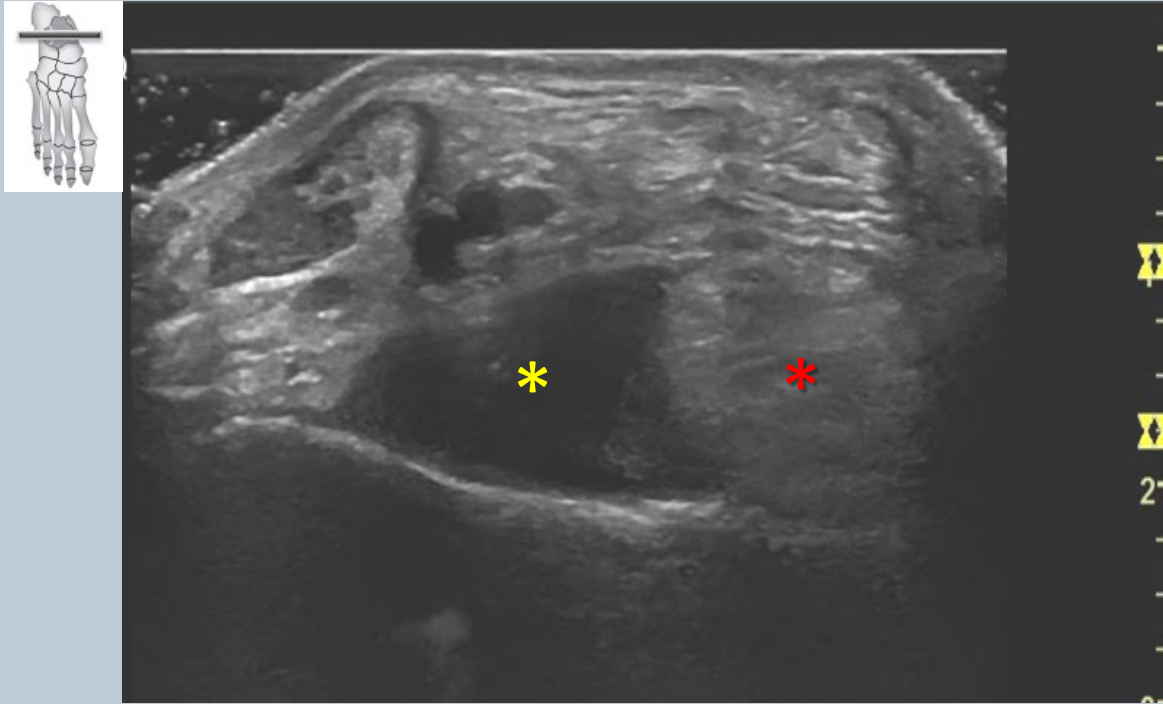


Right ankle
Tibio-talar joint space: short and long axis

* Findings: Large complex effusion
Consistent with hemarthrosis

Treatment: Administration of VWF concentrate daily until symptom relief

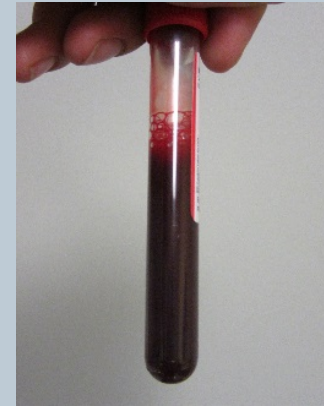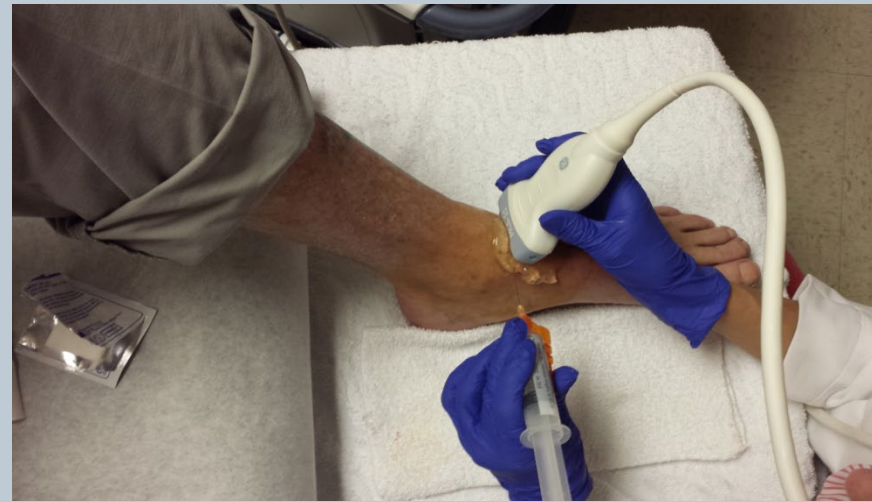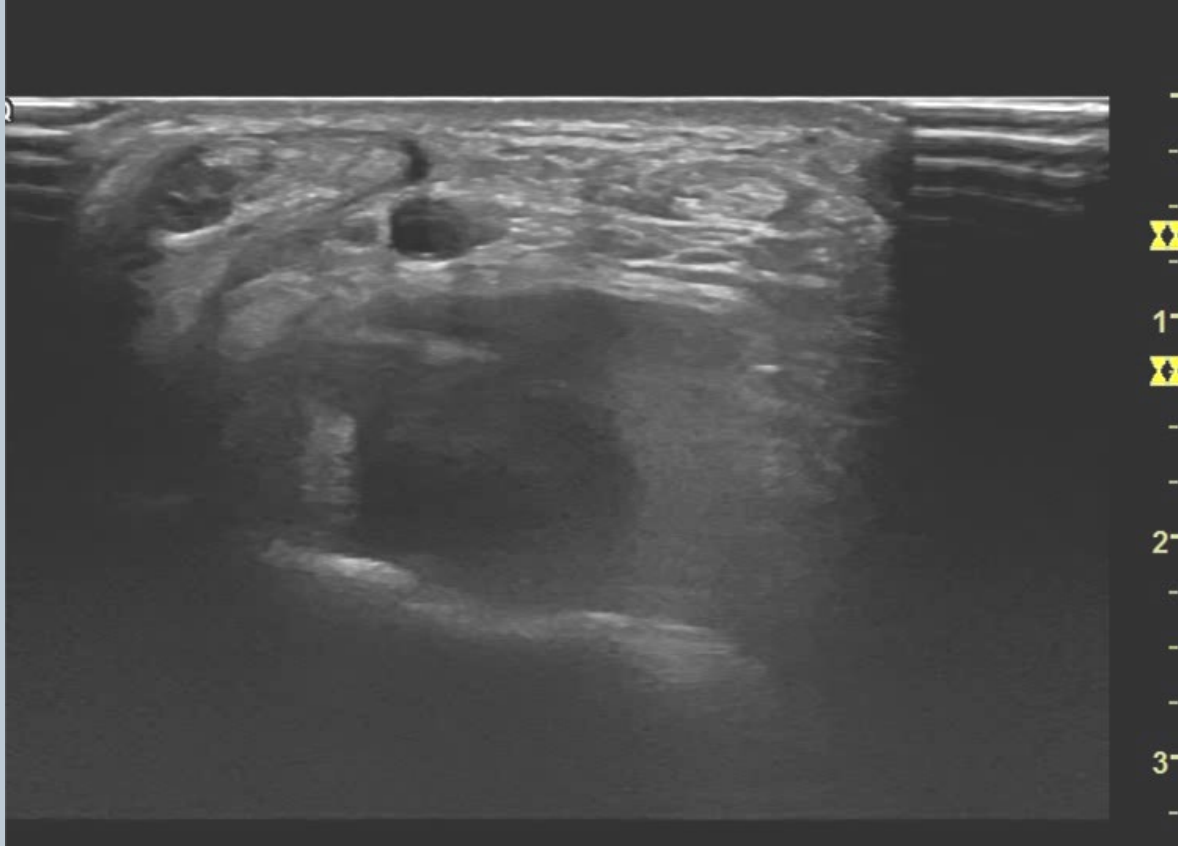
Presentation 3 days later



Right ankle
Tibio-talar joint space: short and long axis

Findings: Continued large complex effusio
Possible clot formation/blood coagulation

Joint aspiration



Findings: Confirmed large hemarthrosis

Additional x-rays: Unremarkable

Results/Treatment Plan

Findings

Complex effusion (compressible)

Without other abnormalities on x-ray

Diagnosis

Hemarthrosis in mild VWD patient

Treatment

Continued infusions with VWF concentrate daily for 2 weeks daily

Aspiration for pain relief

Conservative rehabilitation

Teaching points:

- 1) Patients with mild VWD may suffer from traumatic hemarthrosis**
- 2) Clotting factor administration alone was unable to resolve the bleeding in a timely fashion**
- 3) Aspiration was effective to reduce blood volume and prevent bleed recurrence**

Hemophilia

A case of acute joint pain ?

Bleeding or not

ANNETTE VON DRYGALSKI, MD, PHARM.D, RMSK

PROFESSOR OF CLINICAL MEDICINE

DIRECTOR, HEMOPHILIA & THROMBOSIS TREATMENT CENTER

UNIVERSITY OF CALIFORNIA SAN DIEGO

Case: 37 y/o male with severe Hemophilia A and inhibitor

Presentation

Acute knee pain

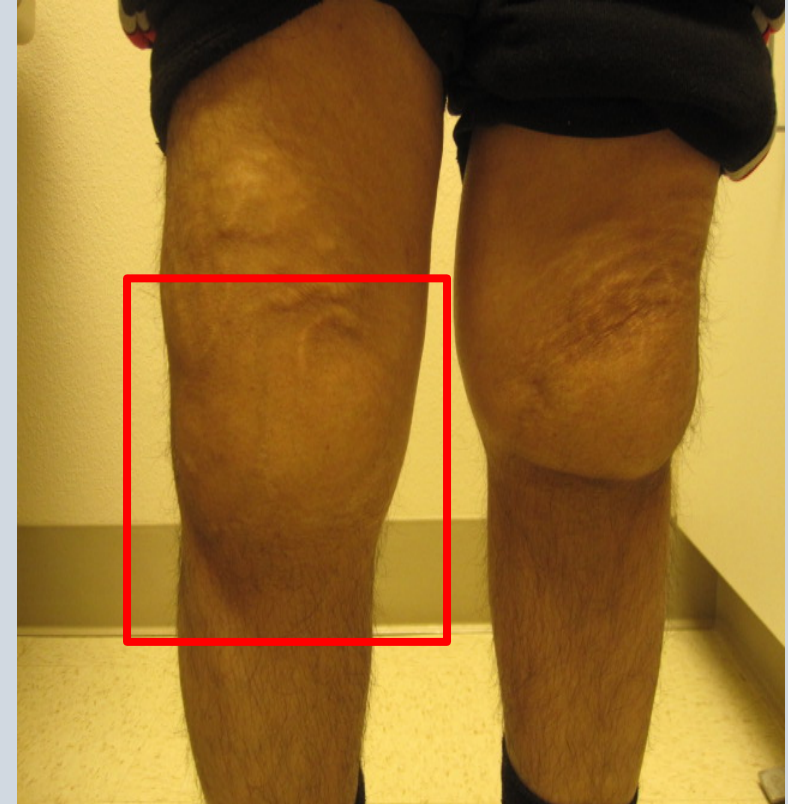Swelling

Warmth

Perceived joint bleeding

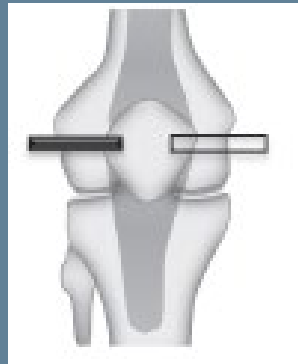
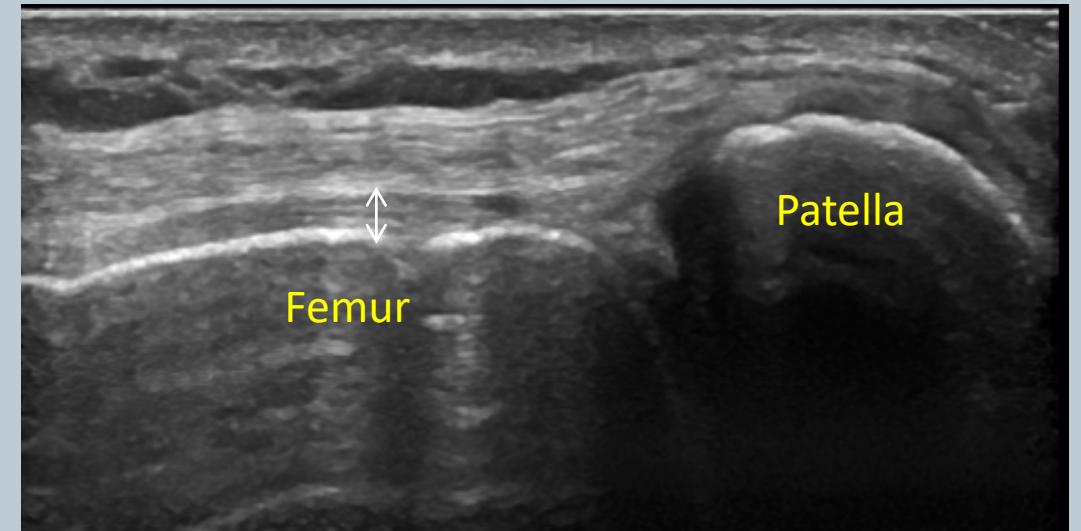
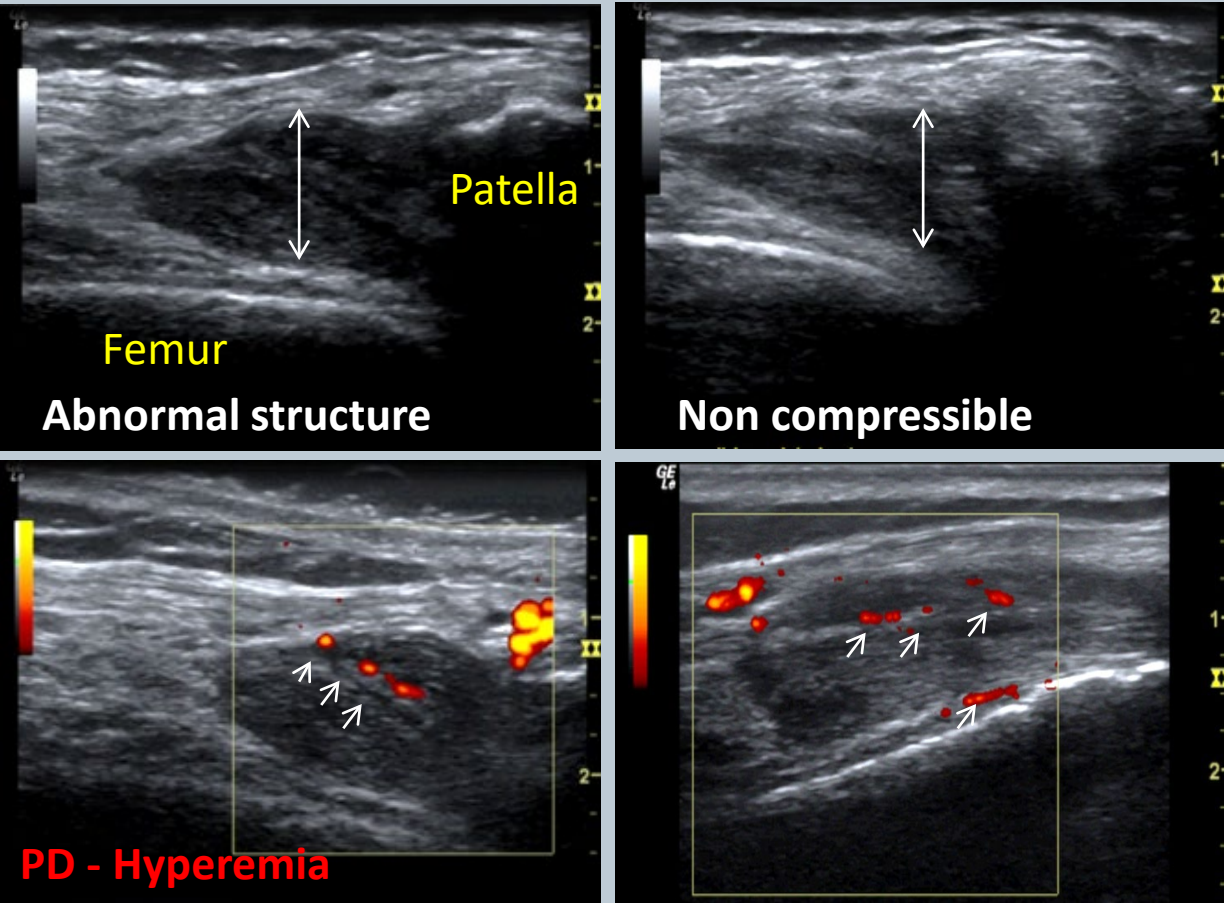
Clinical question: Bleeding or not ?

**“not” = Synovitis, Arthritis,
+/- Effusion**



Patient

Normal



Right knee
Lateral recess

Results/Treatment Plan

Findings Lateral Recess SAX

Soft tissue expansion (non compressible)

Inflammation (PD signal present with the soft tissue)

Diagnosis

Findings most suggestive:

Synovial hypertrophy with synovitis

Treatment

Bypassing infusion x 1 with simultaneous ultrasound-guided cortico-steroid injection

Teaching points:

1) It's not bleeding but synovitis

2) MSKUS-guided management provided long-lasting symptom relief

3) Saved patient and payers from multiple, repeated intravenous injections of bypassing agents based on clinical suspicion only

Hemophilia

A case of acute joint pain

?

Bleeding or not

ANNETTE VON DRYGALSKI, MD, PHARM.D, RMSK

PROFESSOR OF CLINICAL MEDICINE

DIRECTOR, HEMOPHILIA & THROMBOSIS TREATMENT CENTER

UNIVERSITY OF CALIFORNIA SAN DIEGO

Case : 23 y/o male with severe Hemophilia B

Presentation

History of non-adherence and denial

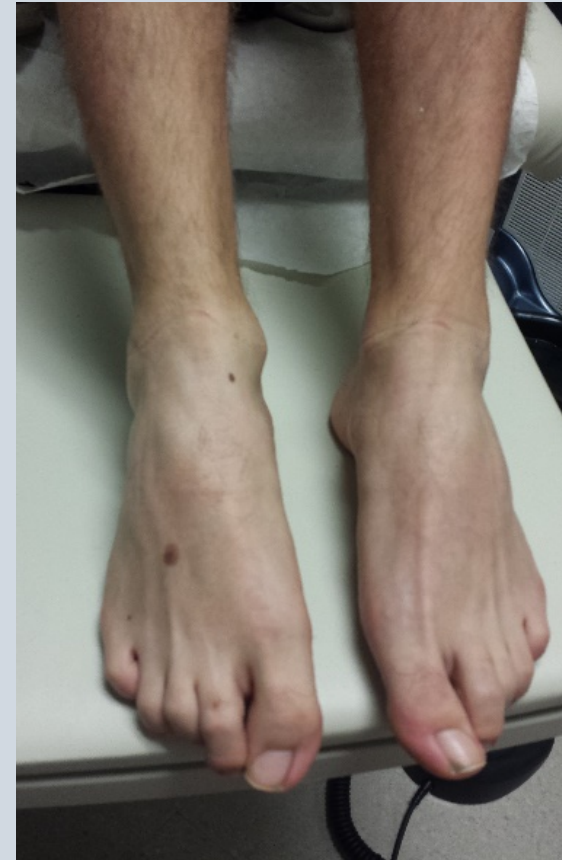Beliefs that all his pains are “arthritic”

Acute joint pain, ROM deficit and difficulty walking

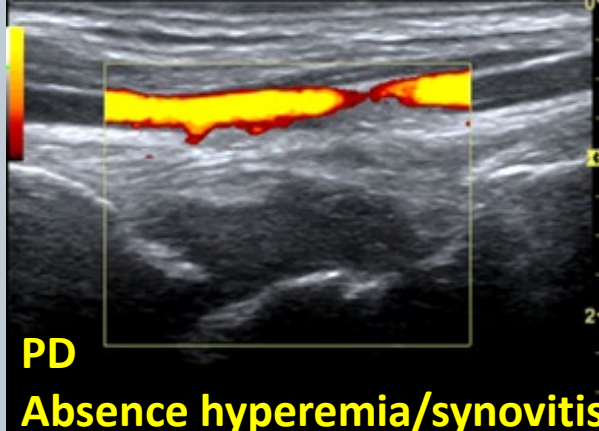
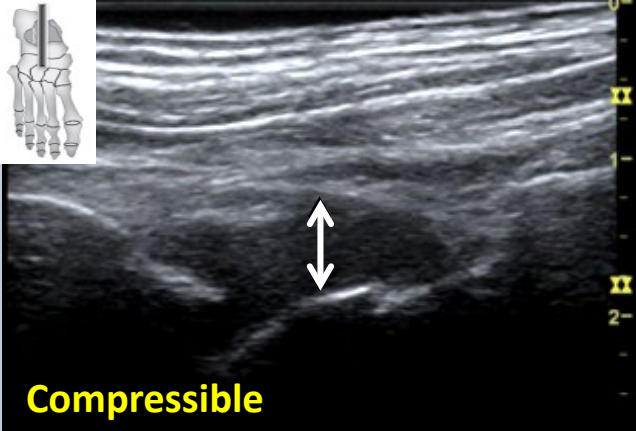
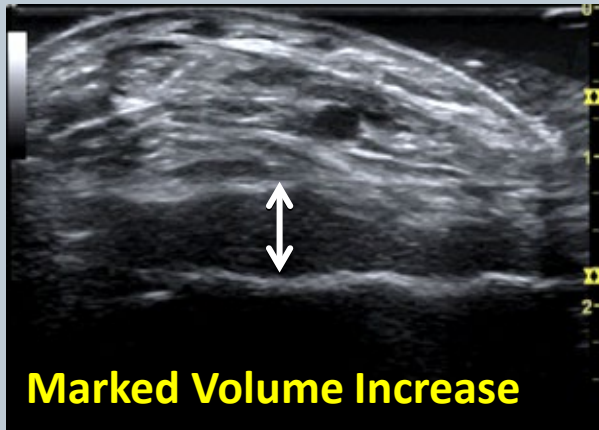
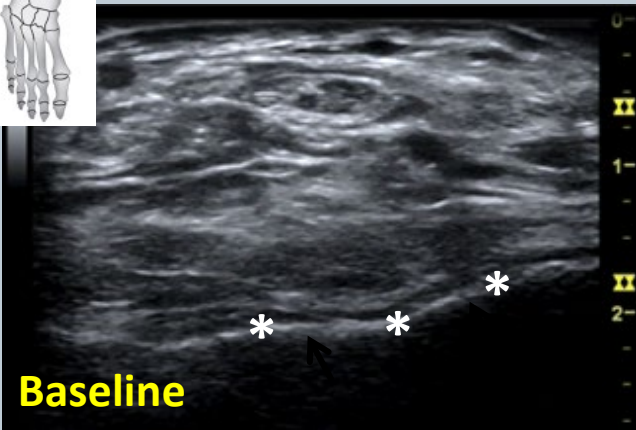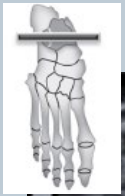Perceived “arthritic pain”

Clinical question: Bleeding or not ?

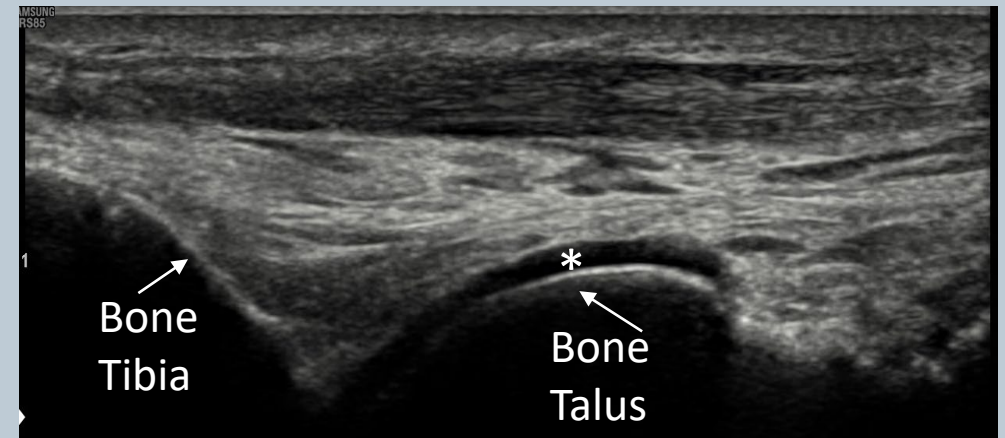
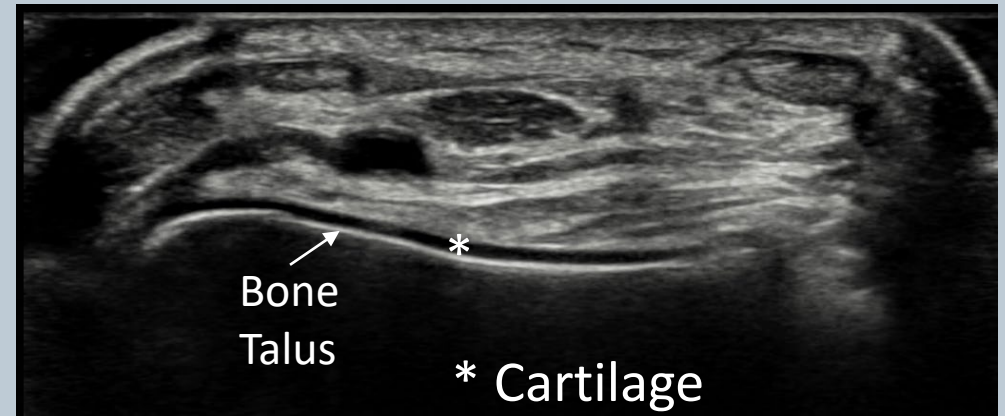
**“not” = Synovitis, Arthritis,
+/- Effusion**



Patient



Normal



Right ankle
Tibiotalar joint space: short and long axis

Results/Treatment Plan

Findings Tibio-Talar Joint Space

Complex effusion (compressible)

Absent PD signal

Diagnosis

Findings most suggestive:

Acute Hemarthrosis

Treatment

FIX-infusion daily x3

Education regarding the importance of clotting factor prophylaxis

Teaching points:

1) It's not arthritis but hemarthrosis

2) Clinical presentation can be inconspicuous

3) Ultrasound images supported patient education with improved adherence thereafter