

Lumps & Bumps!

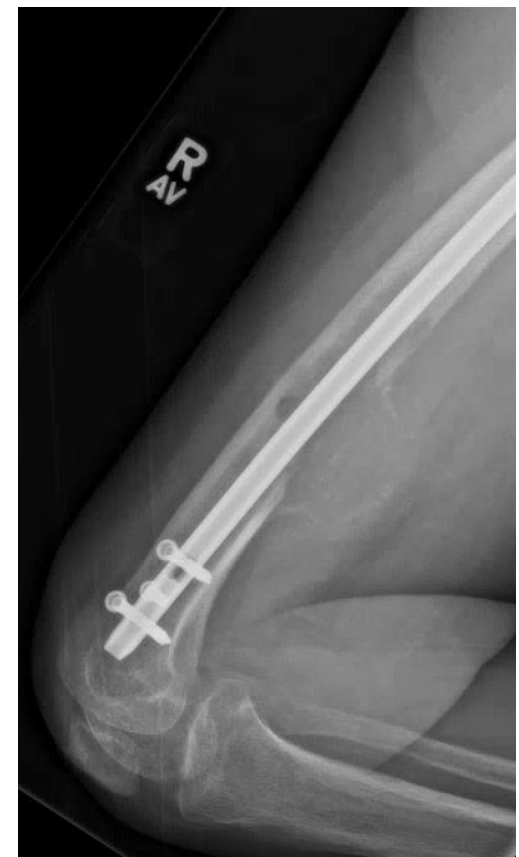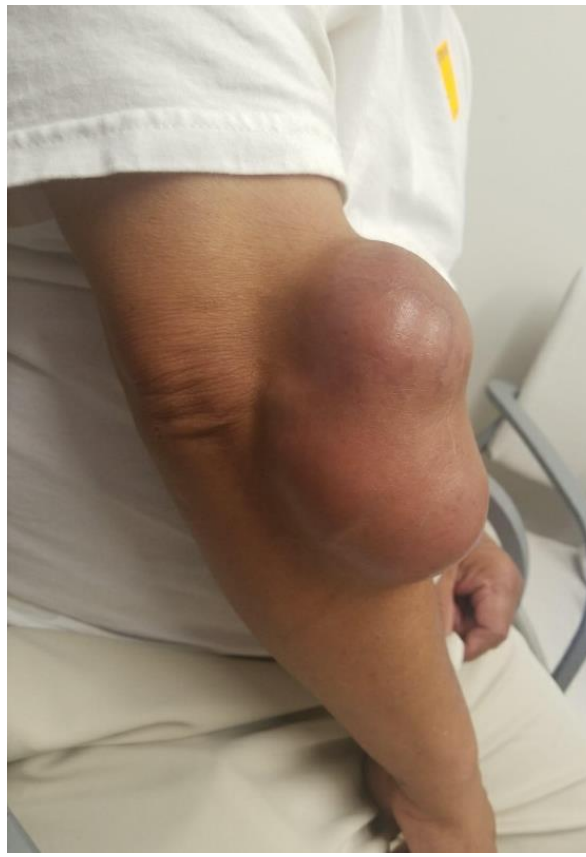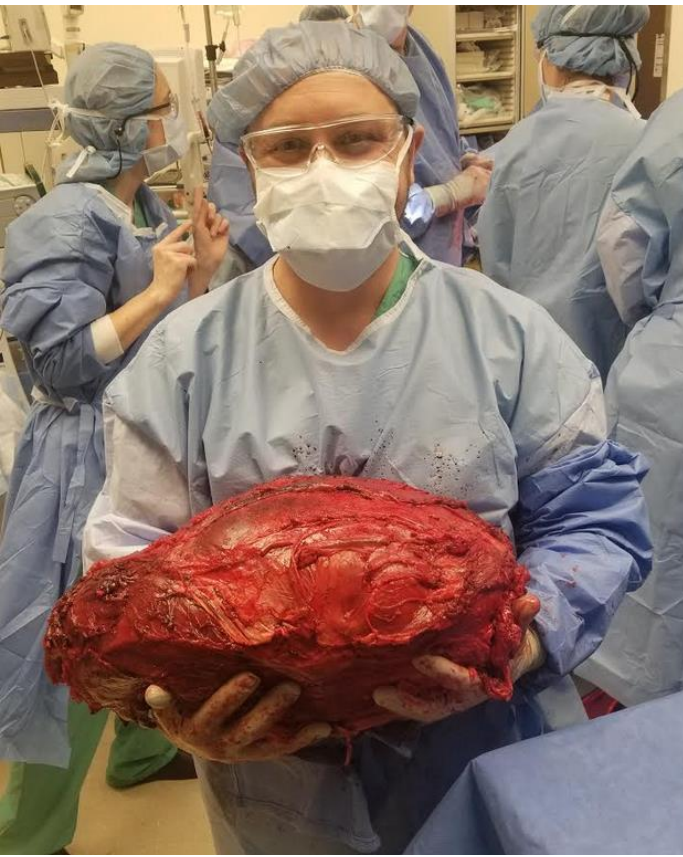Frank Chiarappa

Orthopaedic Oncology

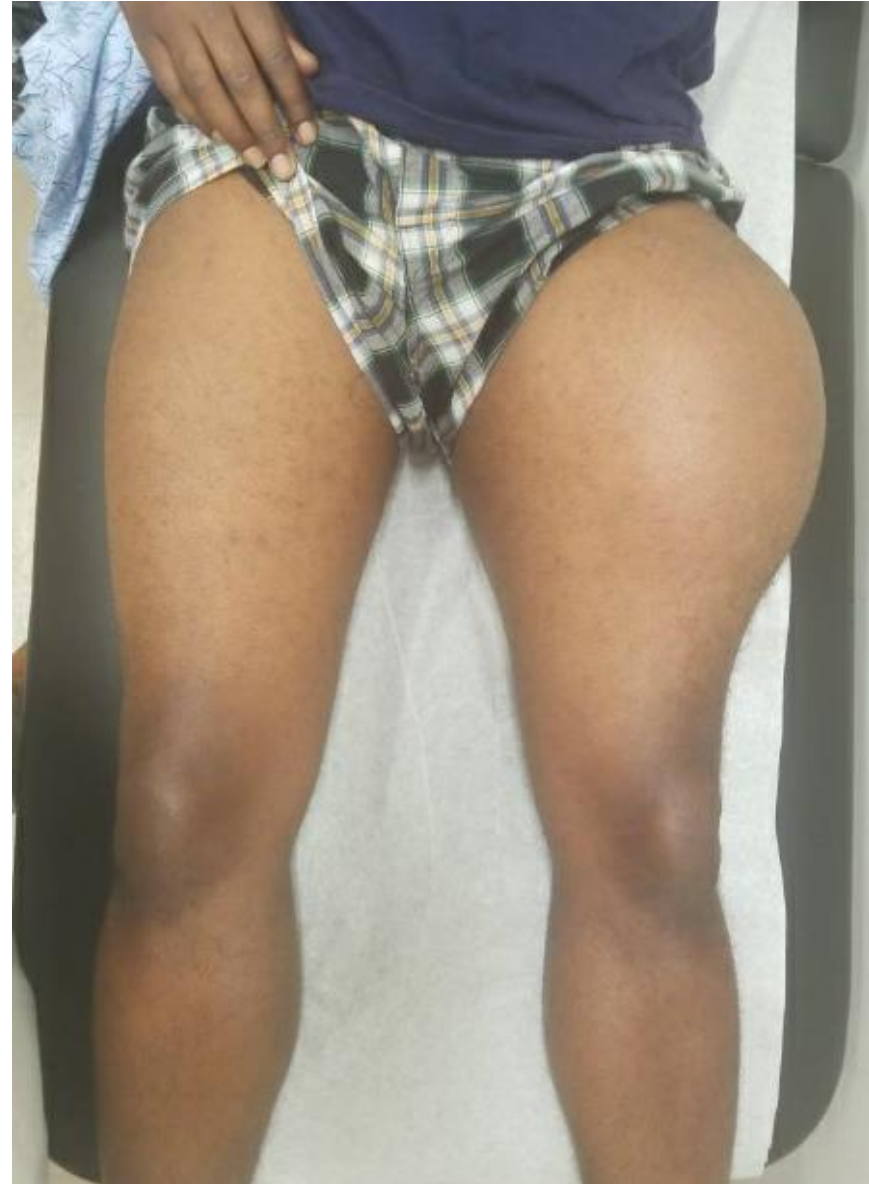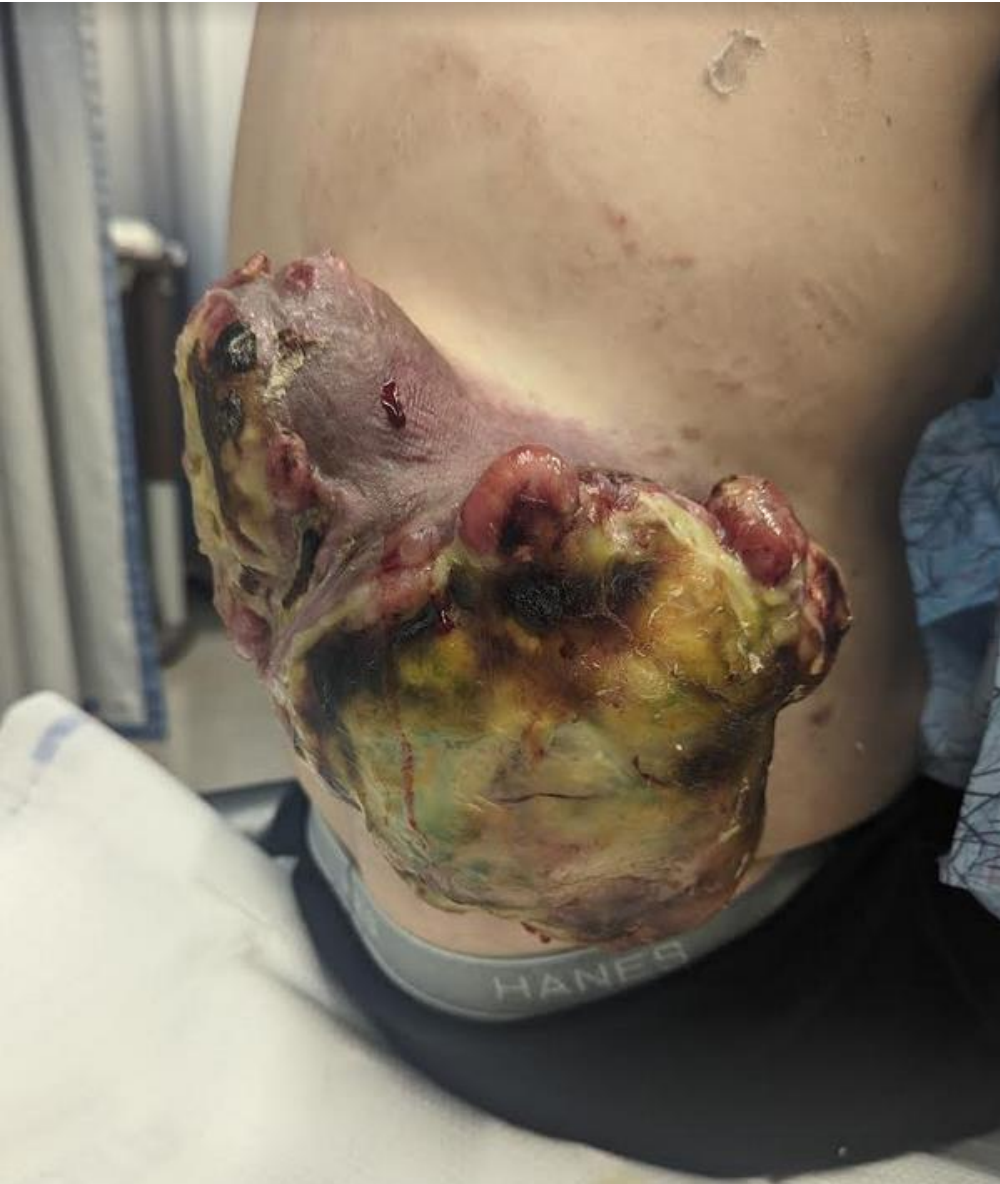12.6.23

What is an Orthopaedic Oncologist?

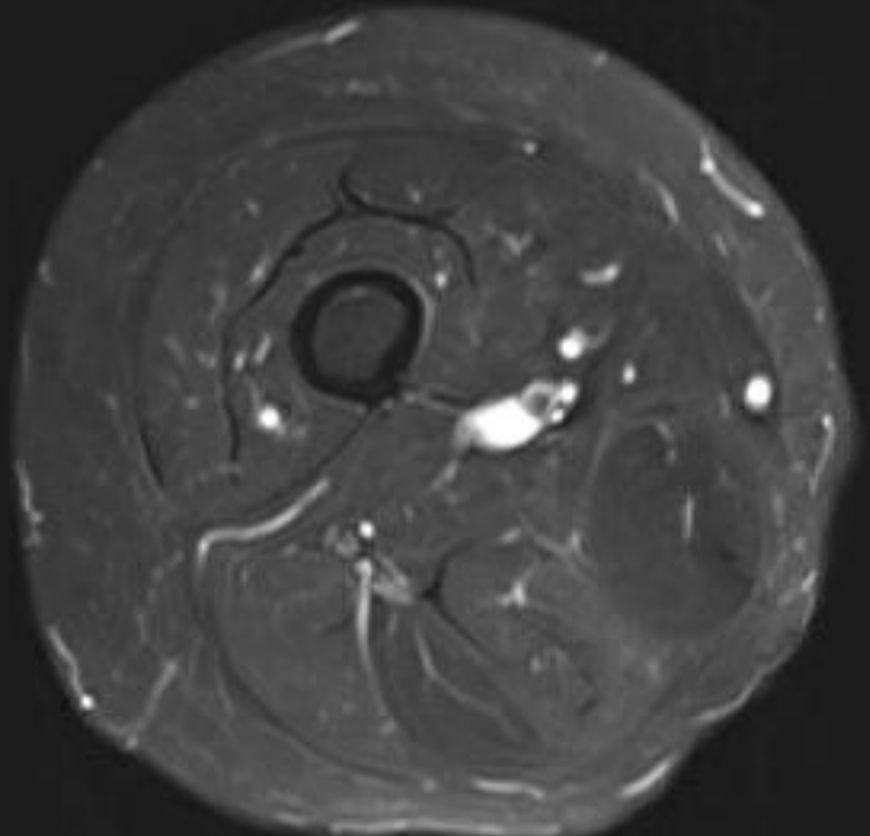
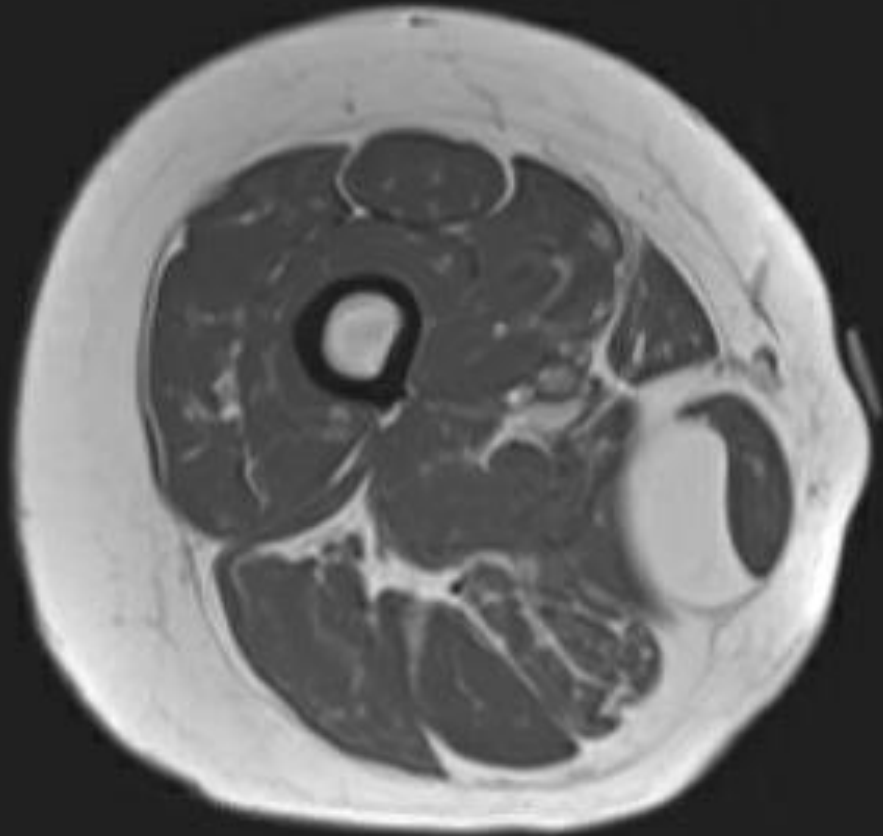
- Limb salvage (sarcoma)
- Benign tumors (lumps & bumps)
- Metastatic bone disease



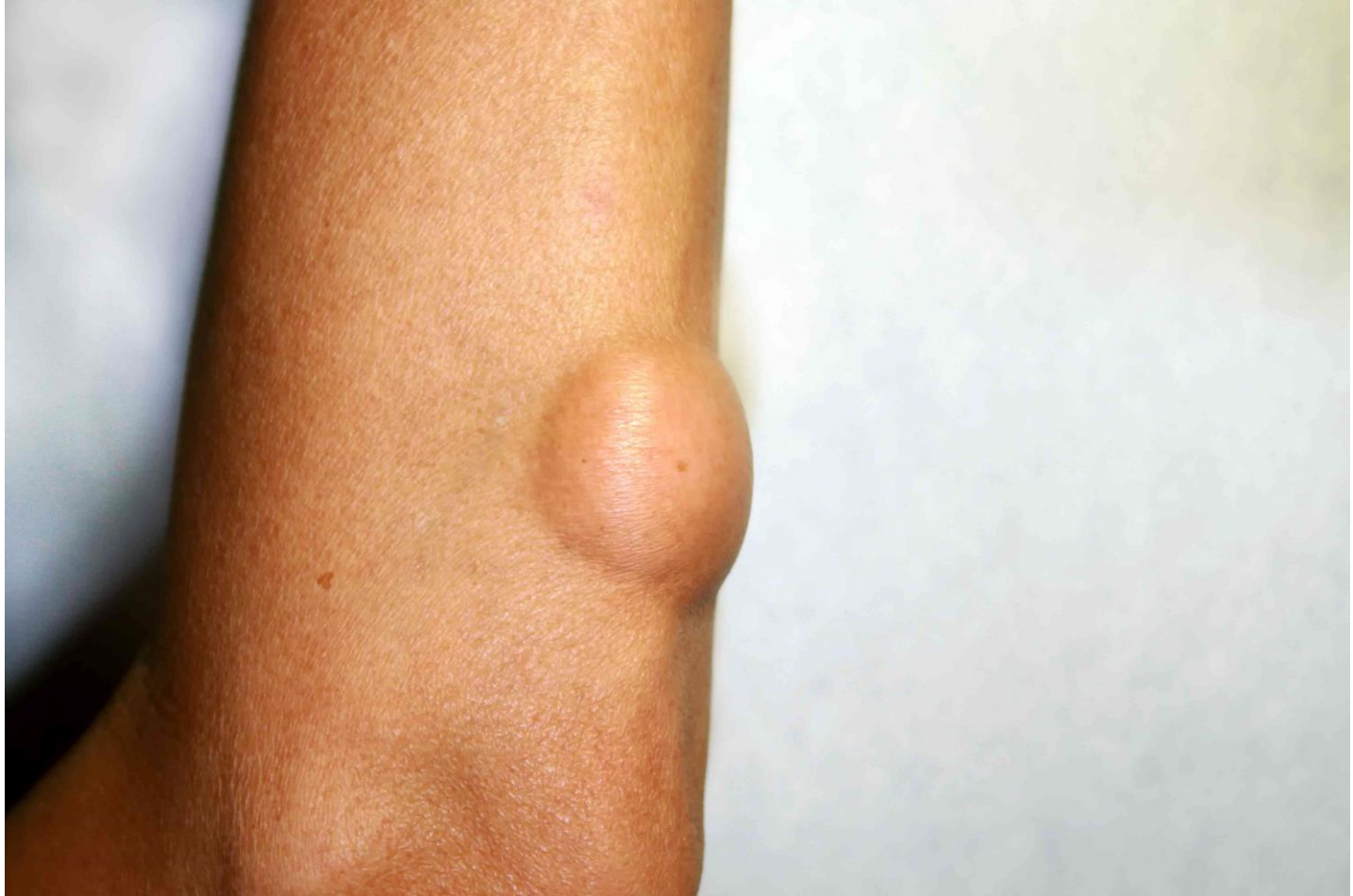Sometimes the lump finds you!



Sometimes incidental



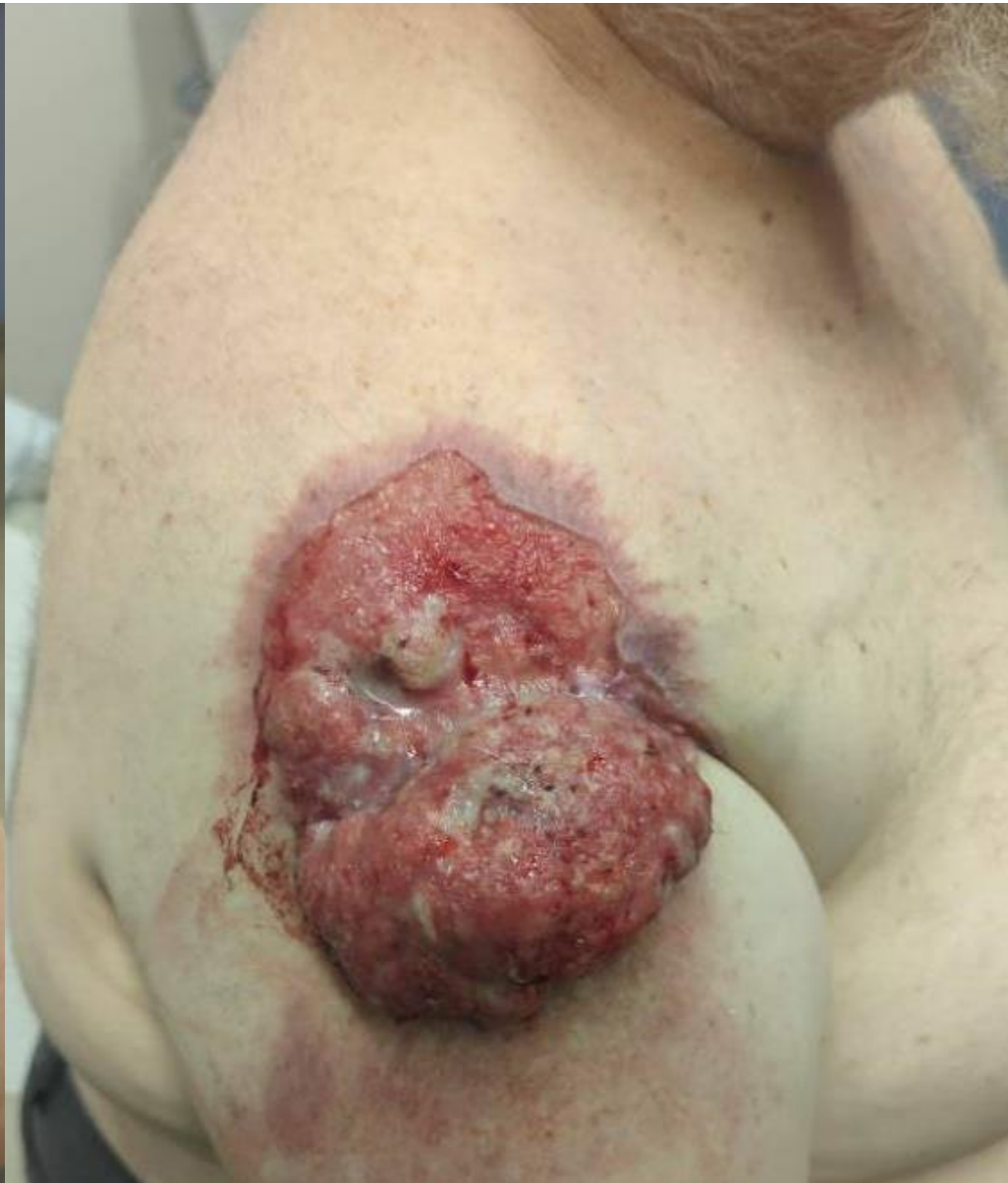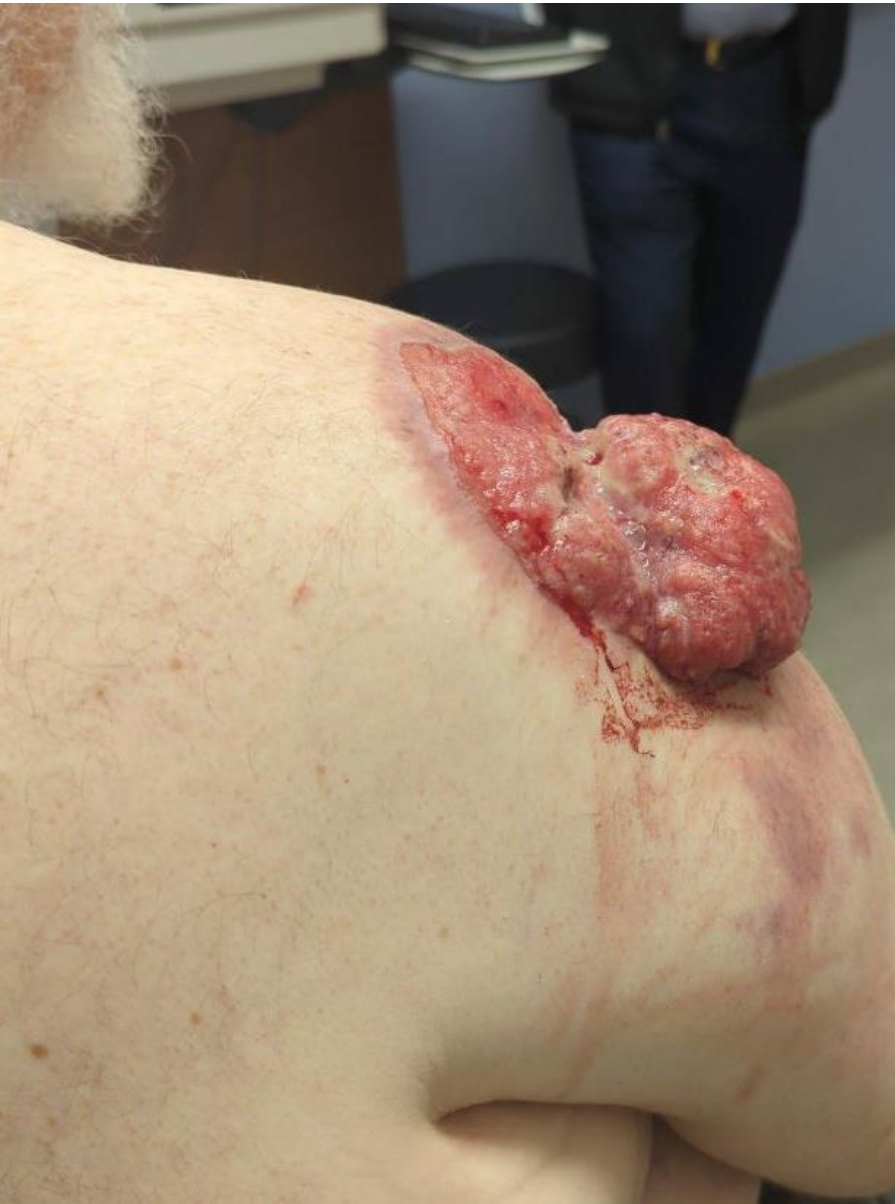Doc, I have this lump.



Exam

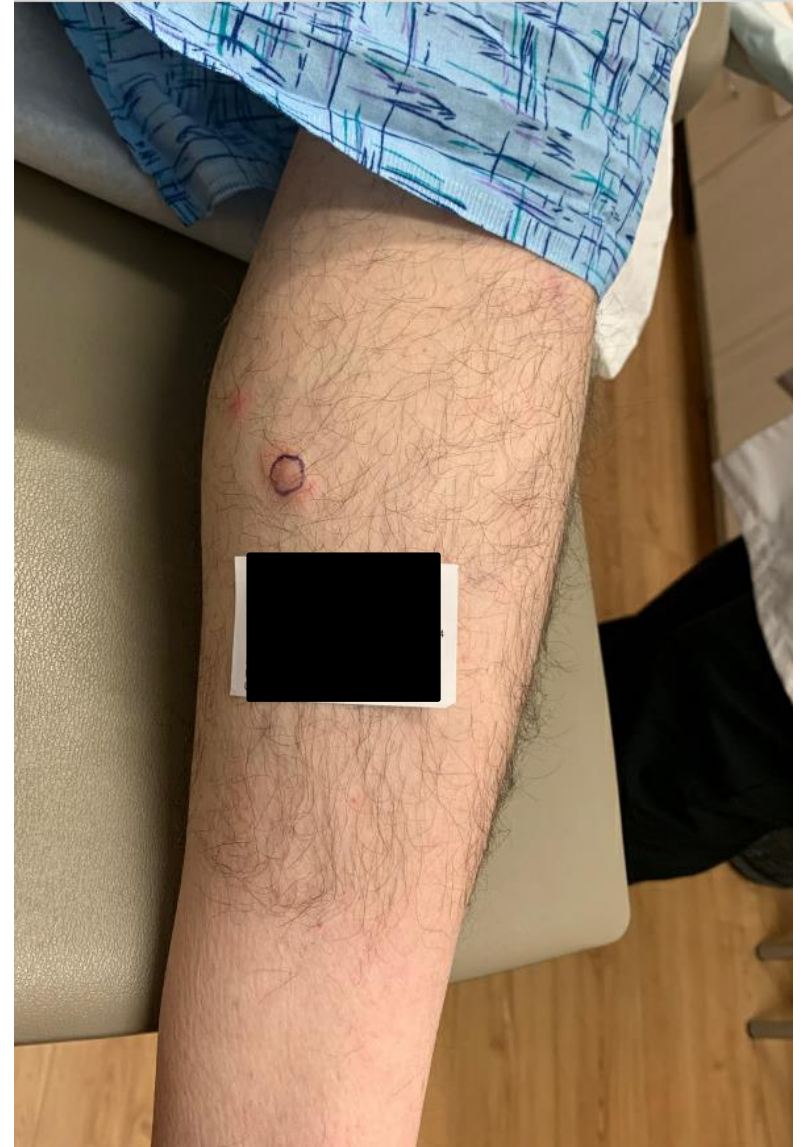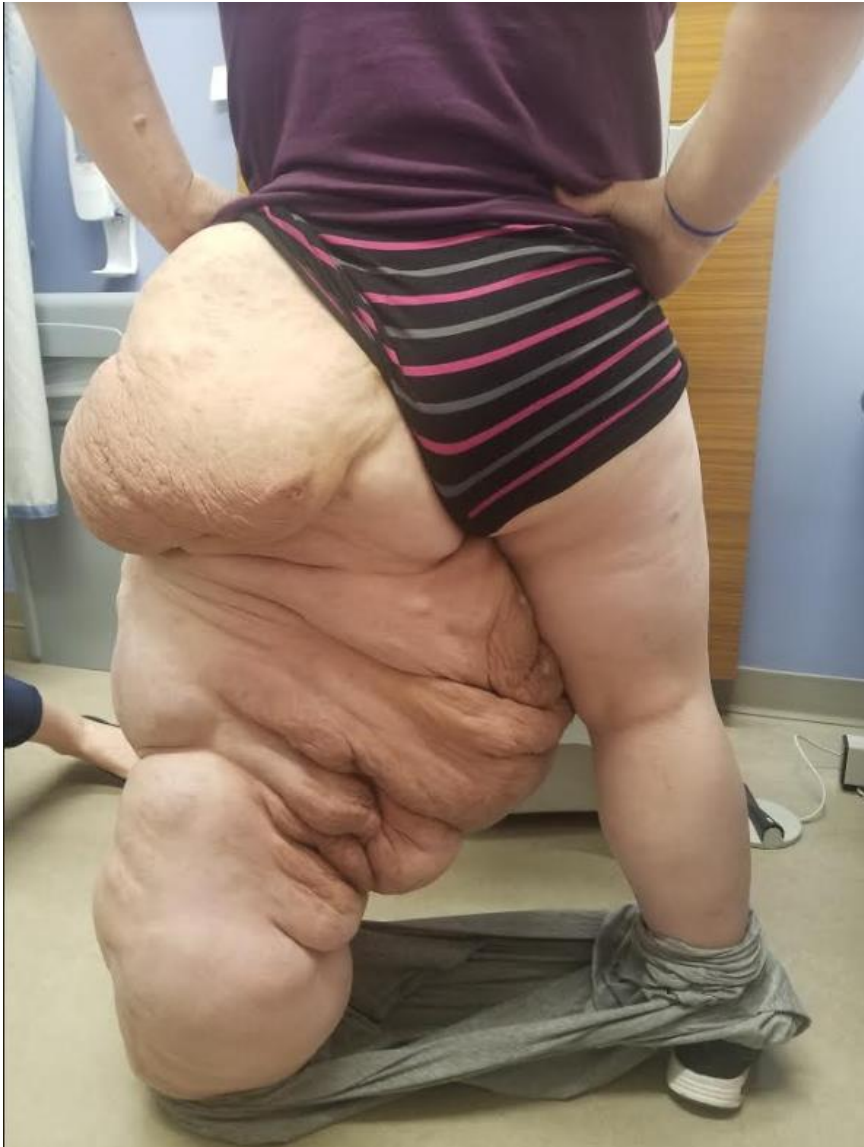- Firm or soft?
- Mobile?
- Multiple?
- Transilluminate?
- Tinel's sign?
- Painful?
- Regional lymph nodes?
- History of malignancy?

Doc, I have THIS lump.



Does size matter?

Or depth?



Imaging

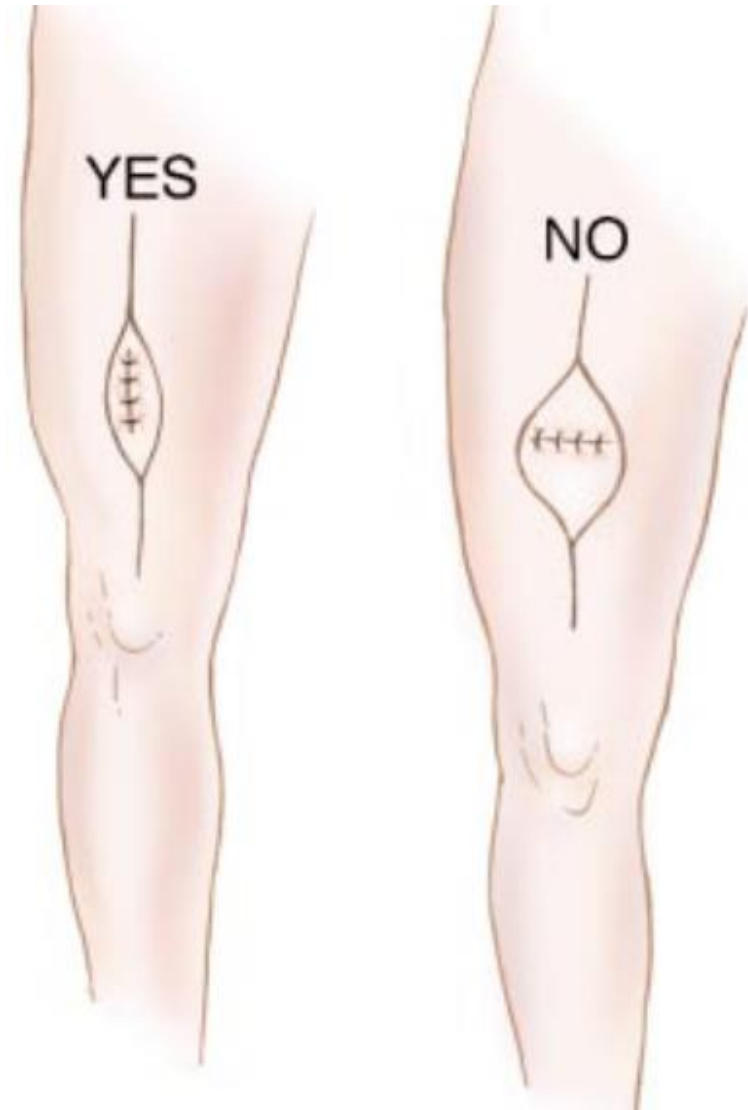
- US has limited role
- MRI
 - Contrast for tumors & infections
 - Prior to biopsy or surgery
- Clinical “trajectory” is important

Labs

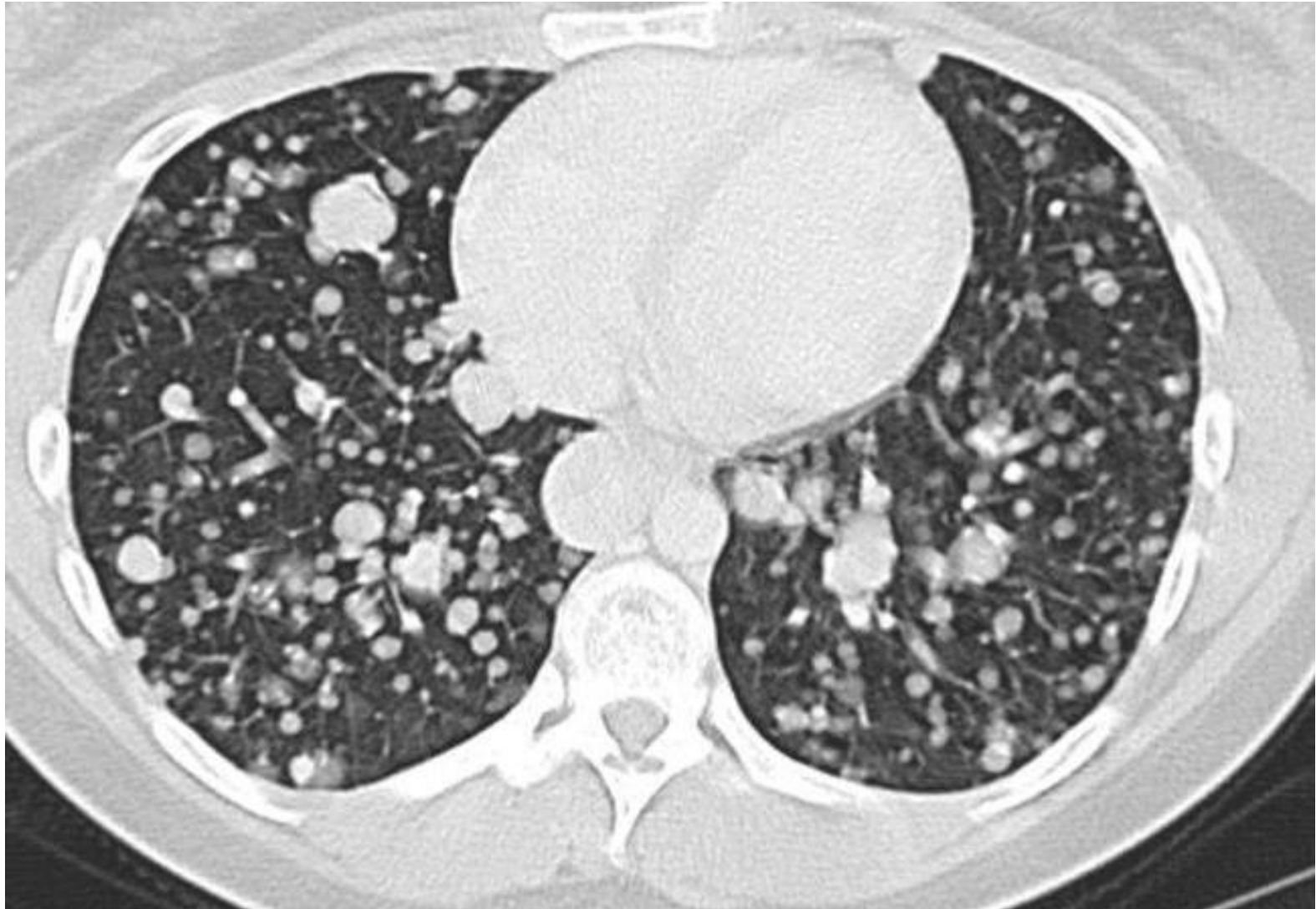- Limited

Biopsy

- Excisional biopsy OK if small
- **Longitudinal incision**
- Core needle, not FNA
 - Architecture important
- **Along course of surgical approach**



Staging

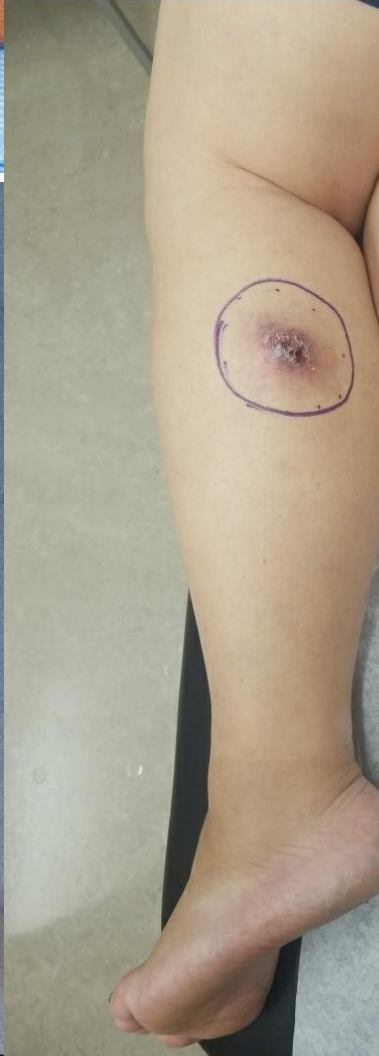
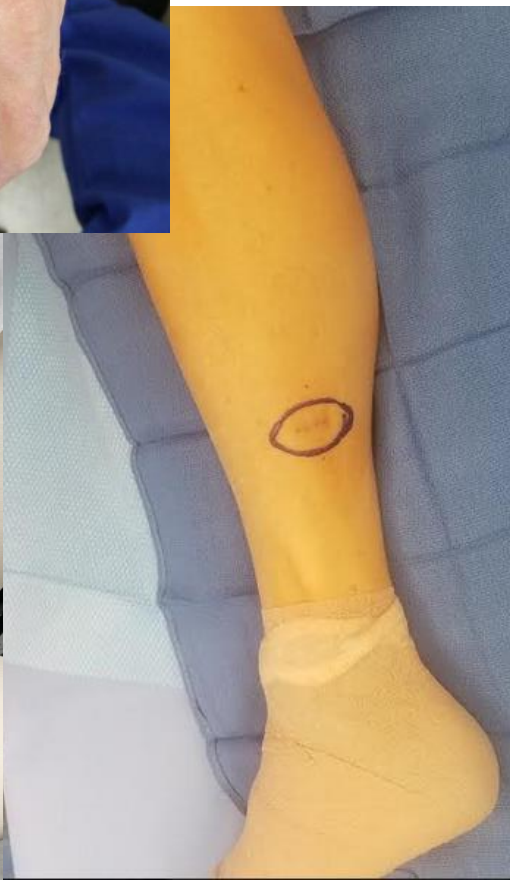
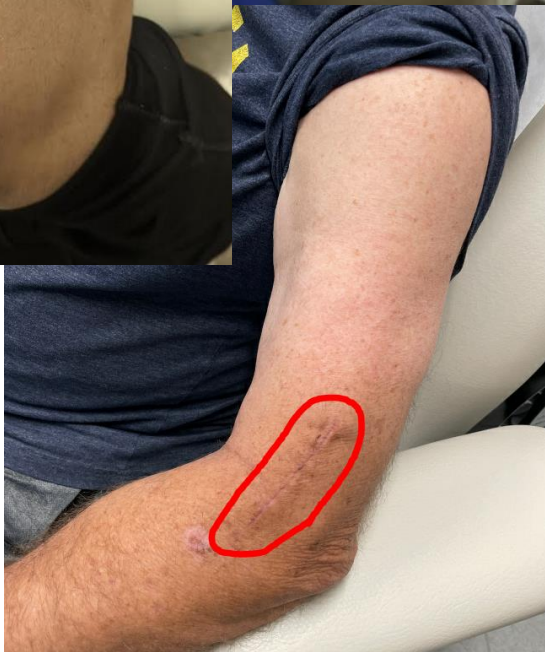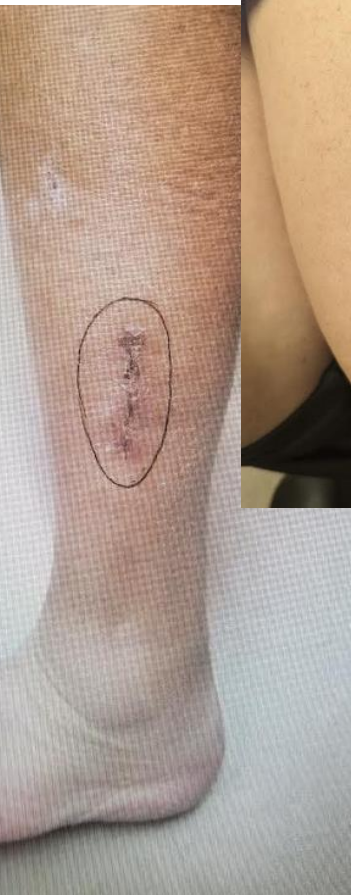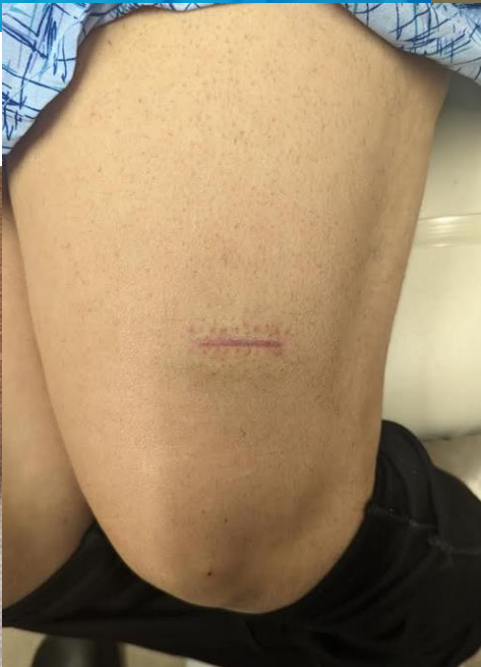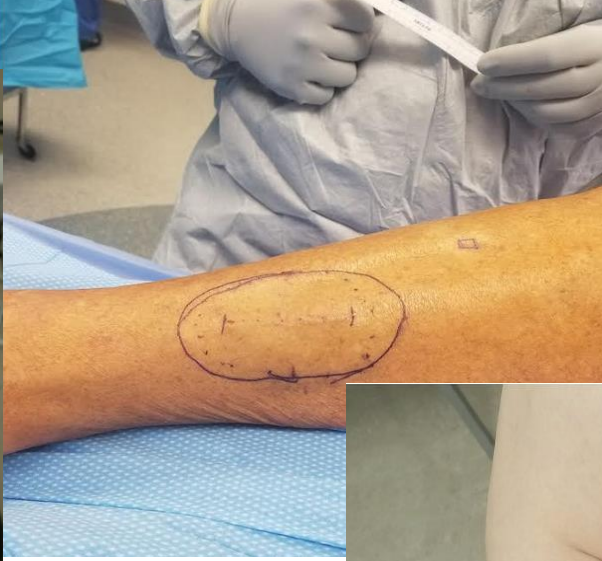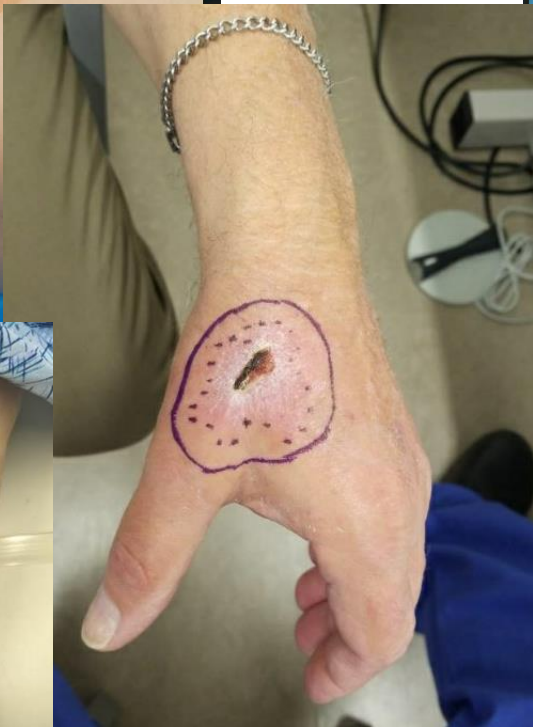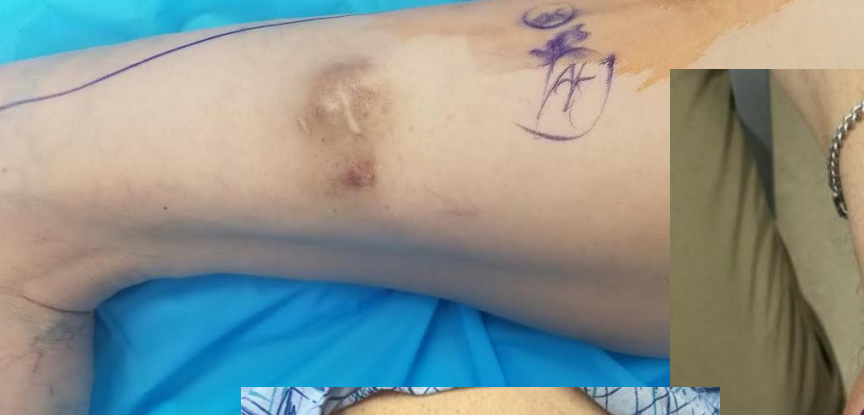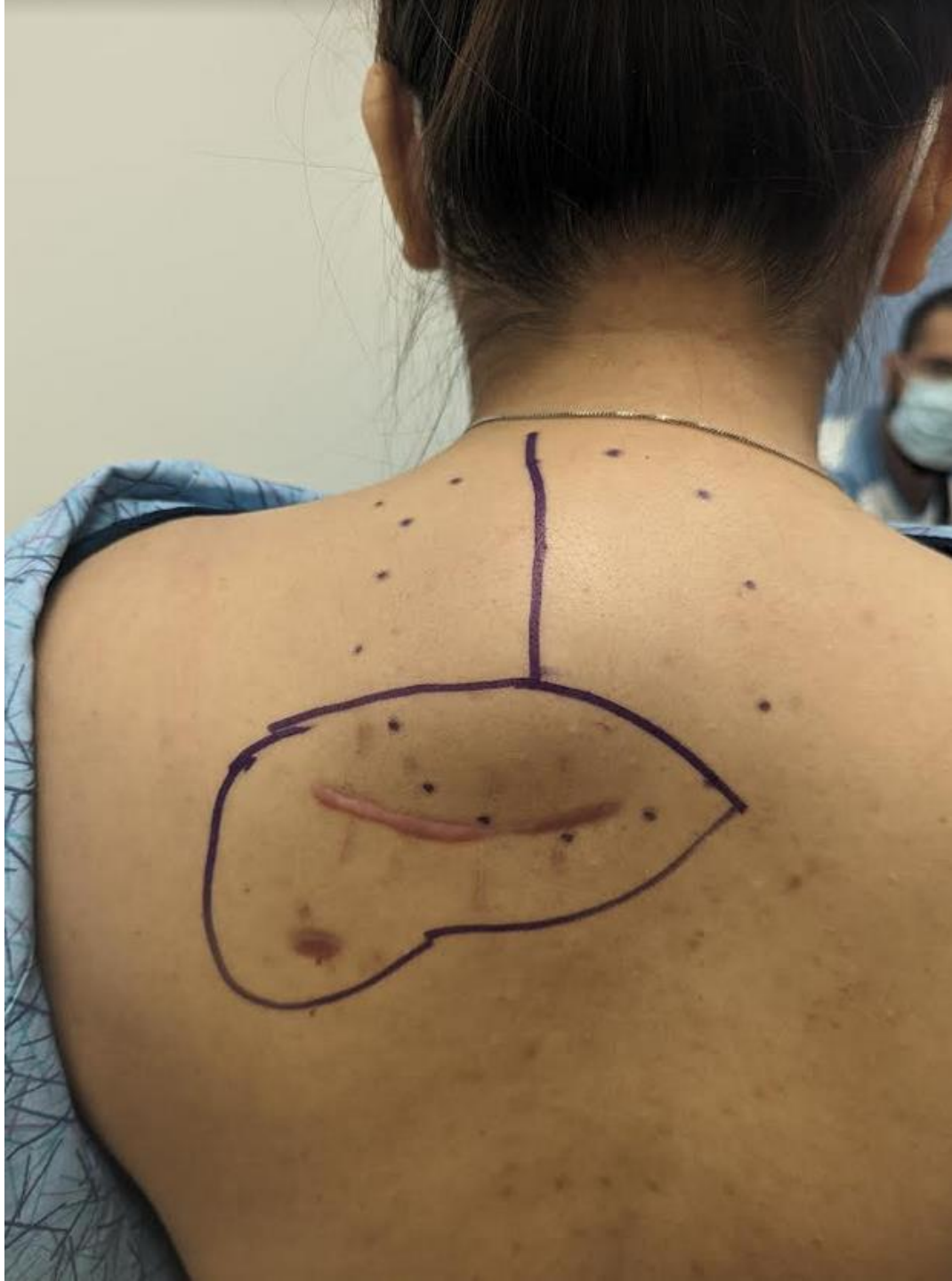Avoiding the “OOPS” procedure

JB & JS THE JOURNAL OF BONE & JOINT SURGERY



goal of obtaining wide margins. Excluding thirteen patients who had had

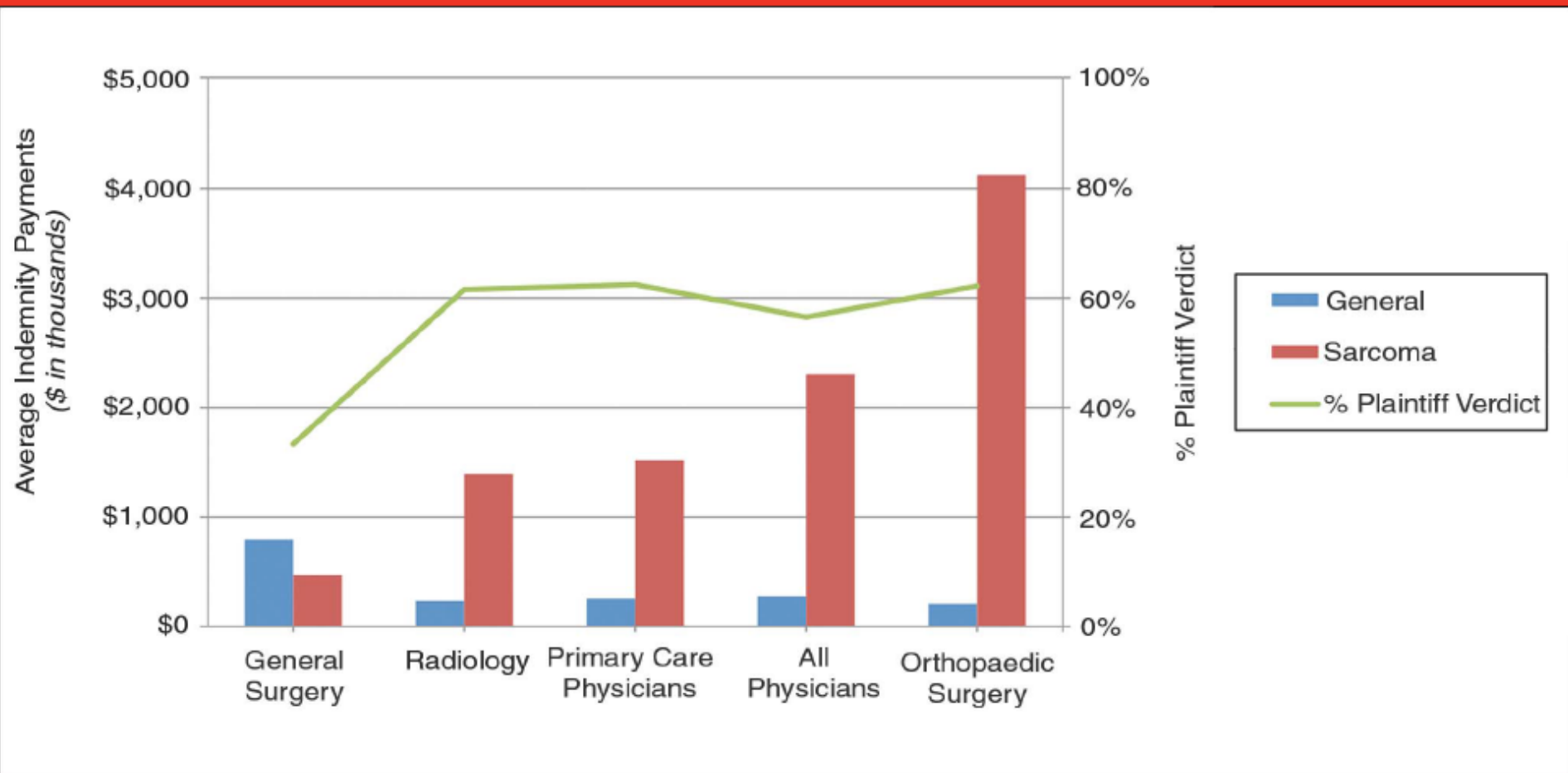




Review Article

Unplanned Resection of Sarcoma

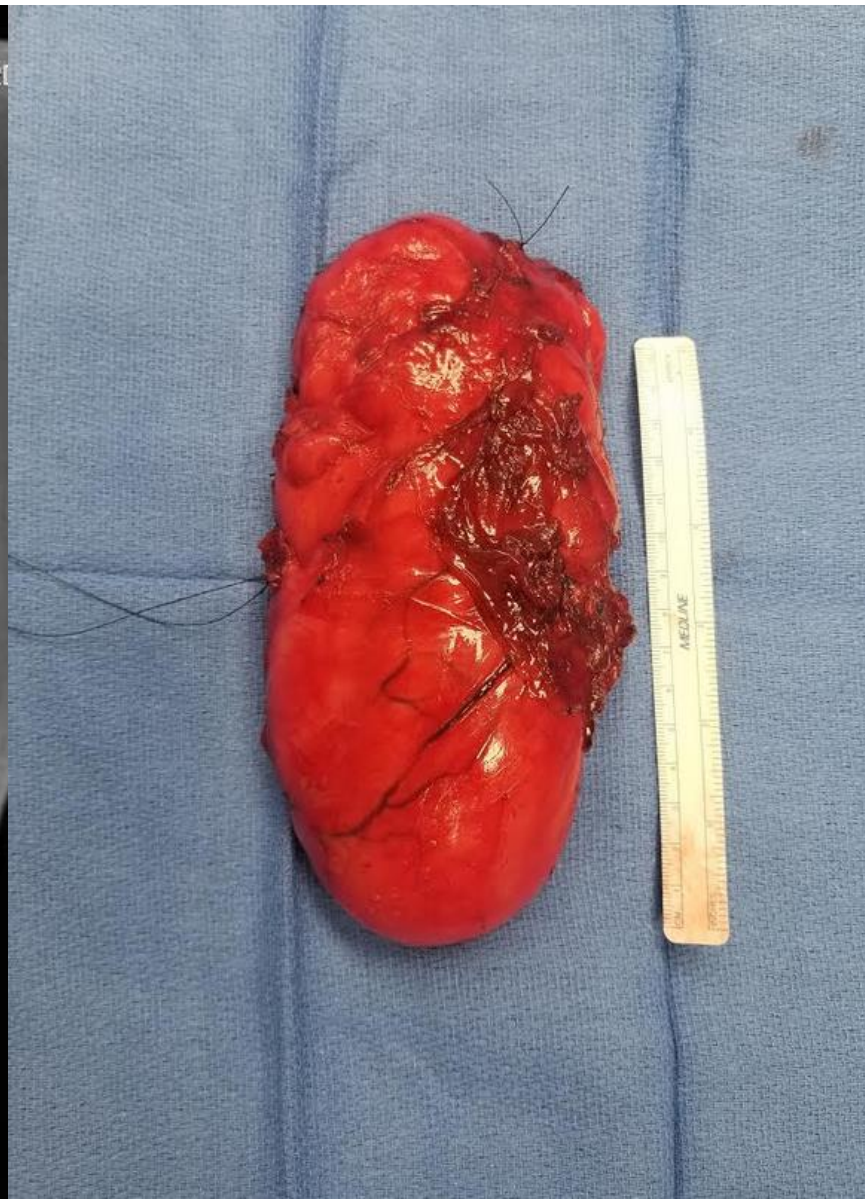
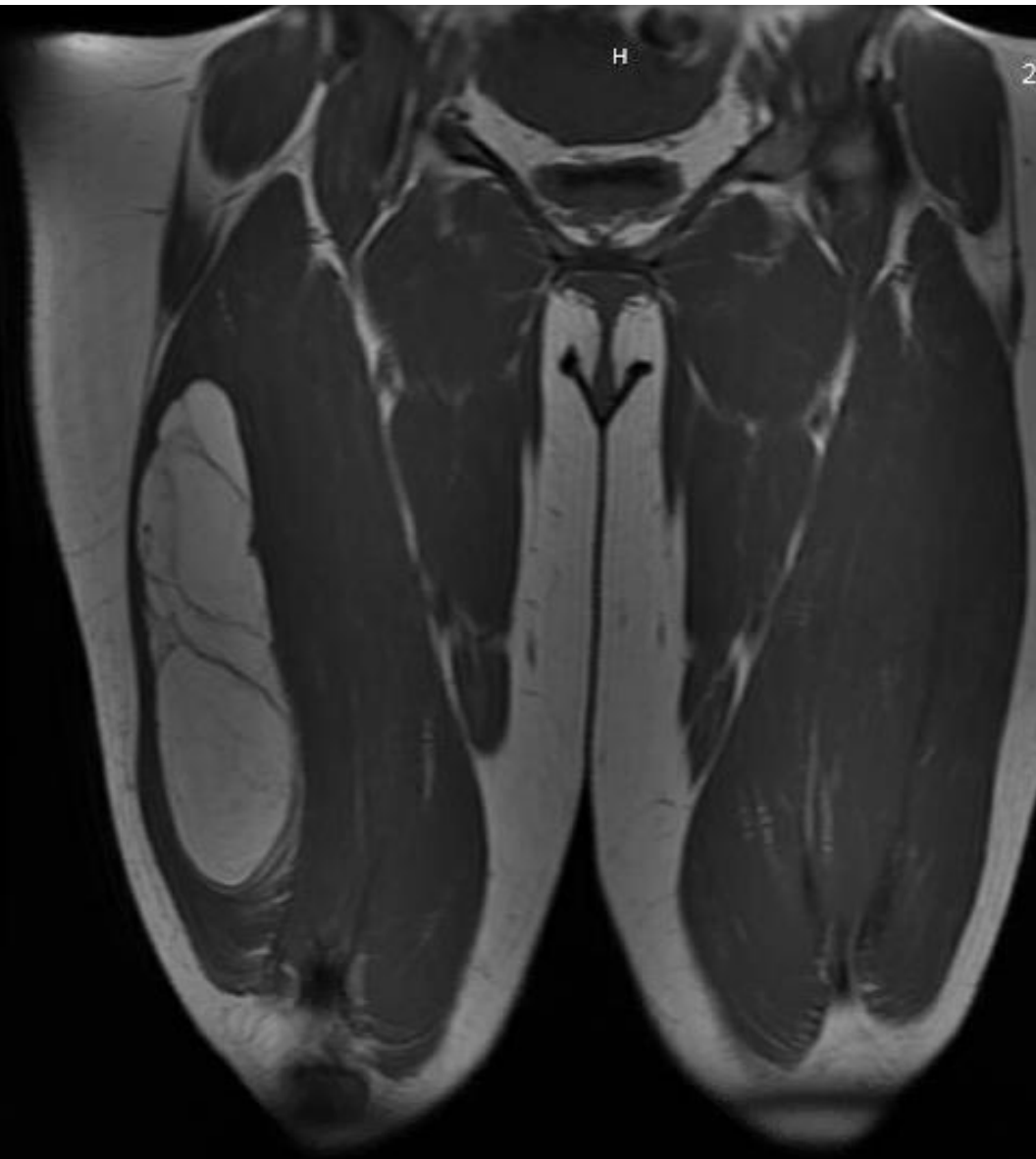
Figure 6



Documentation

- Extremely important
- Imaging/referrals
- Return precautions or followup

Lipomas

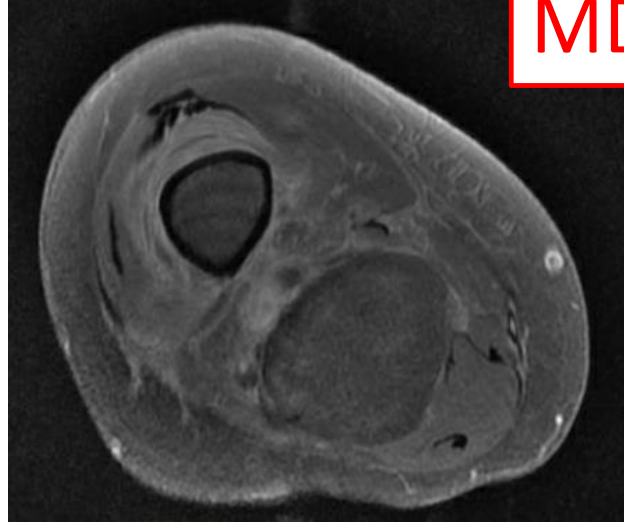
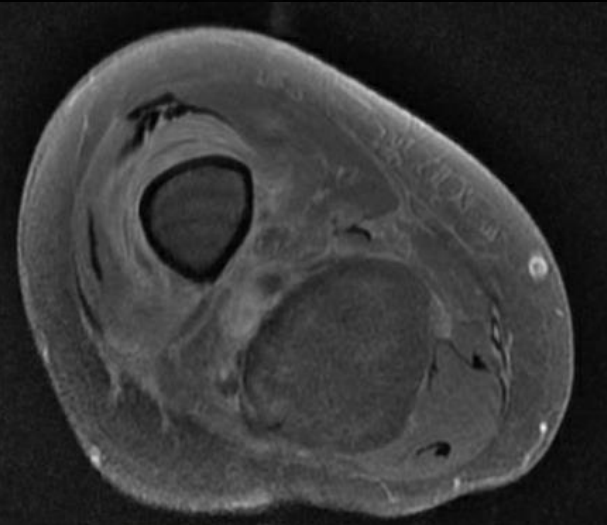
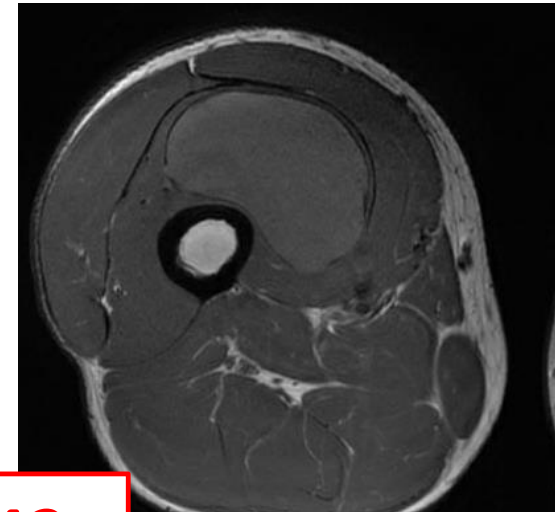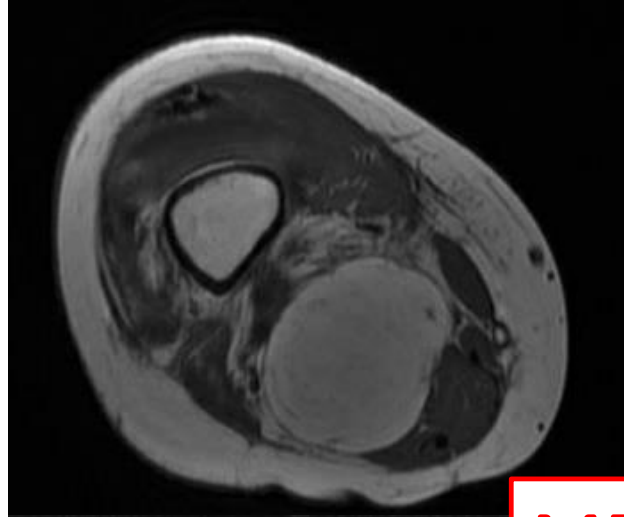
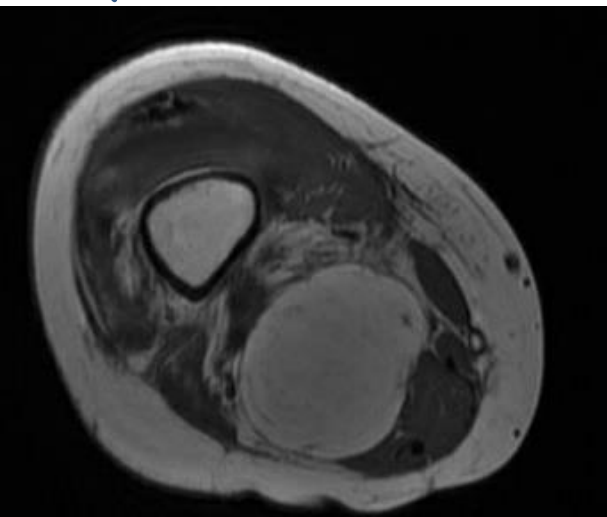


Lipomatous Tumors

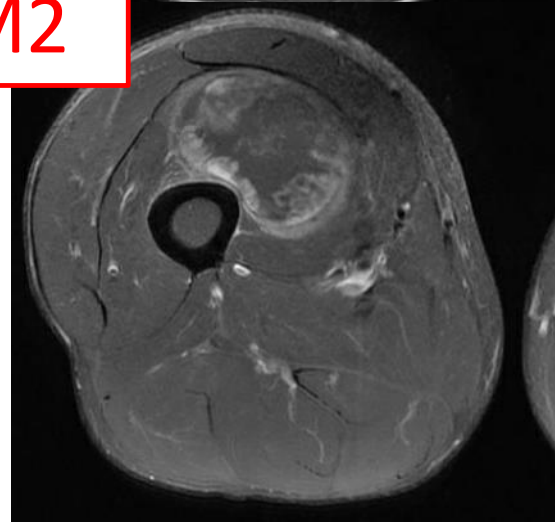
Lipoma

ALT (well-diff liposarc)

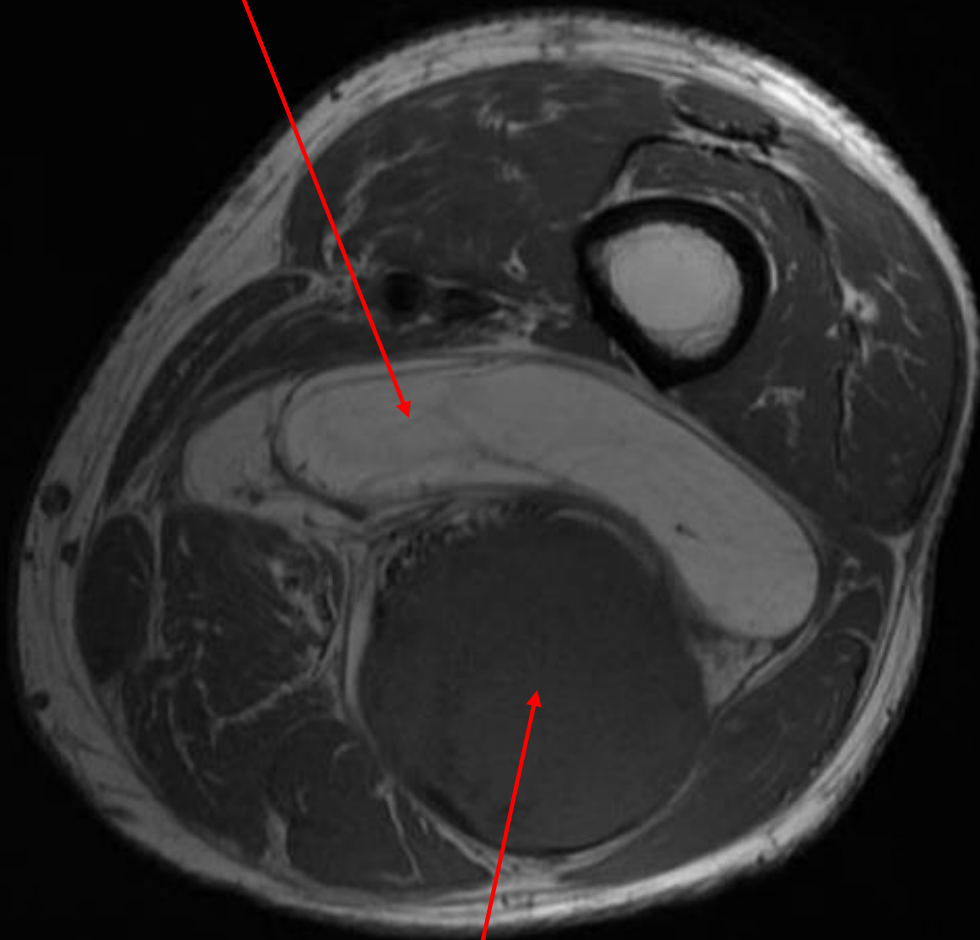
Liposarcoma



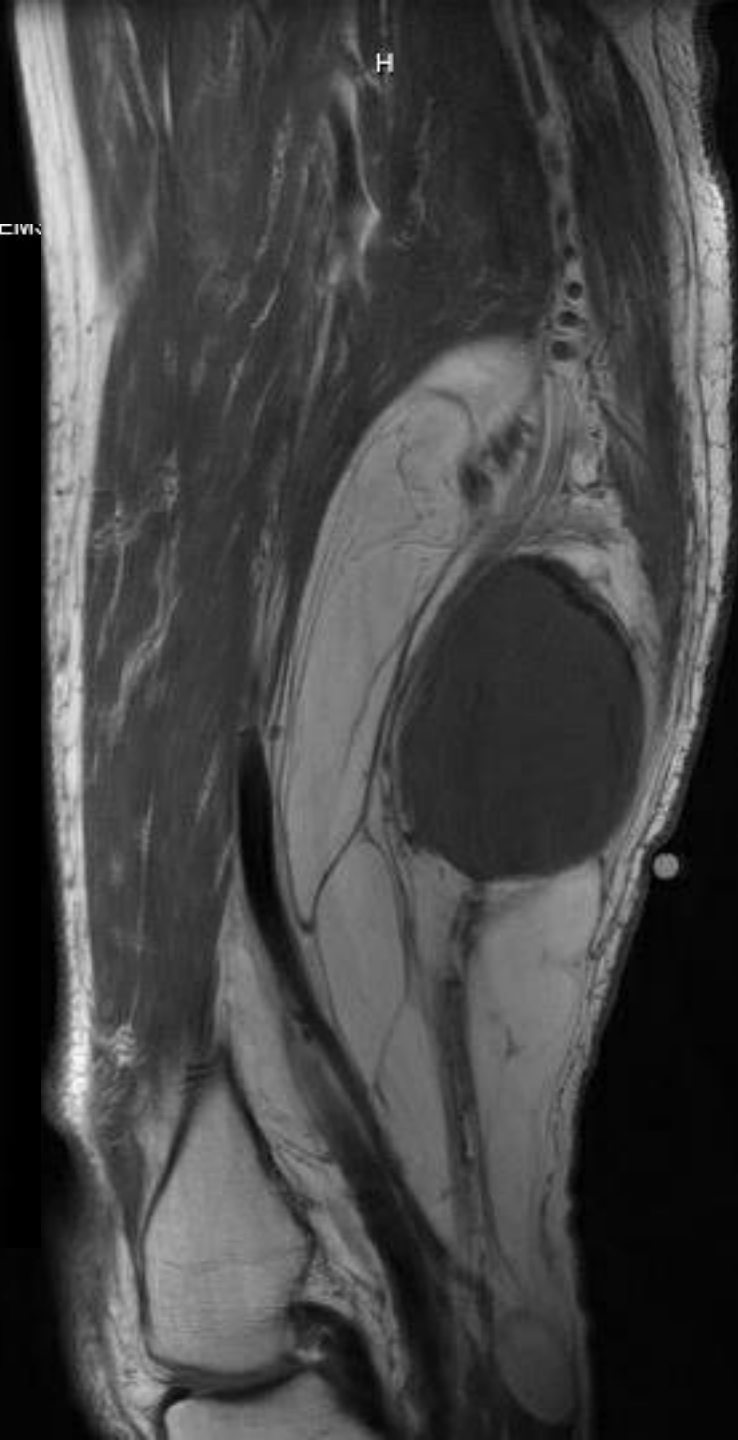
MDM2

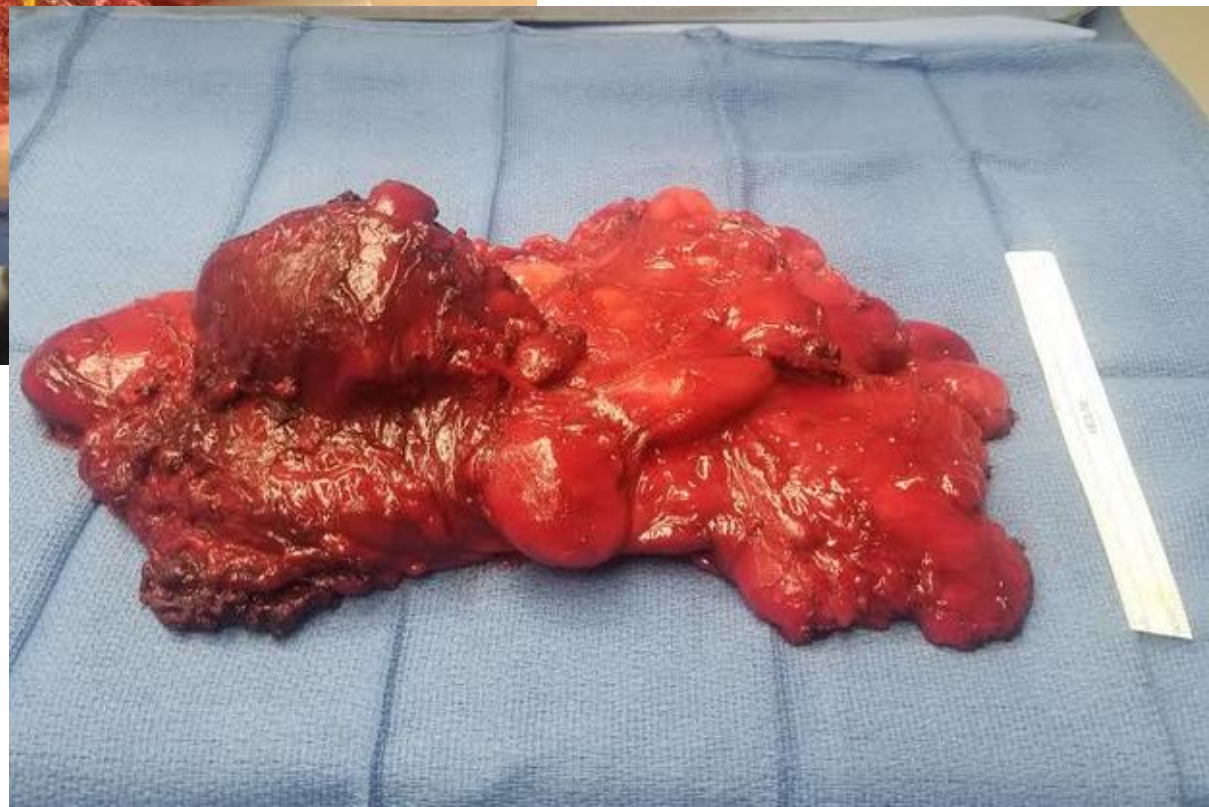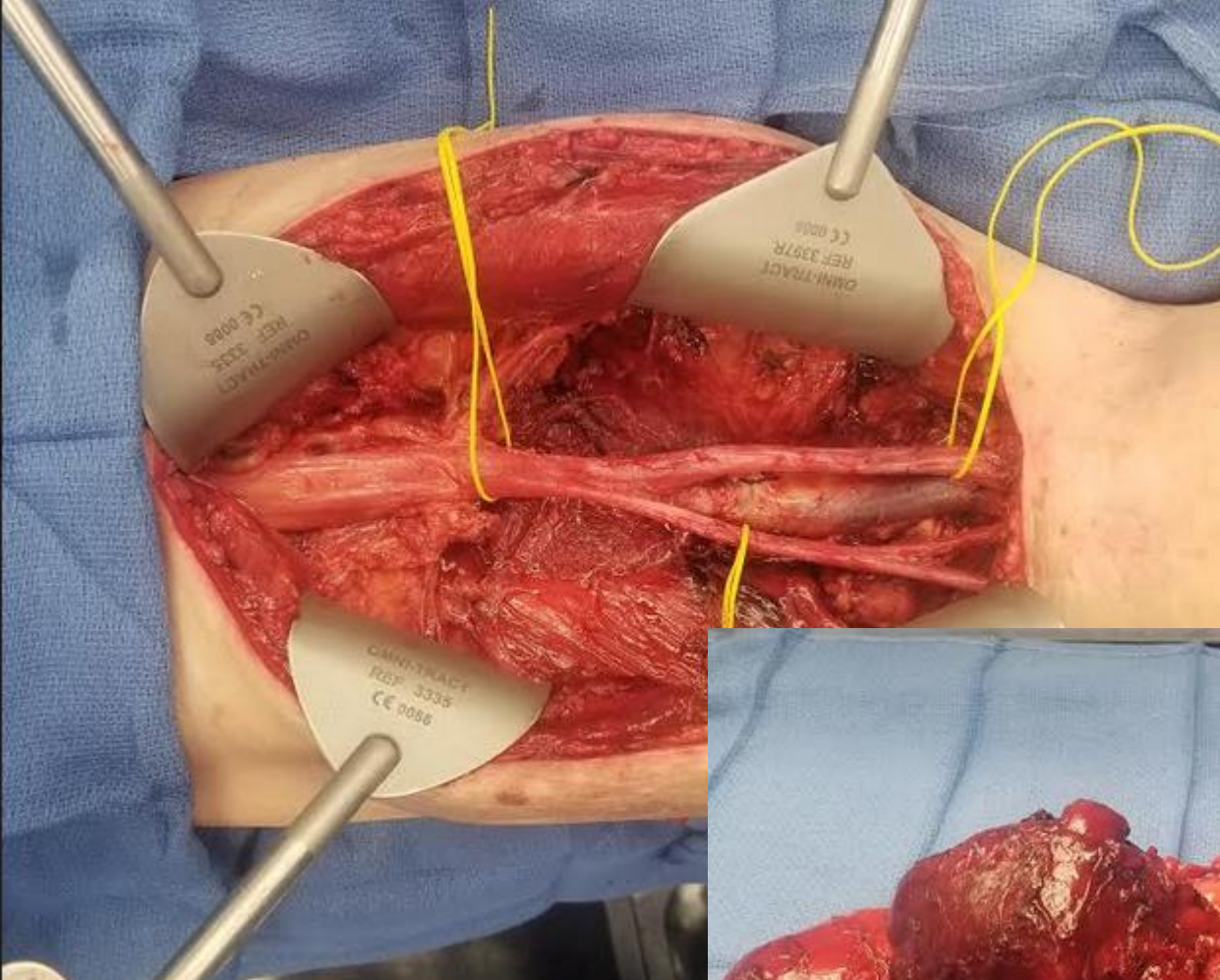


ALT/WDL

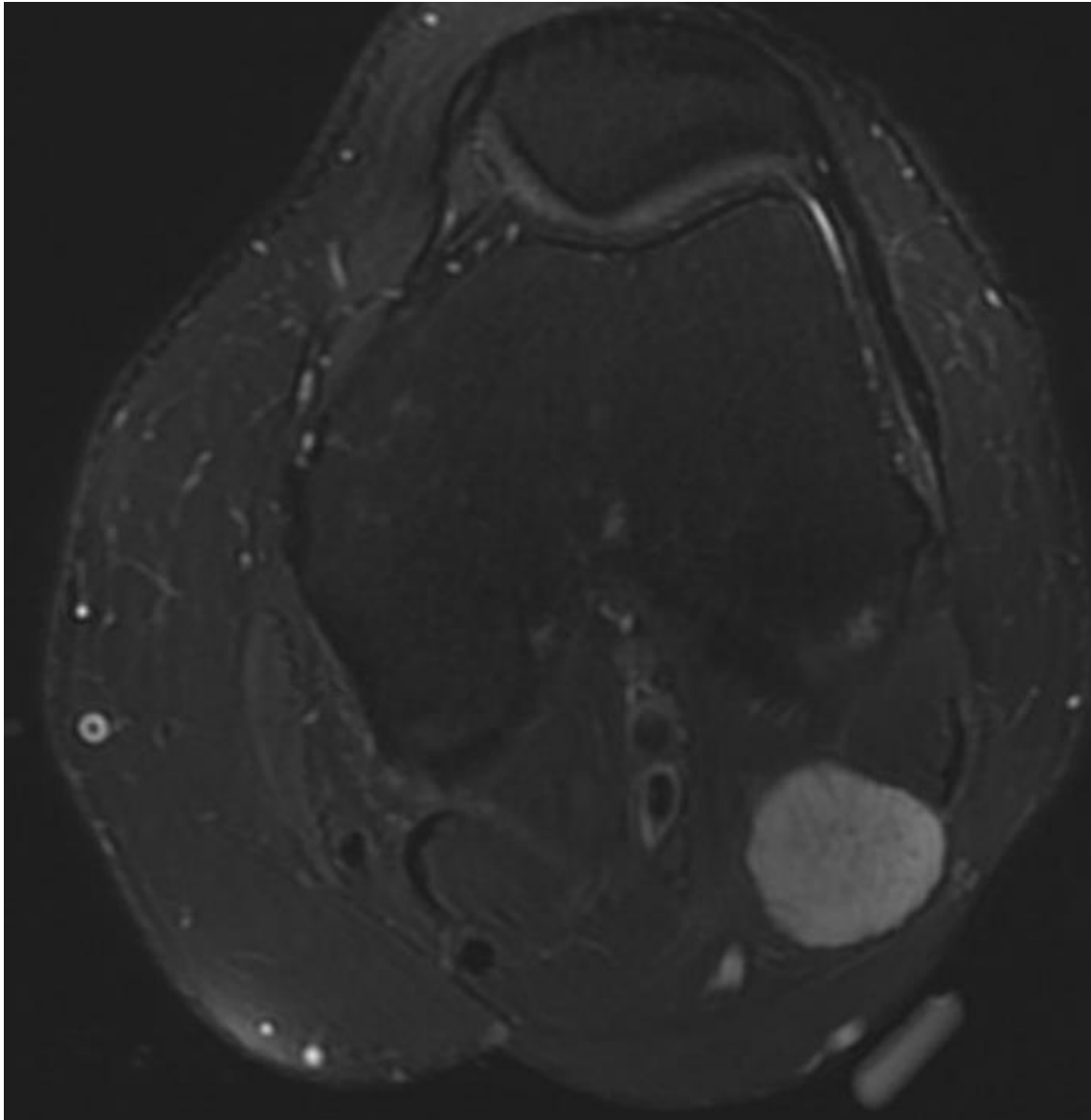


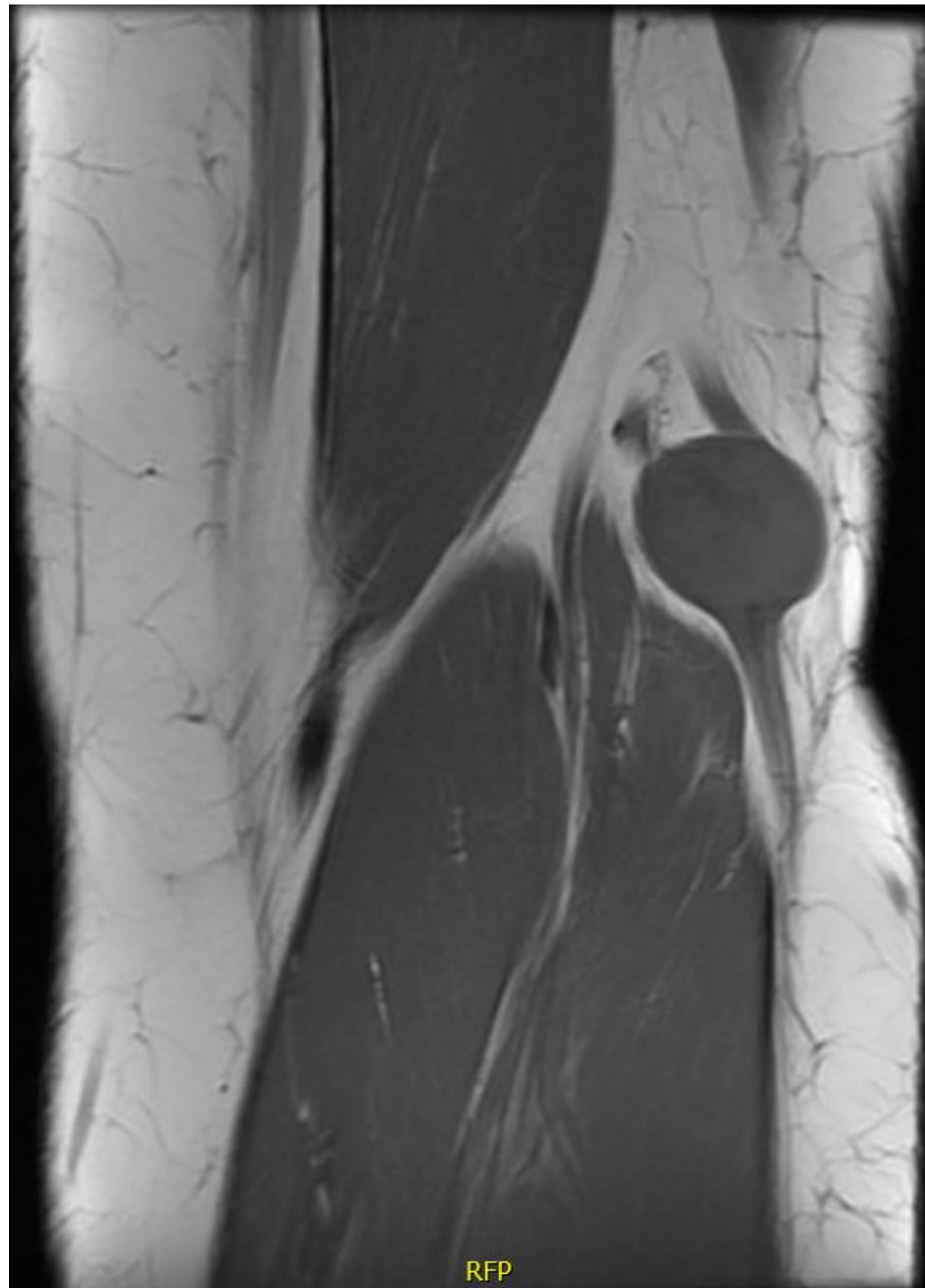
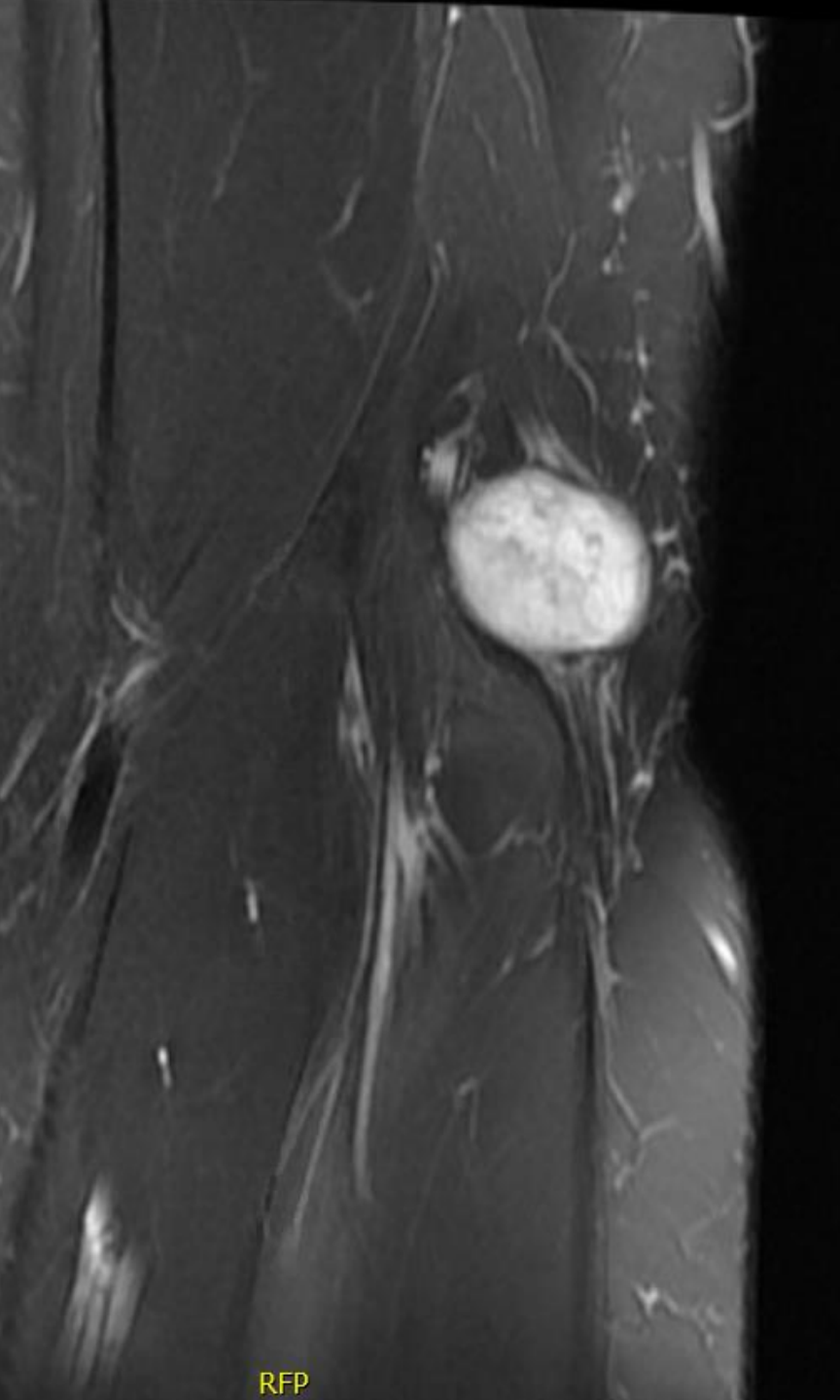
De-diff (high grade) liposarcoma



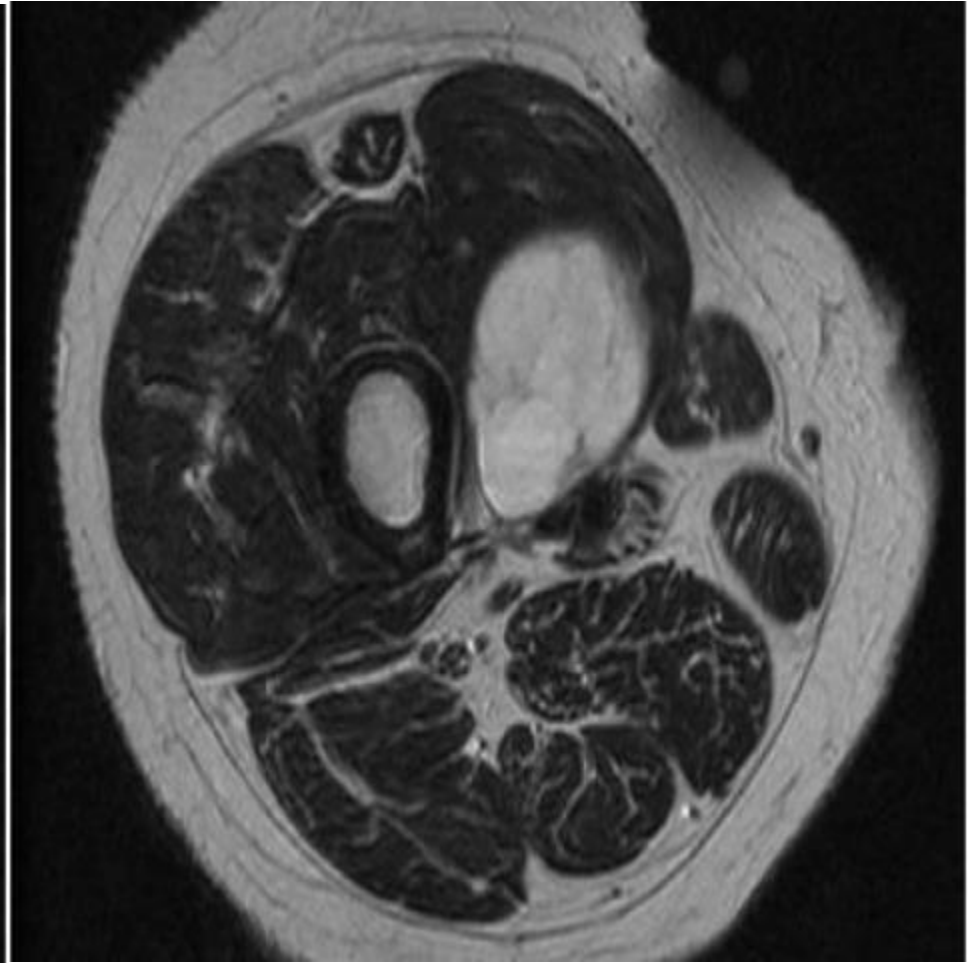
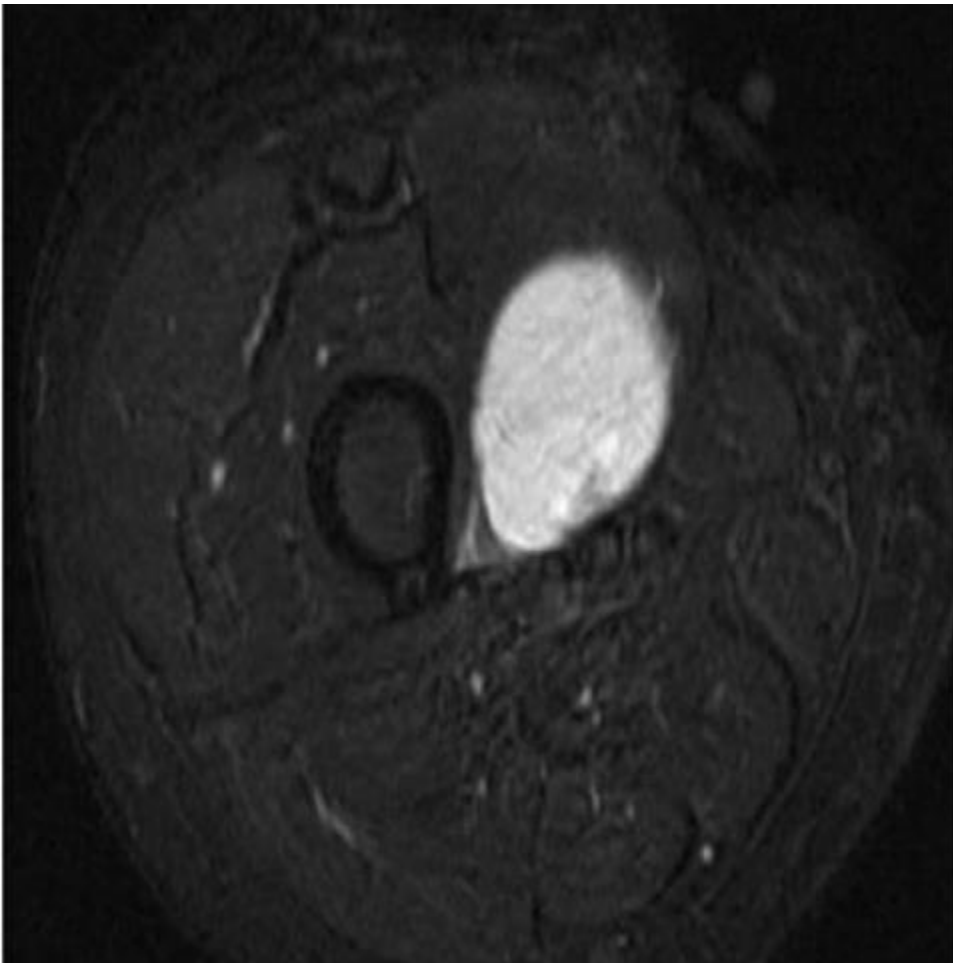


Nerve sheath tumors

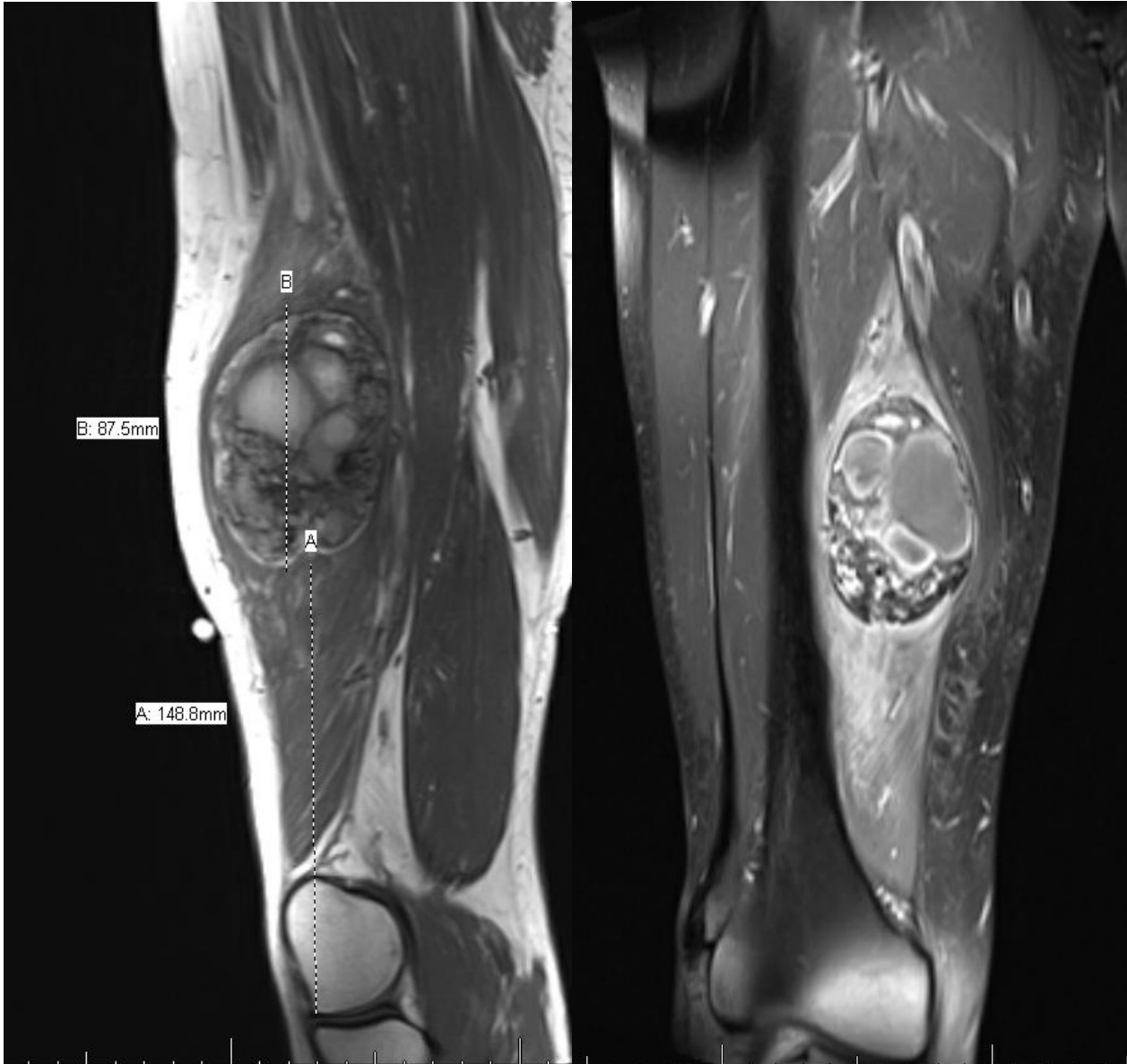


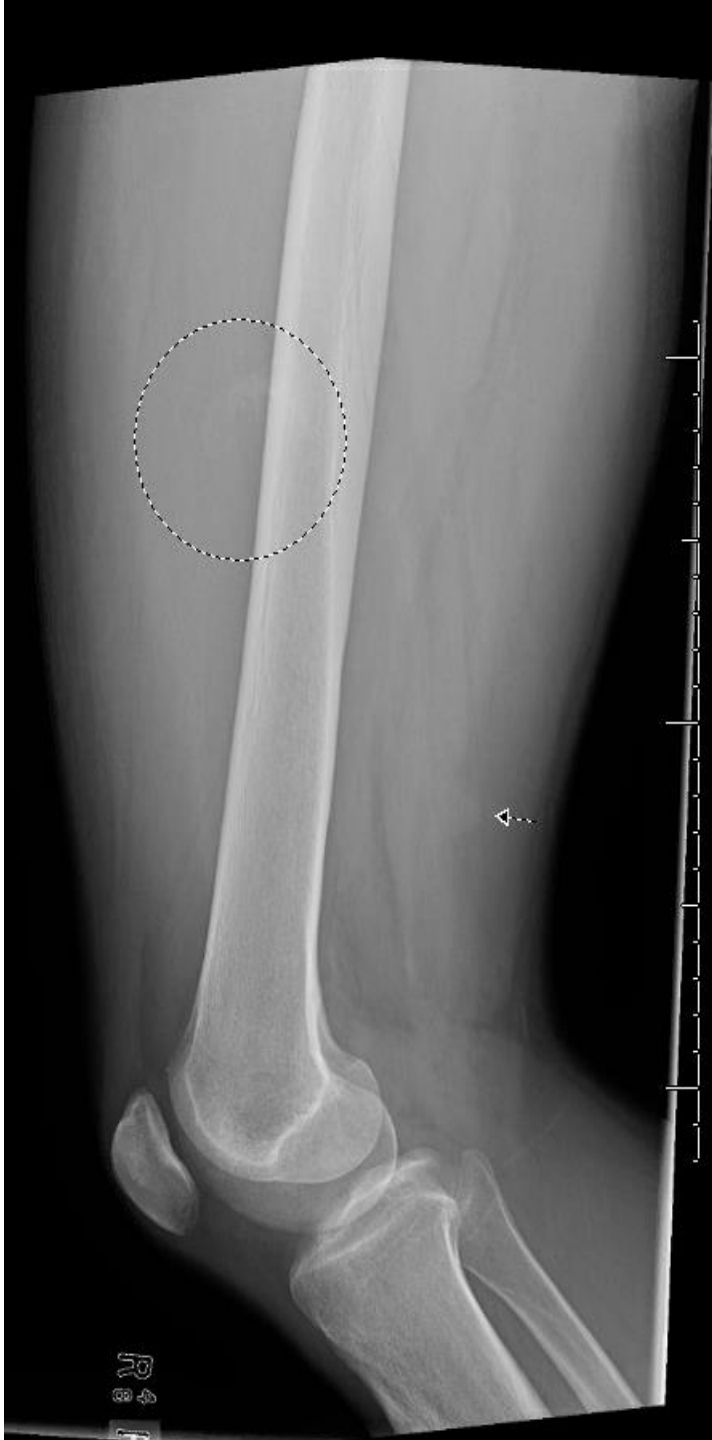

Myxoma

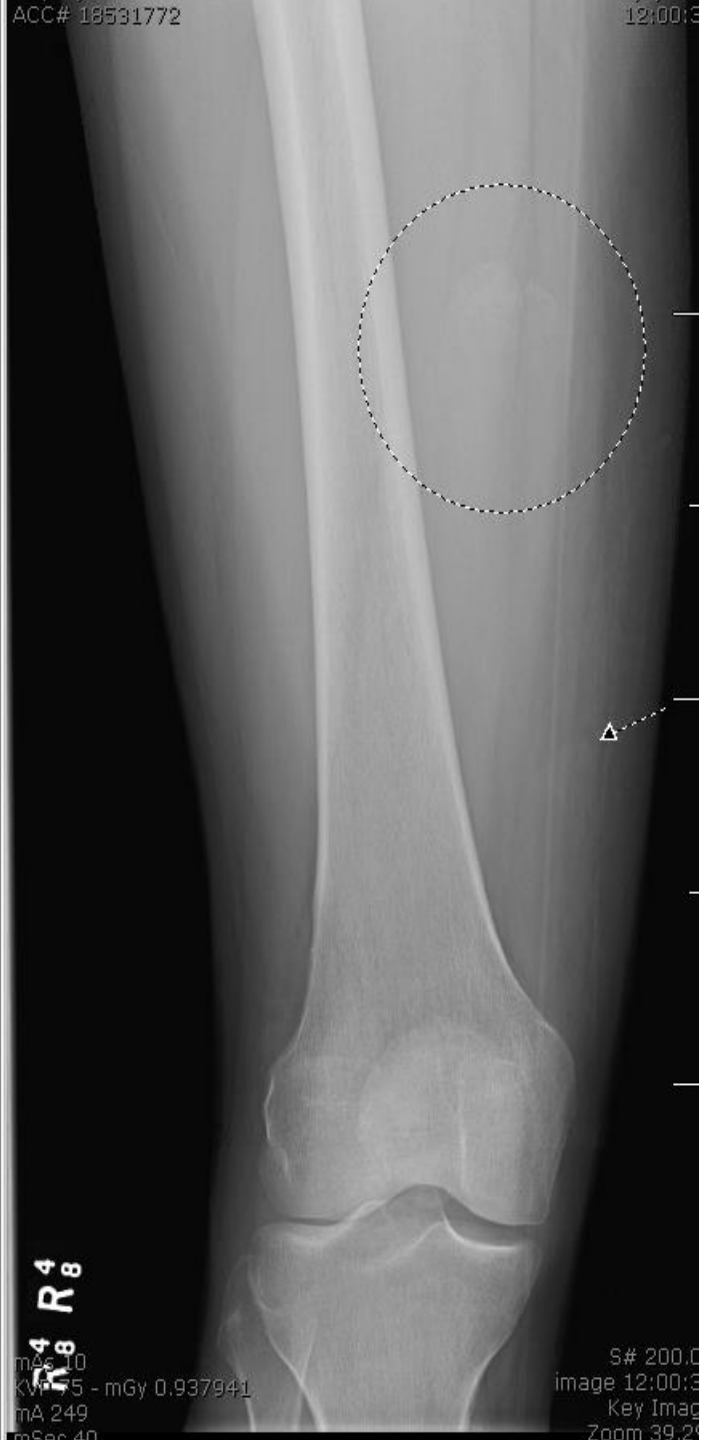


Large thigh mass after injury





R 4



R 4

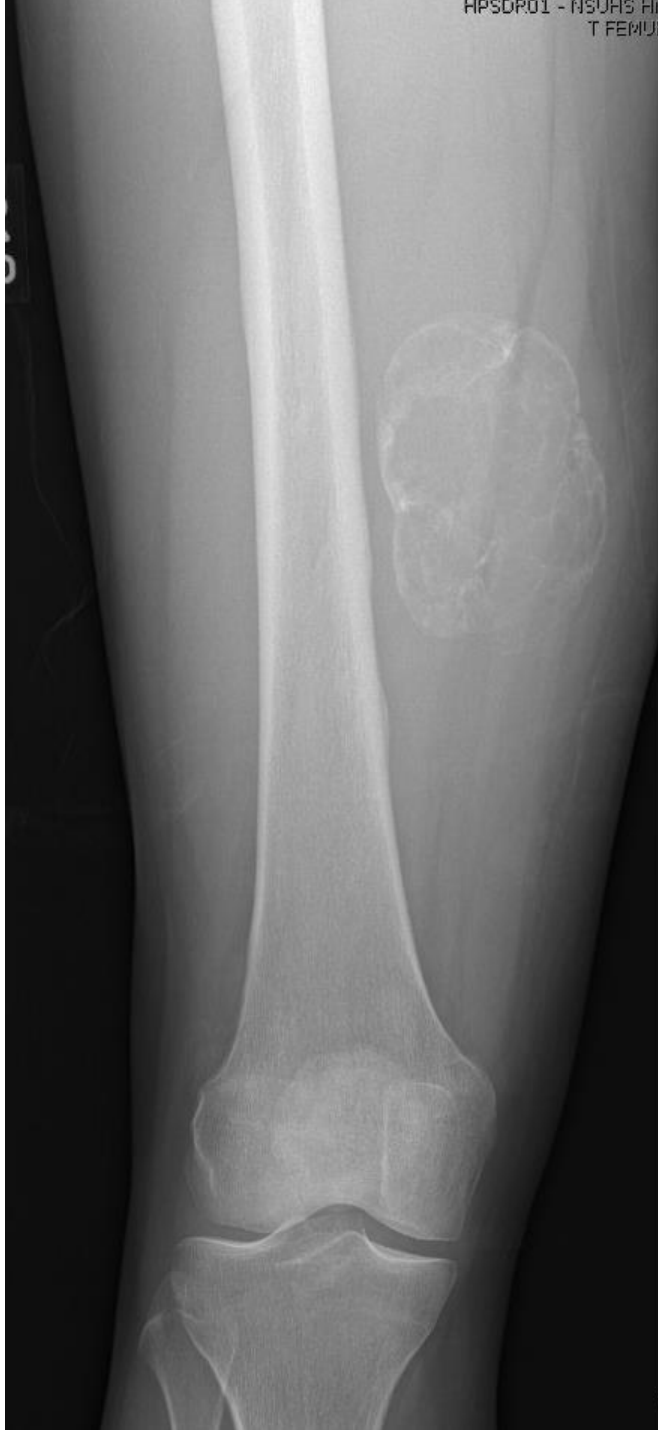mA 249
mSec 40
KVP 75 - mGy 0.937941

S# 200.0
image 12:00:3
Key Imag
Zoom 39.2%

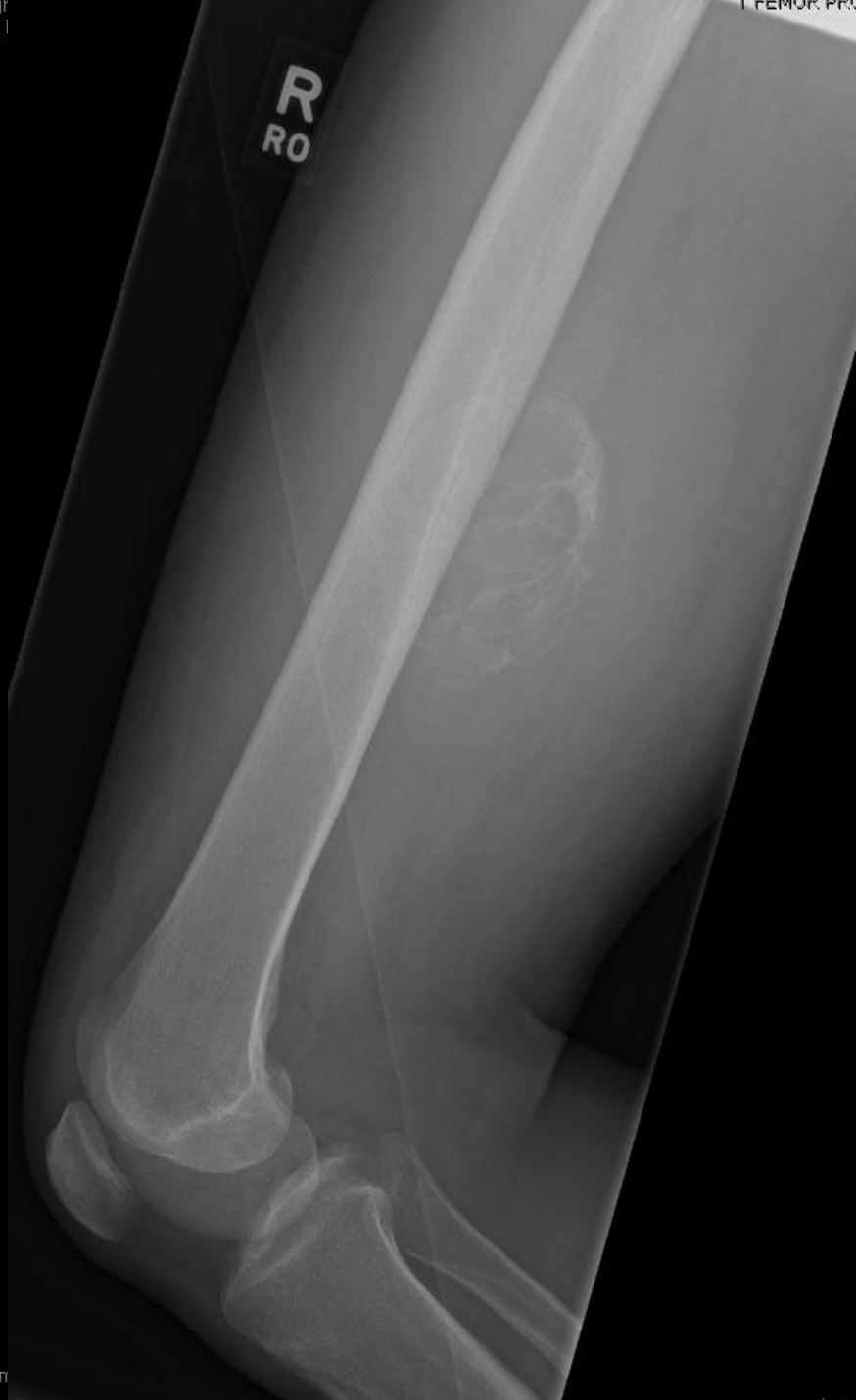ACC# 18531772

12:00:3

HPSDR01 - ASUAS High
T FEMUR I



R
RO

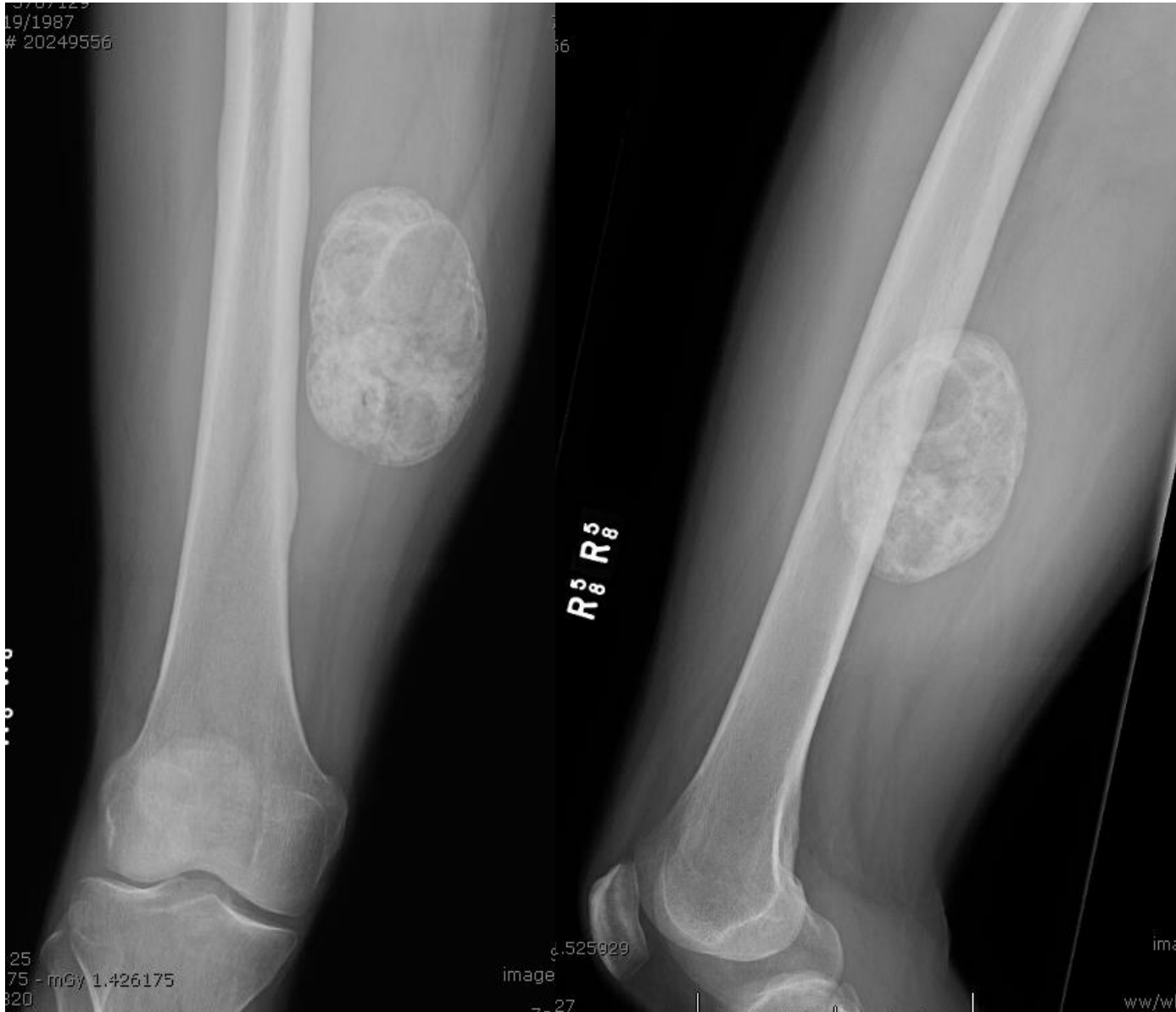

T FEMUR PR

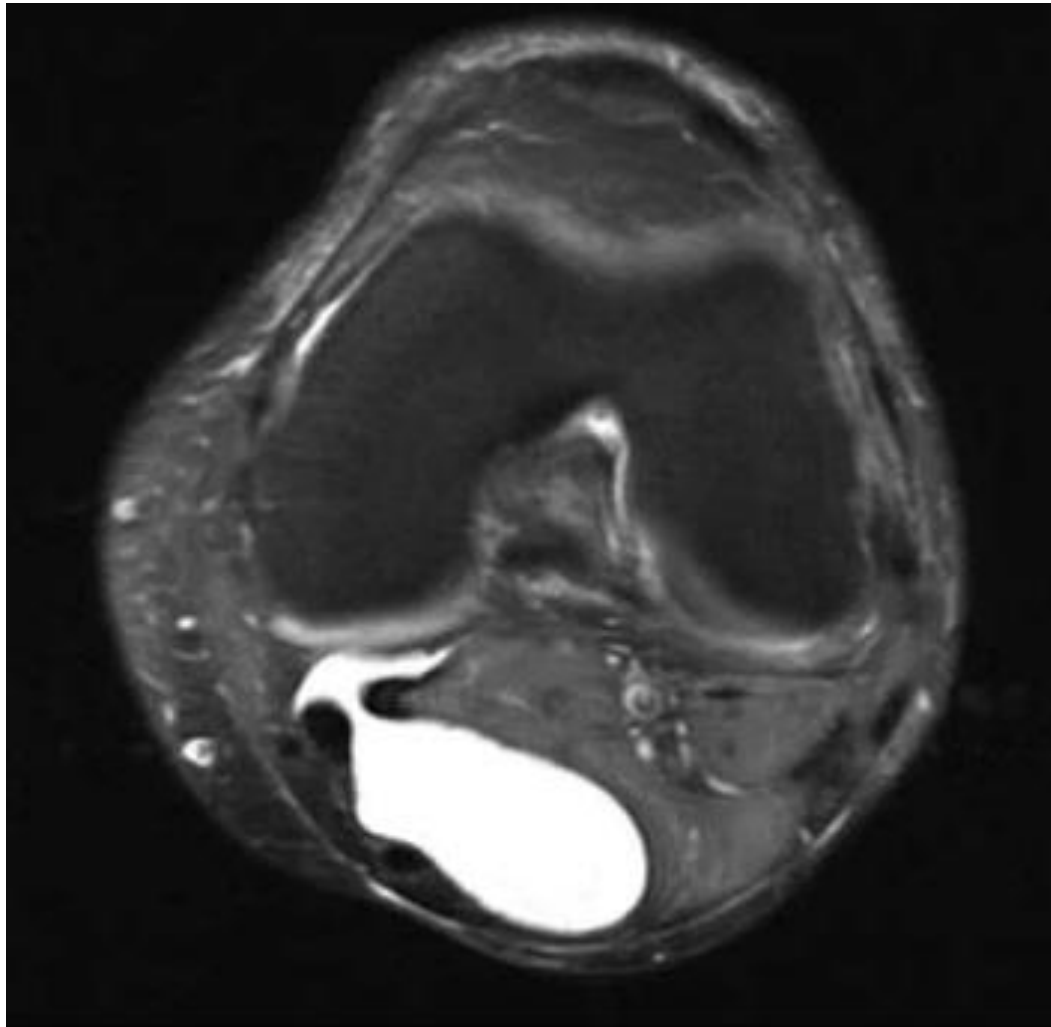
in

ima

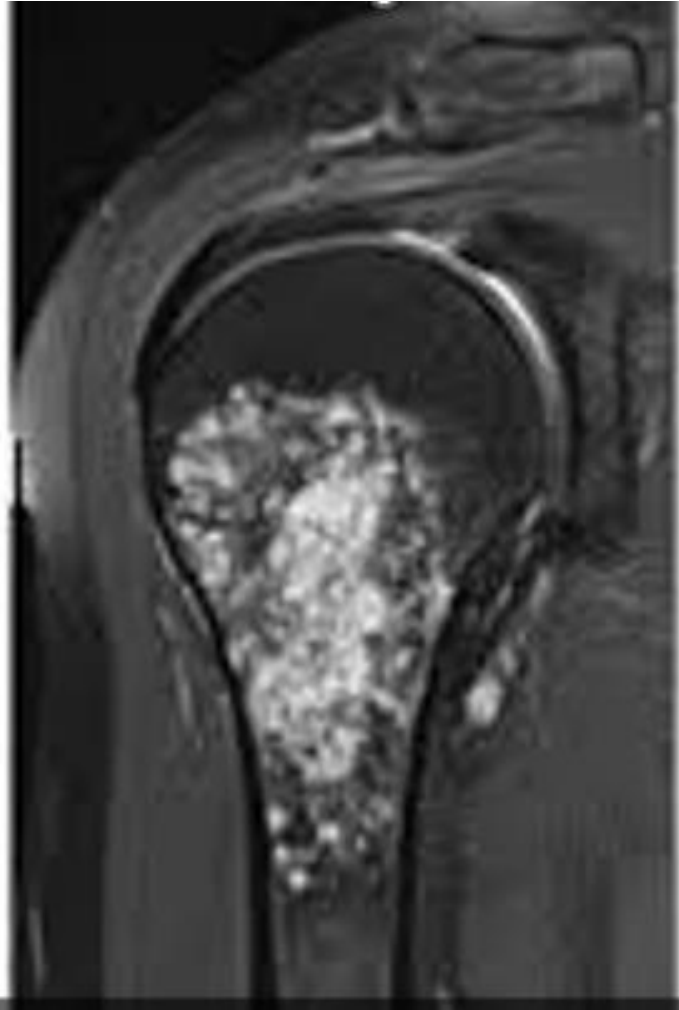
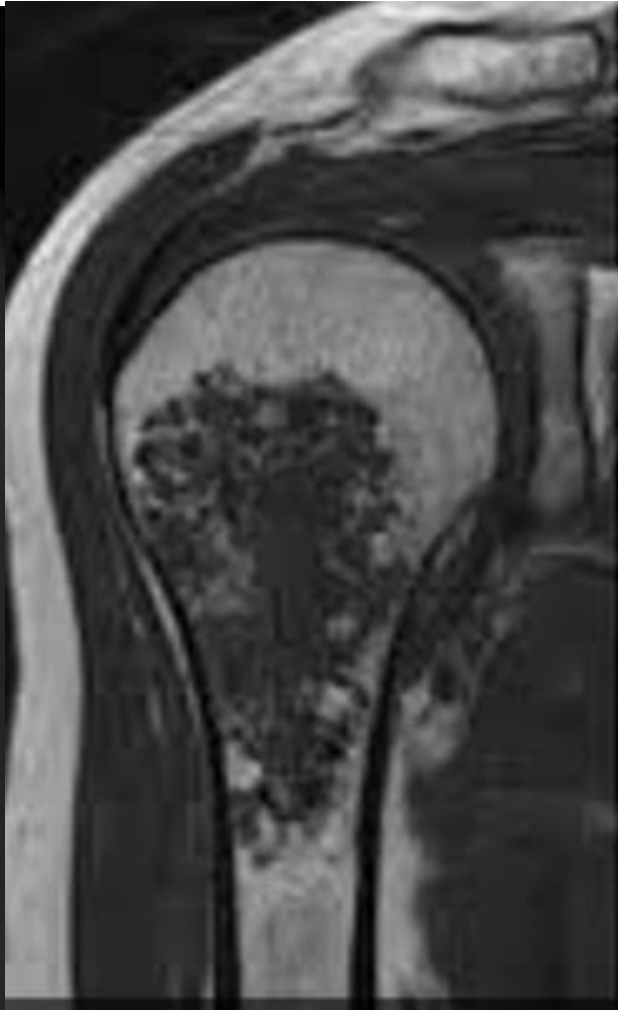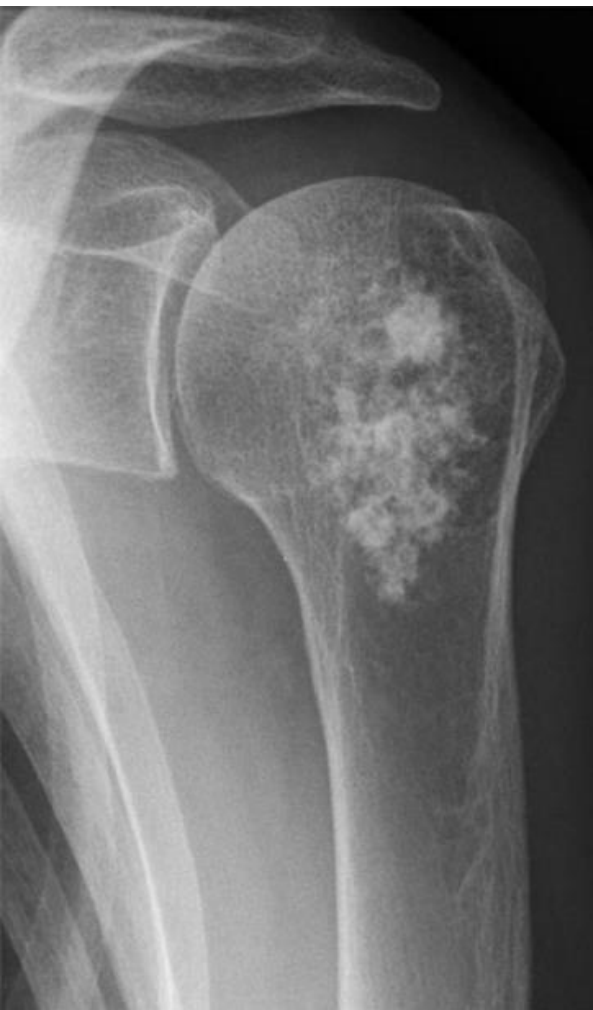Myositis Ossificans



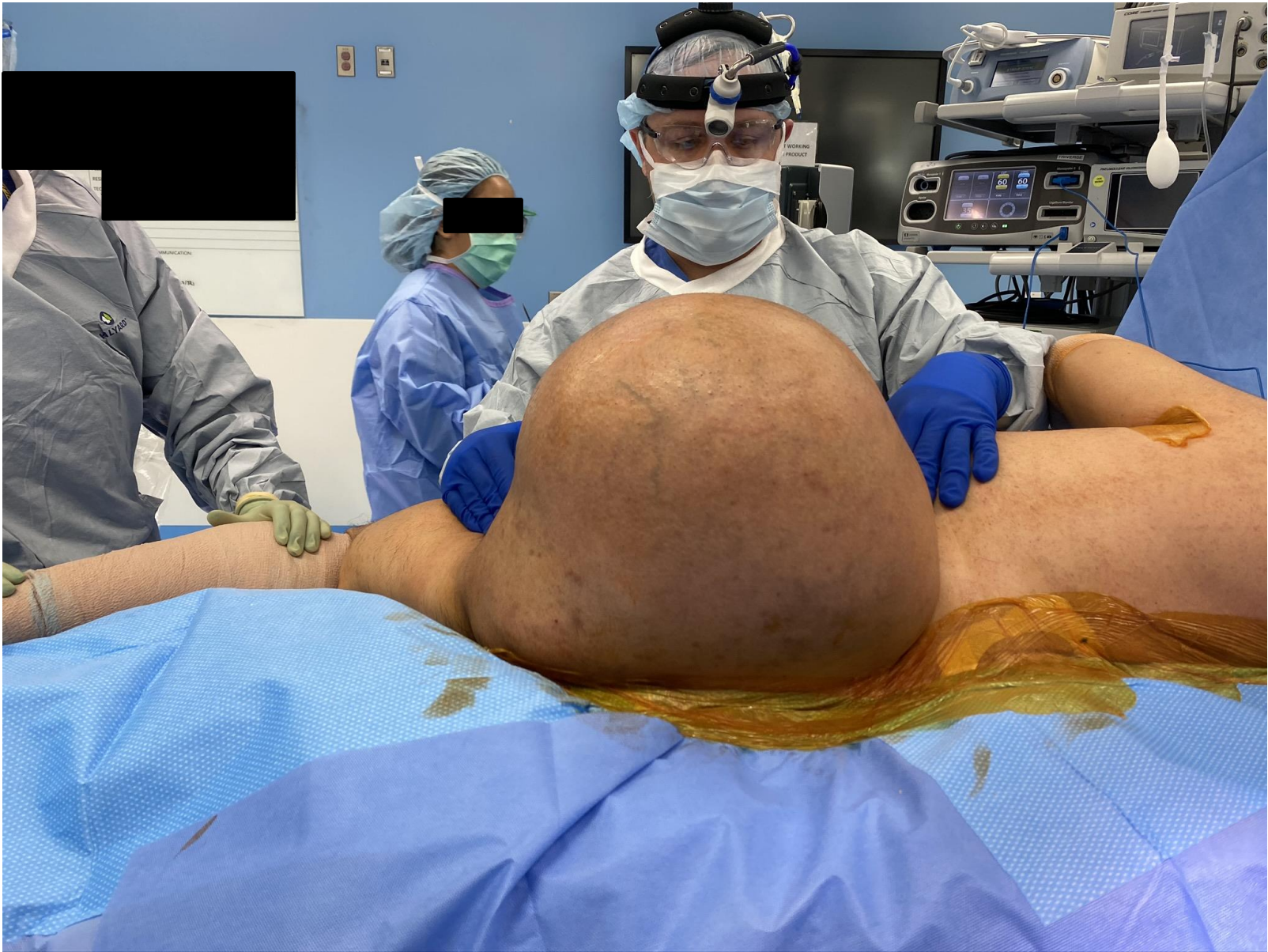Cysts



Enchondroma

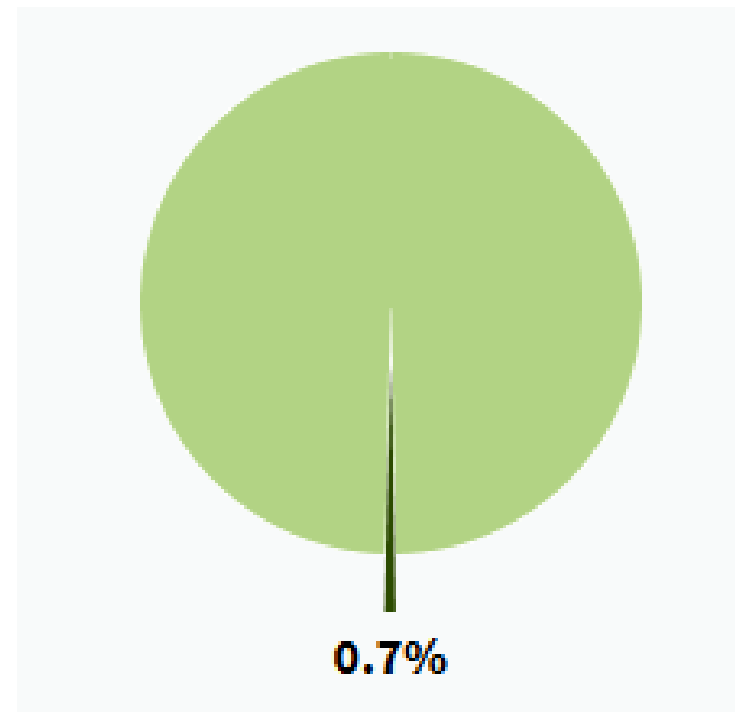
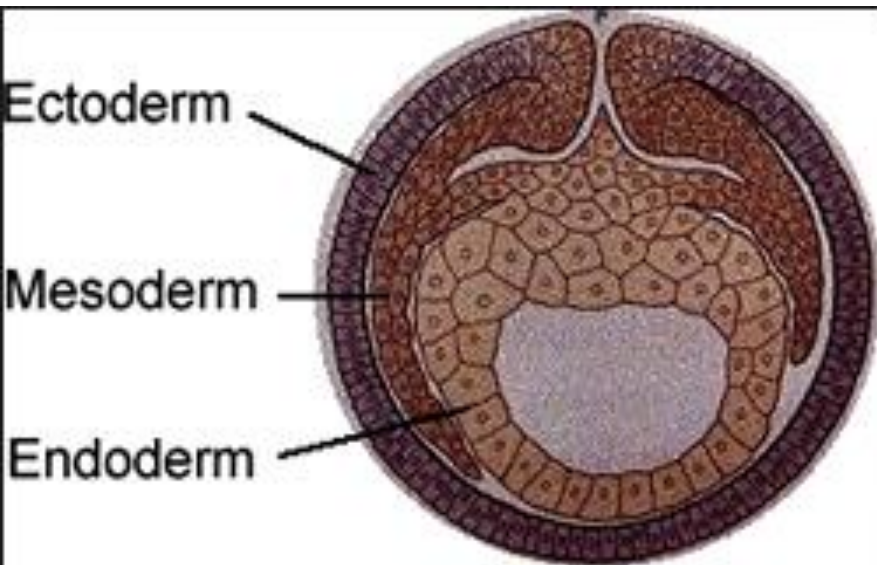


Sarcoma

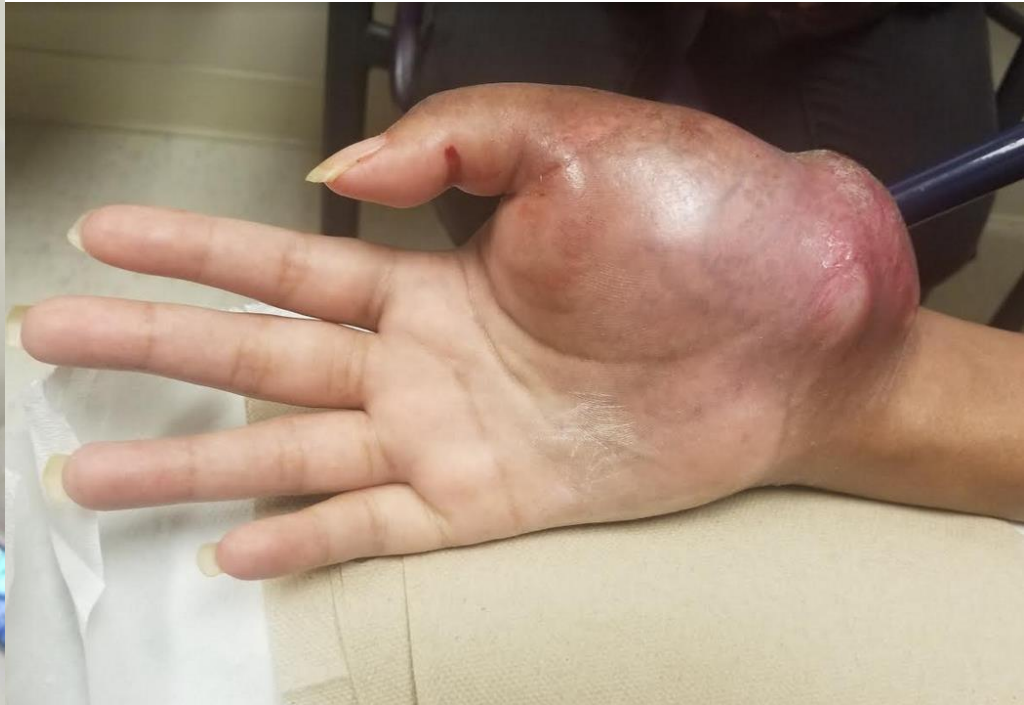
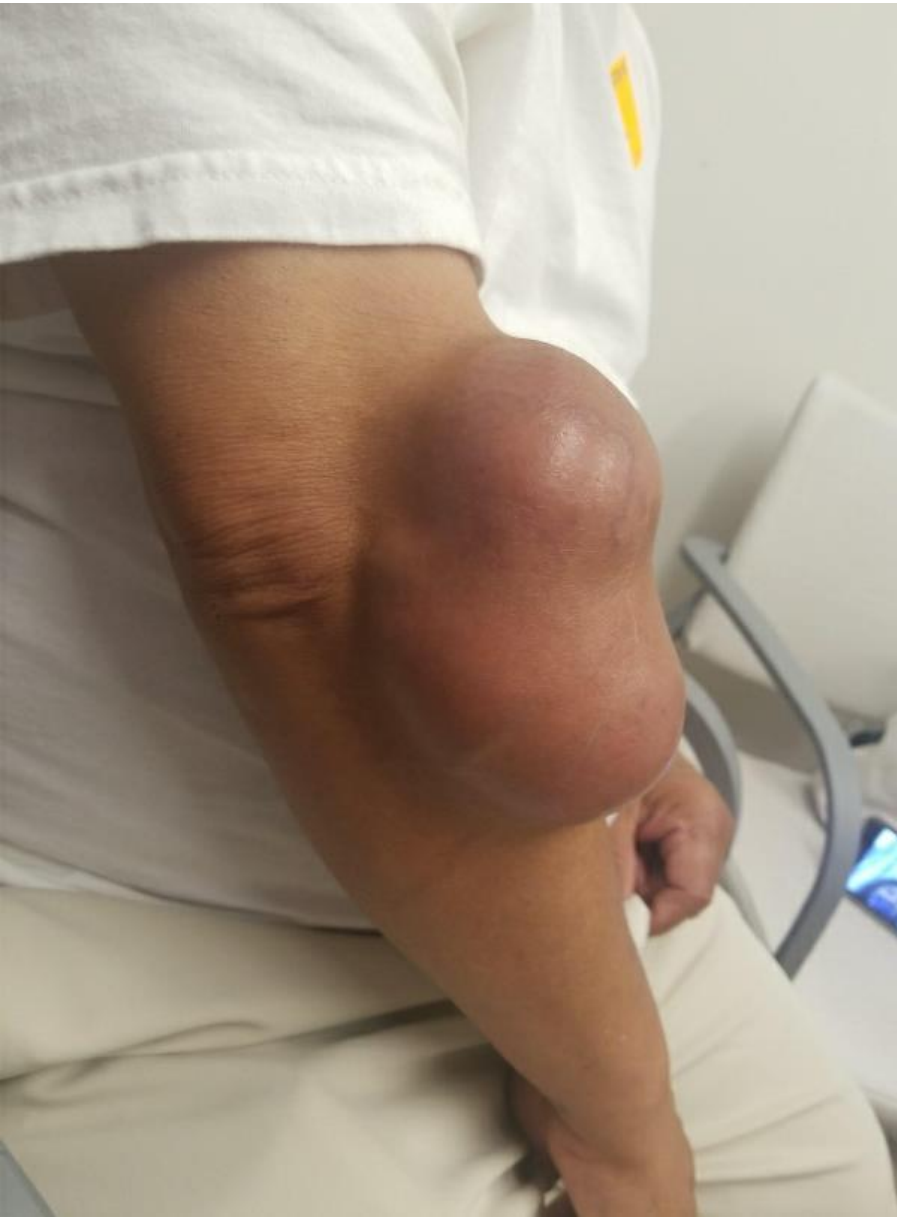
What is Sarcoma?

- Derived from mesoderm (connective tissue)
- ~14,000 cases/year



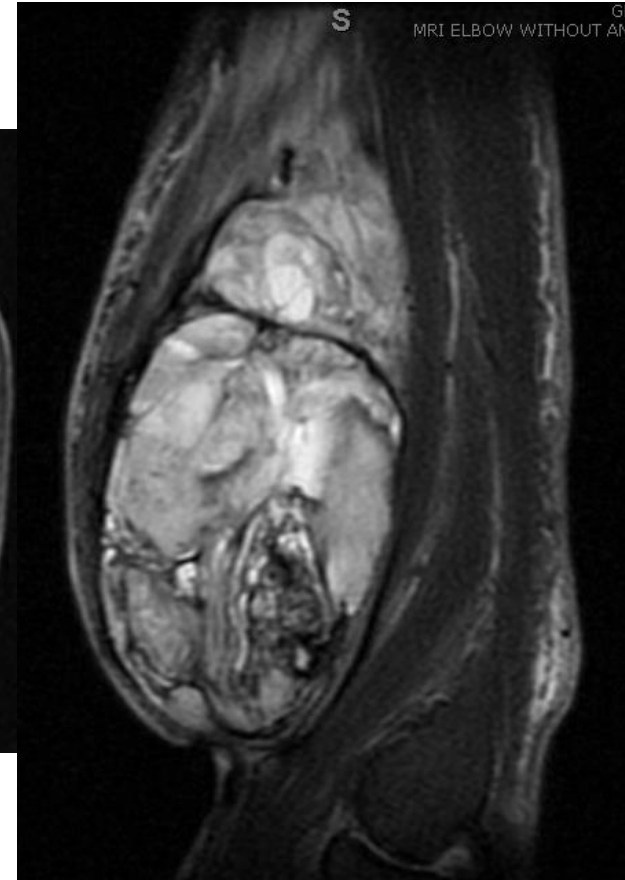
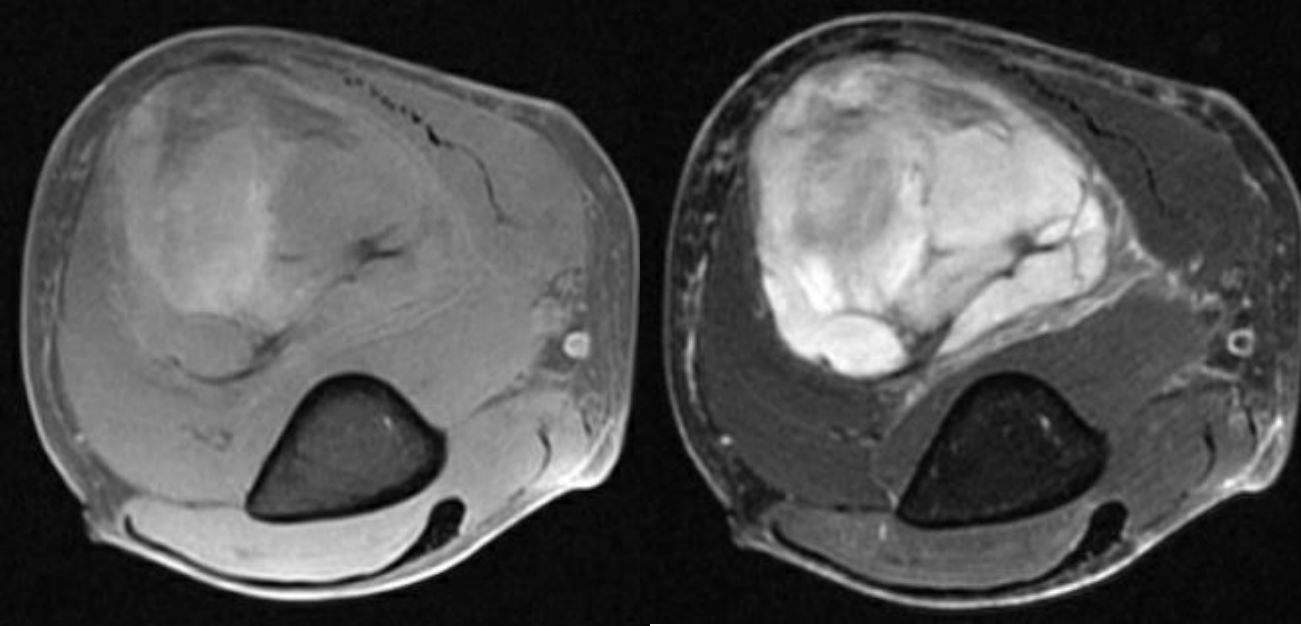
How do we find sarcoma?



How do we find sarcoma?


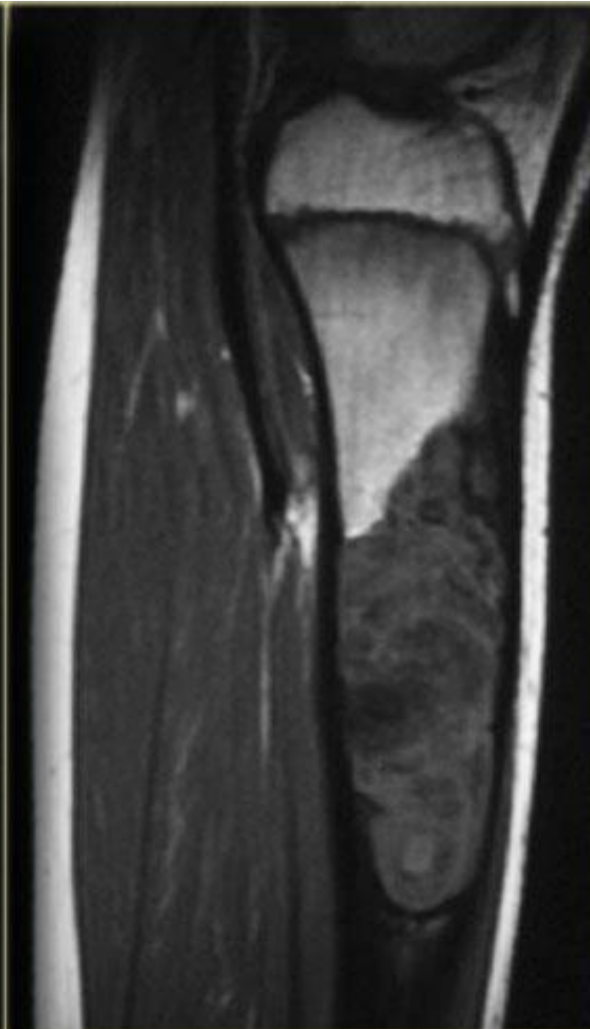
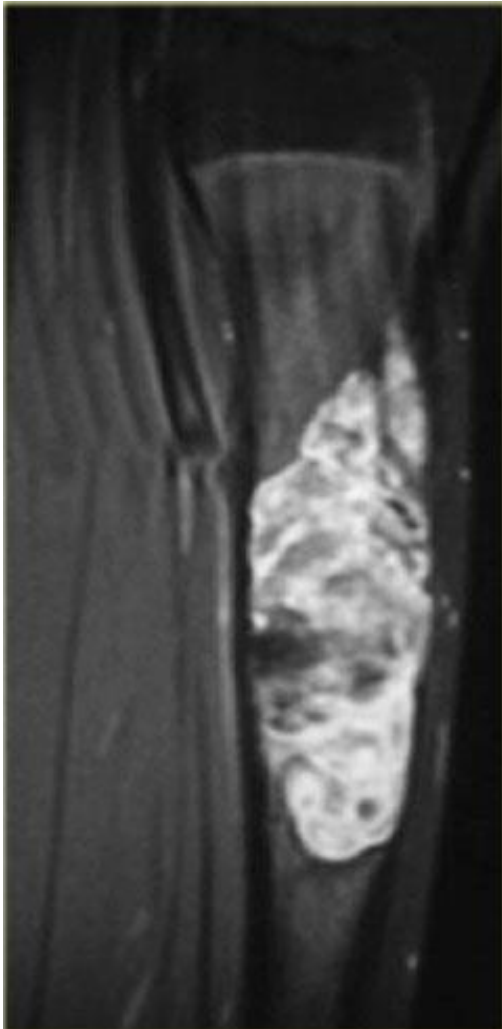
- Soft Tissue Sarcoma
 - Painless enlarging mass
 - 50% history of “trauma”
- Bone Sarcoma
 - Pain with ambulation
 - Night pain
 - “Injury or sprain” doesn’t get better
 - Pathologic fracture

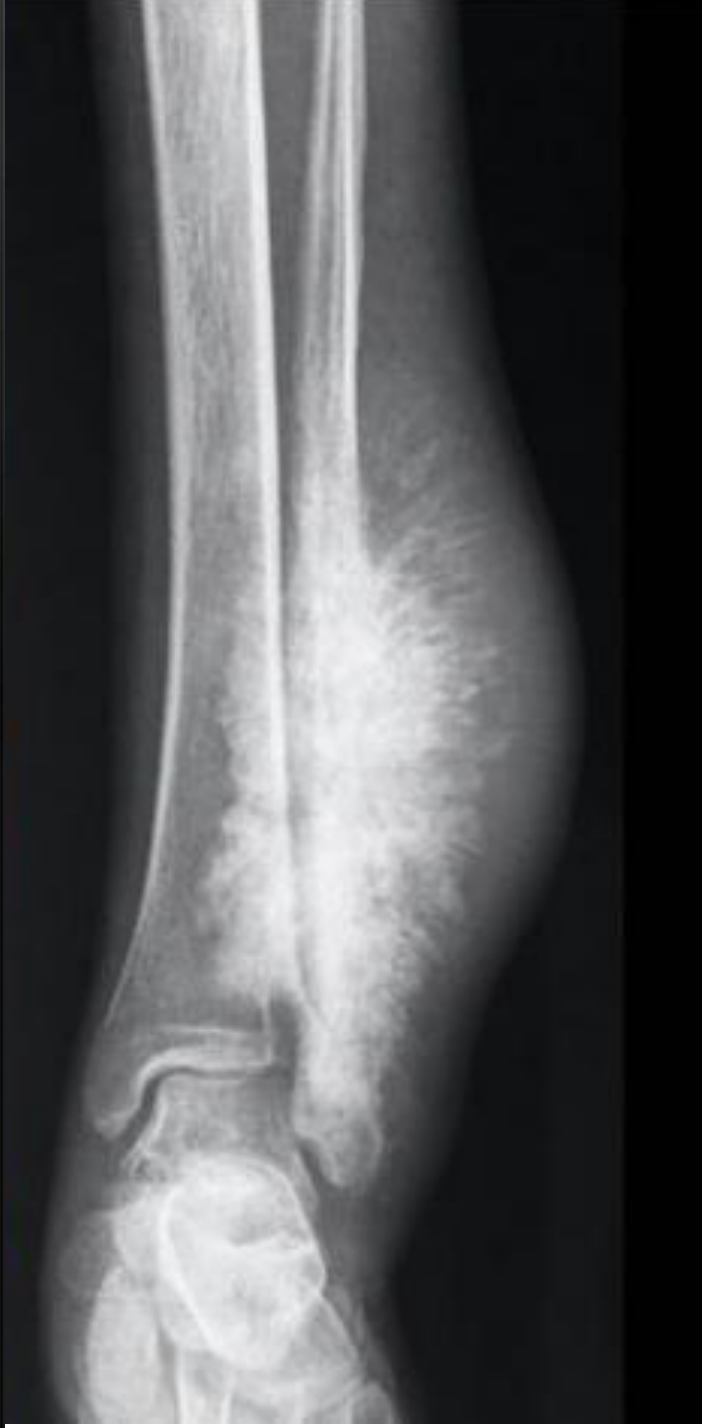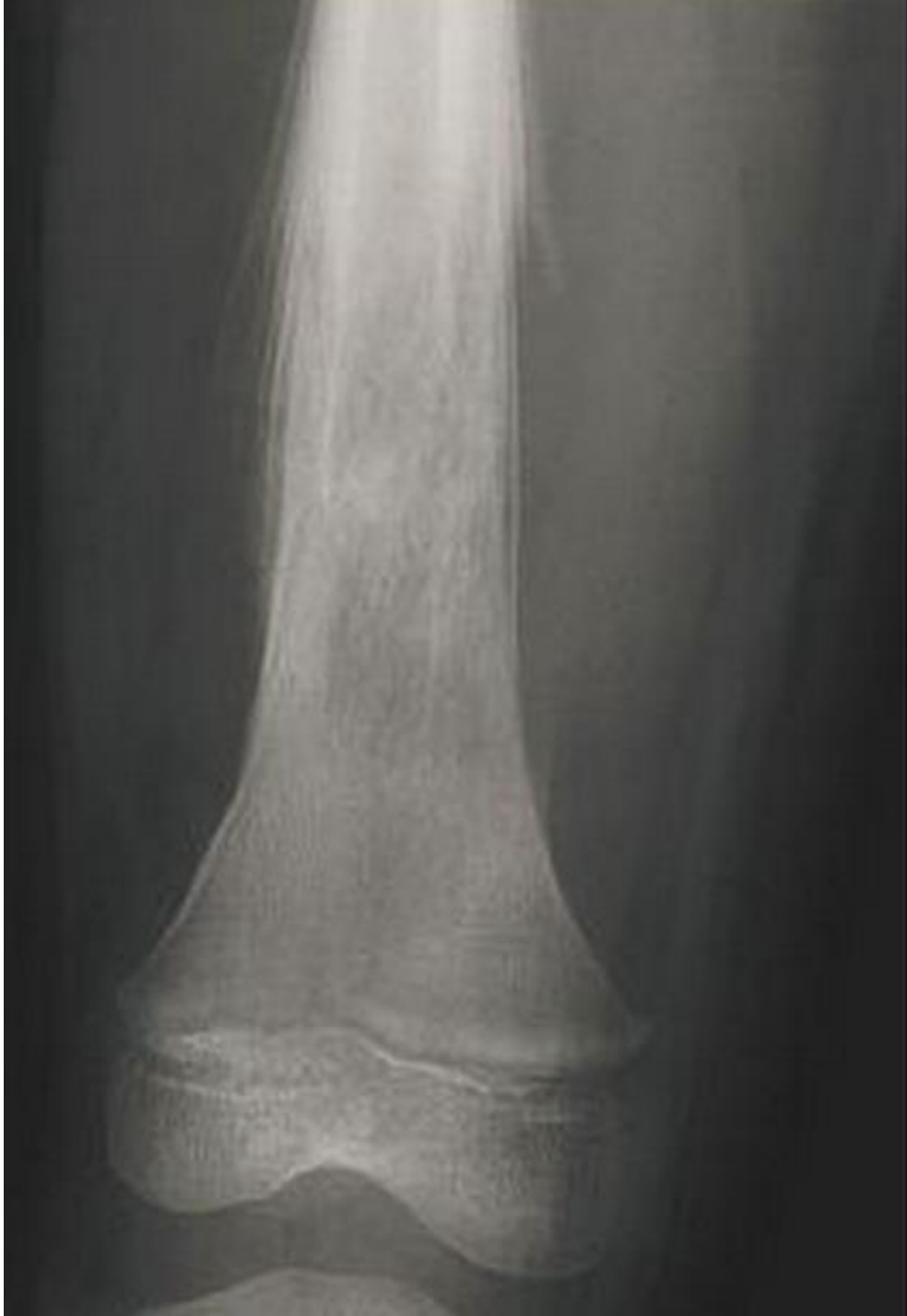Dark T1, Bright T2, Enhances



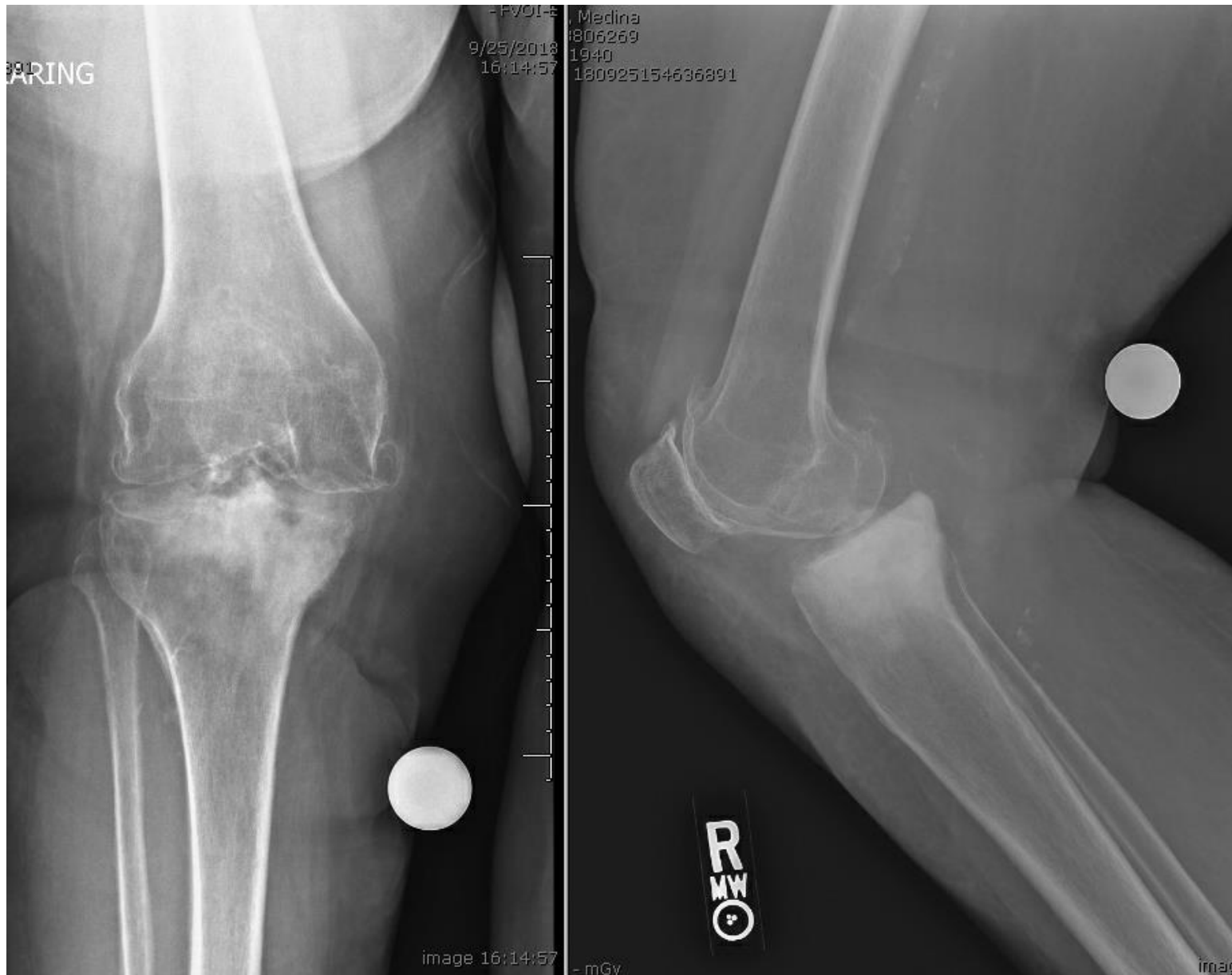
Xrays

- **Gold standard** for bone lesions





Rare- need high clinical suspicion



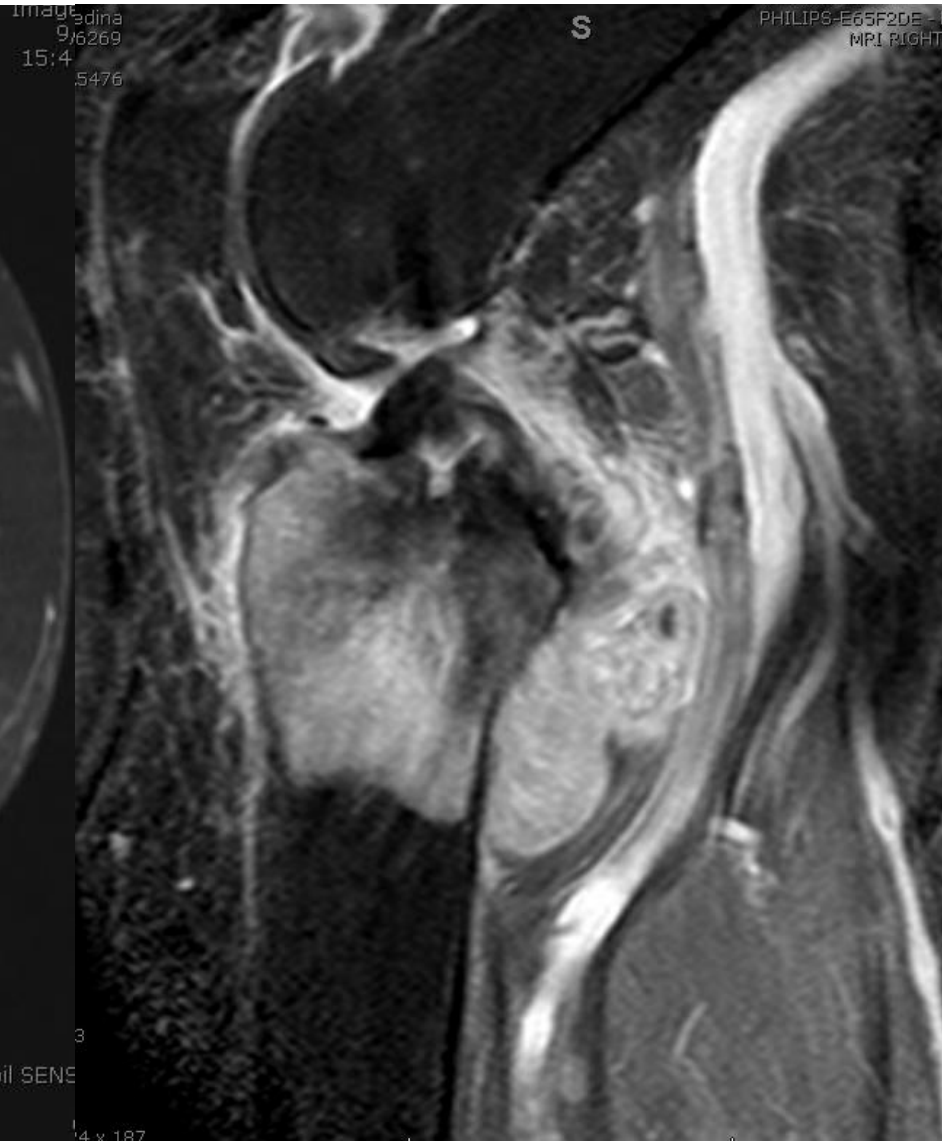
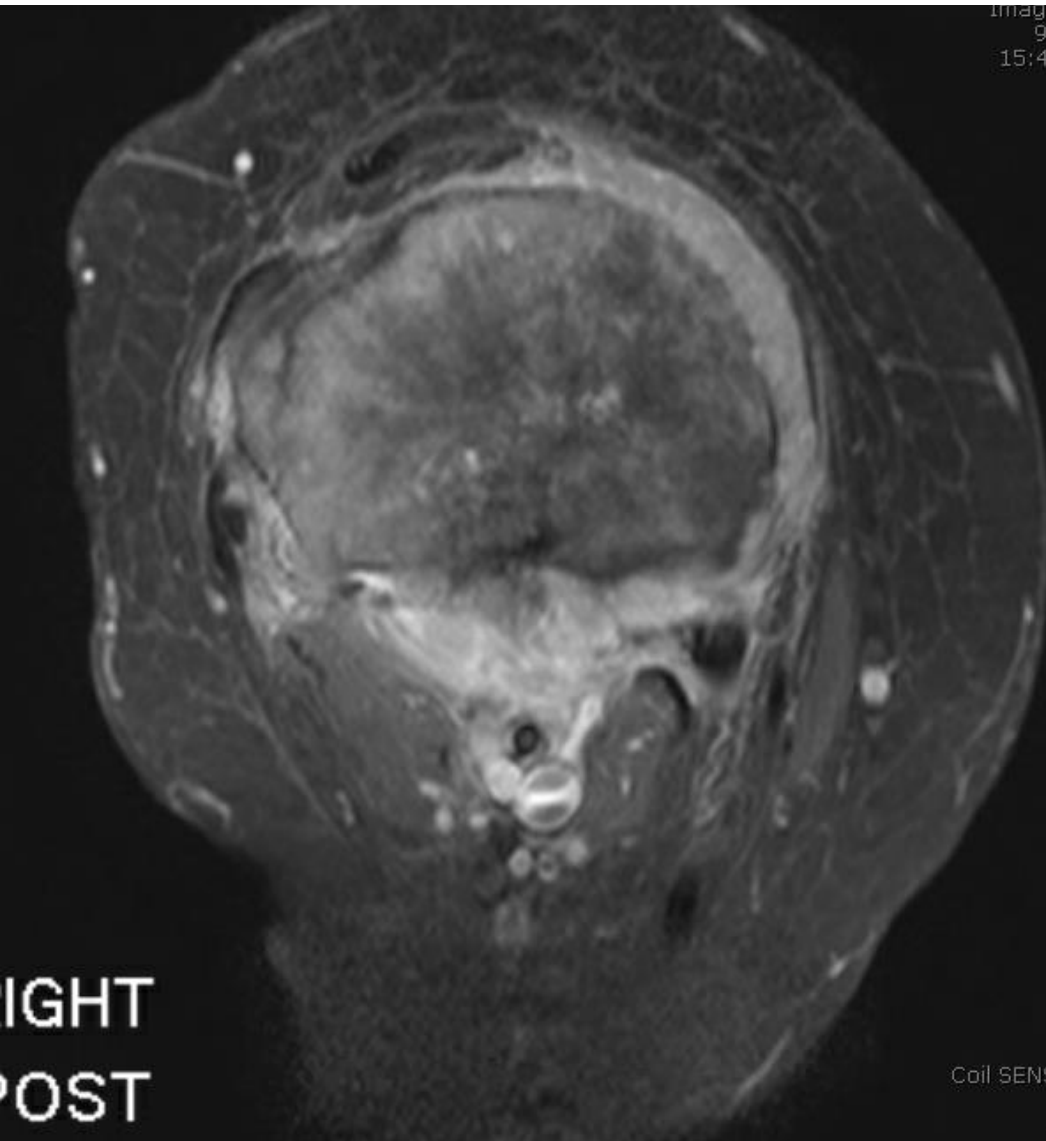
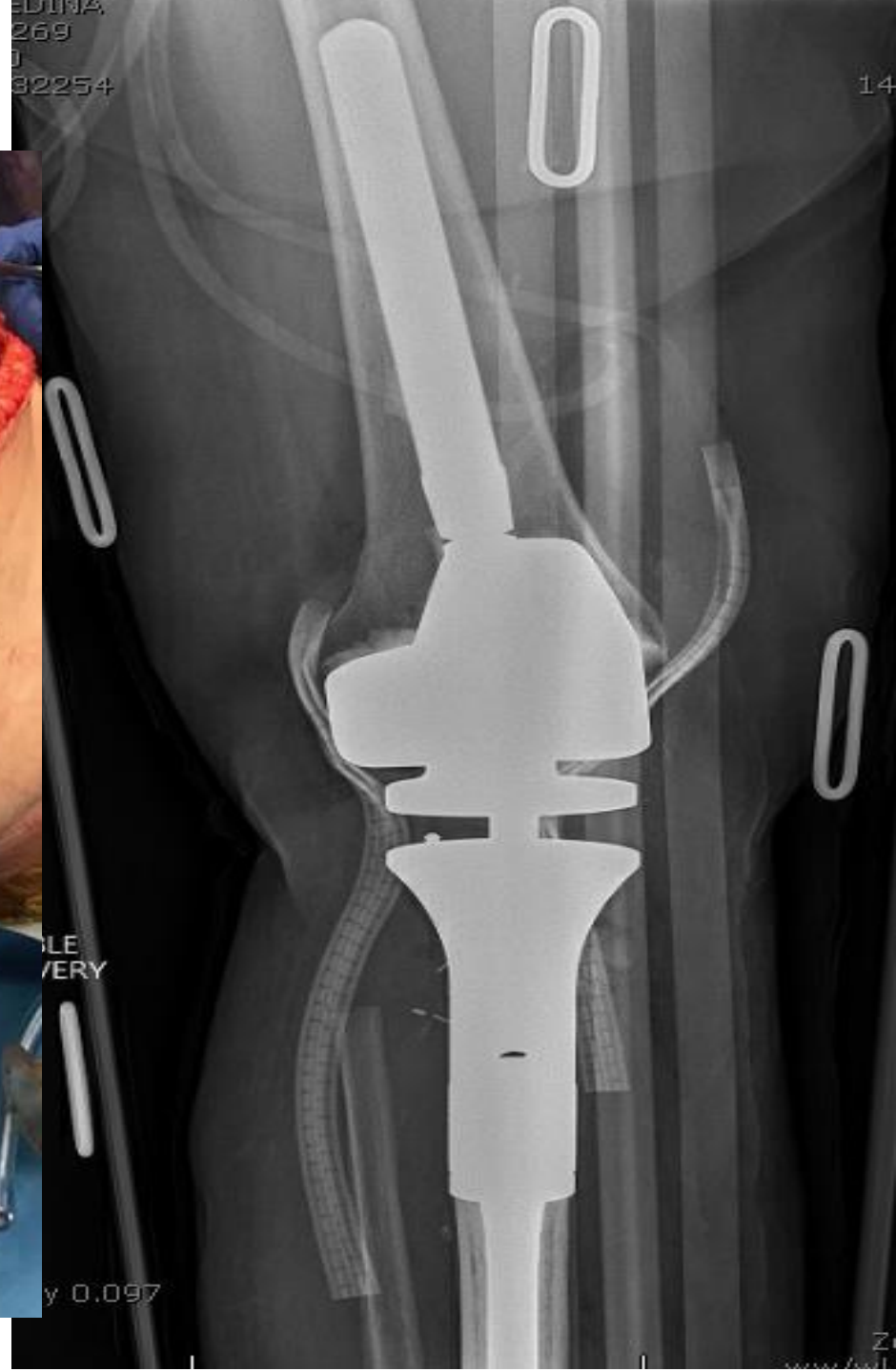
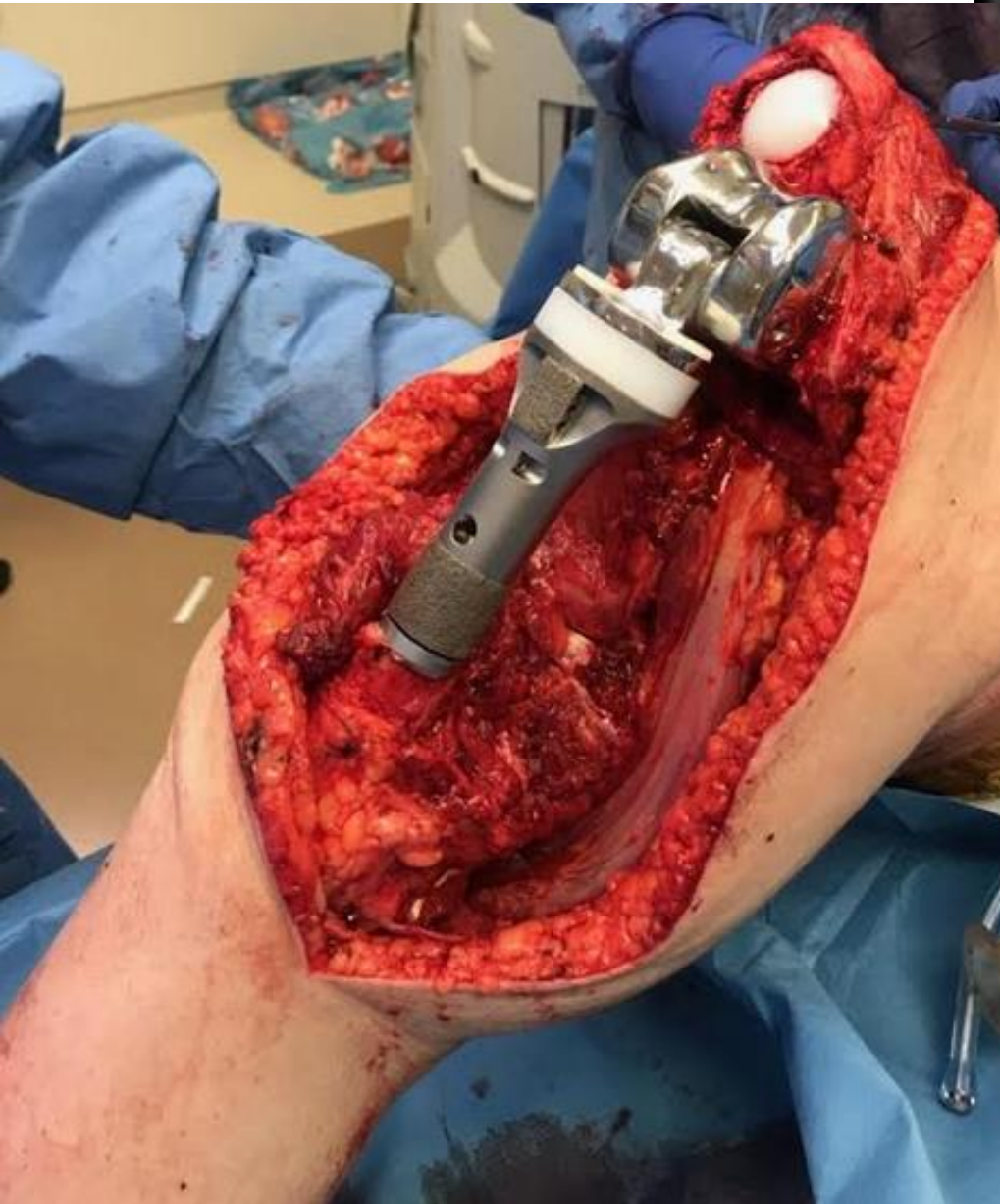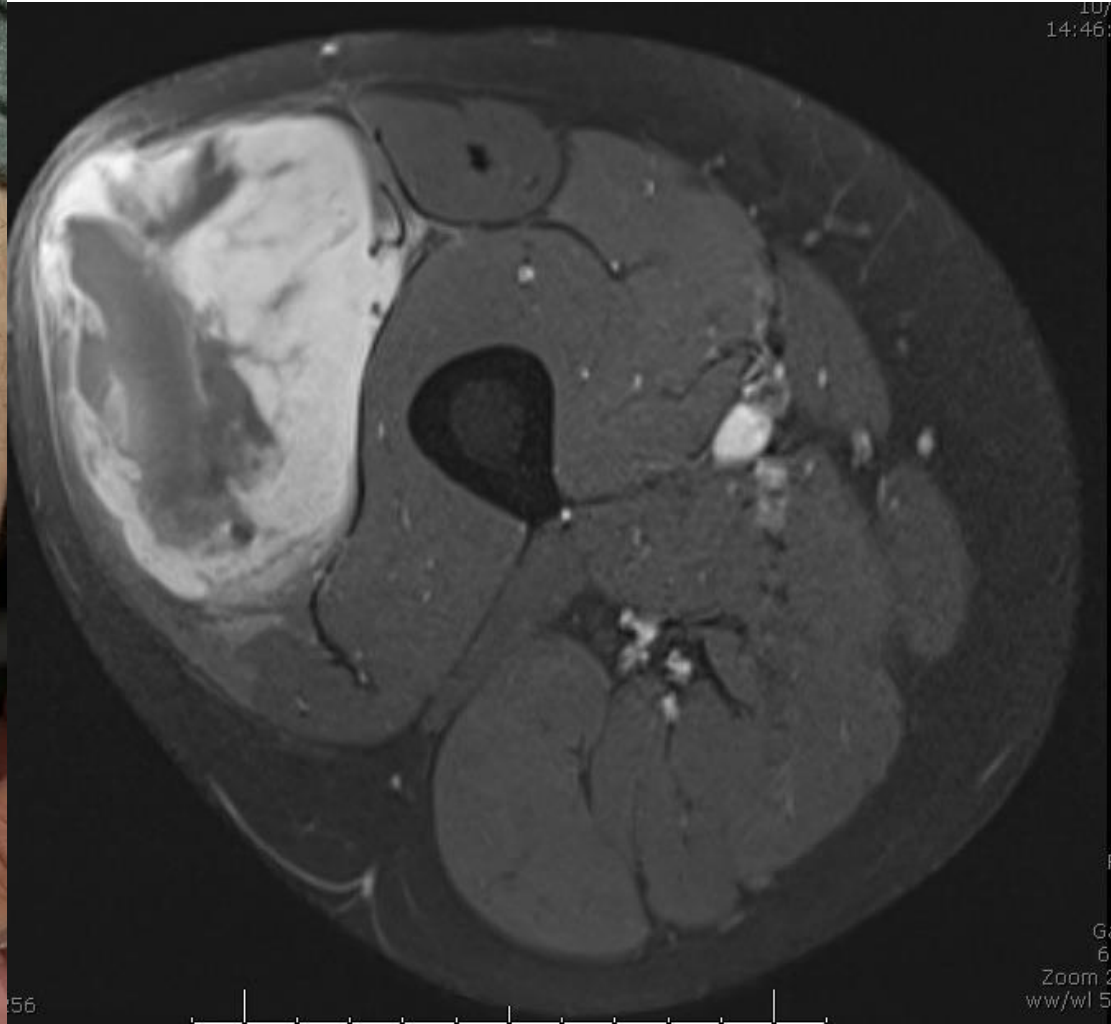

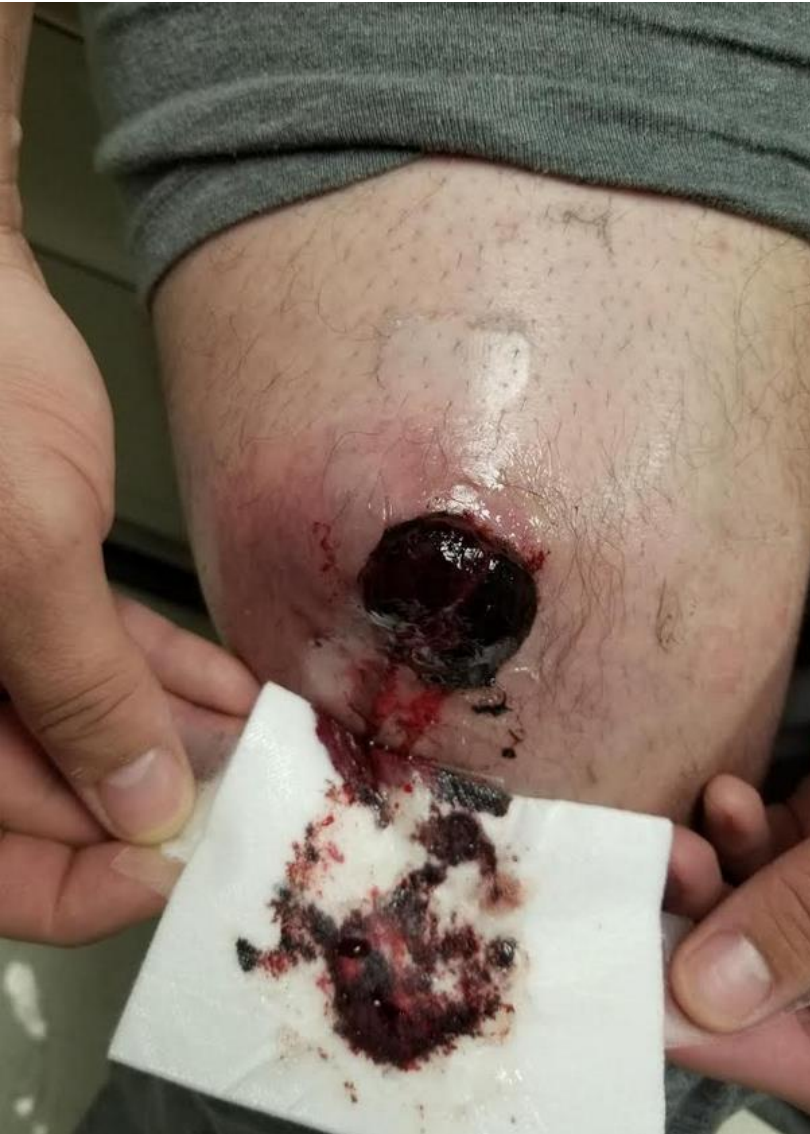
Image
Padina
9/6/2009
15:4
5476



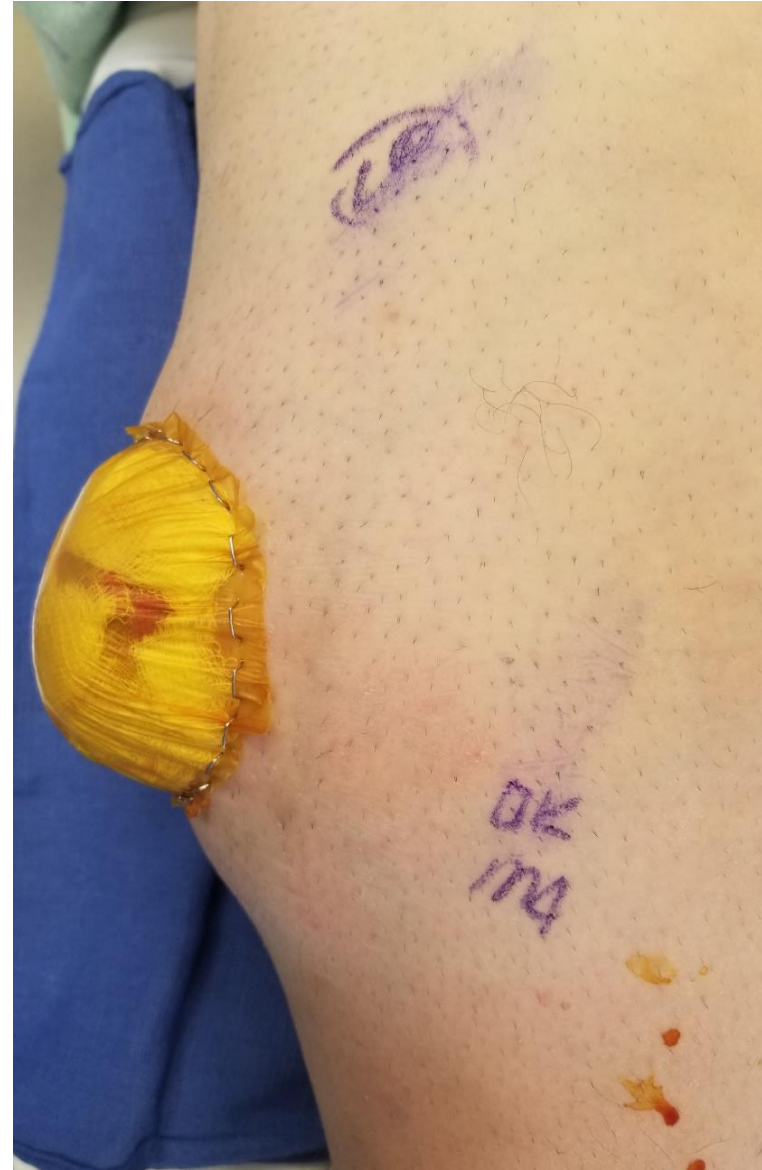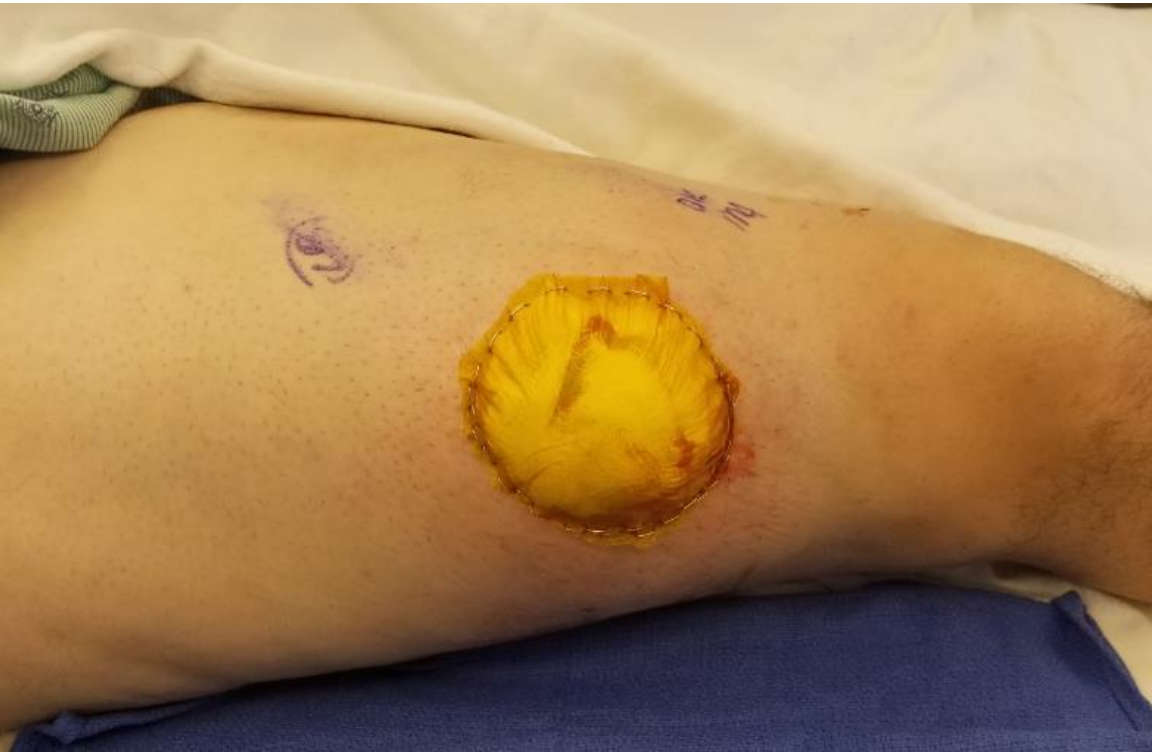32M. "Hematoma" → "Abscess"

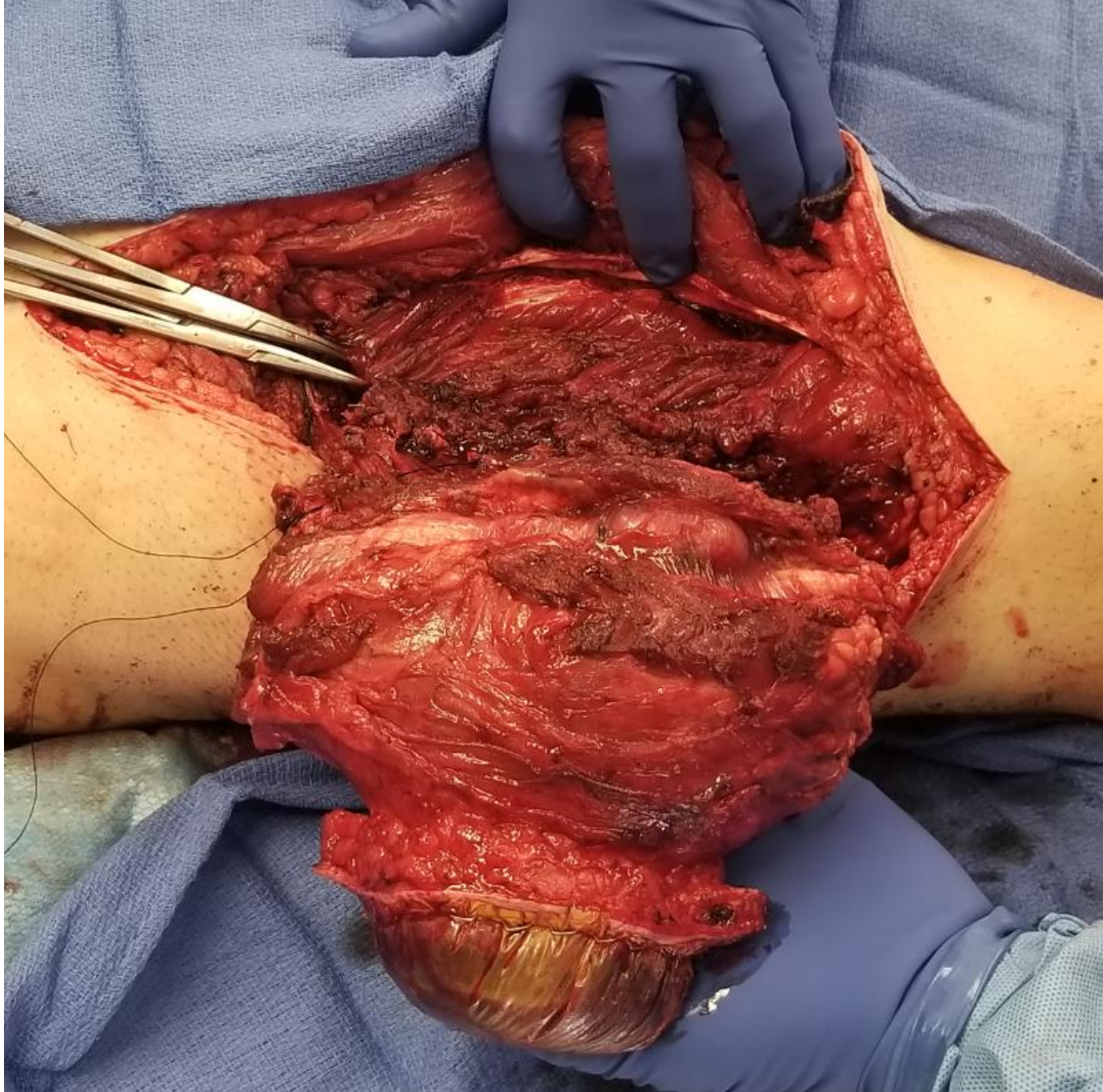


107
14:46

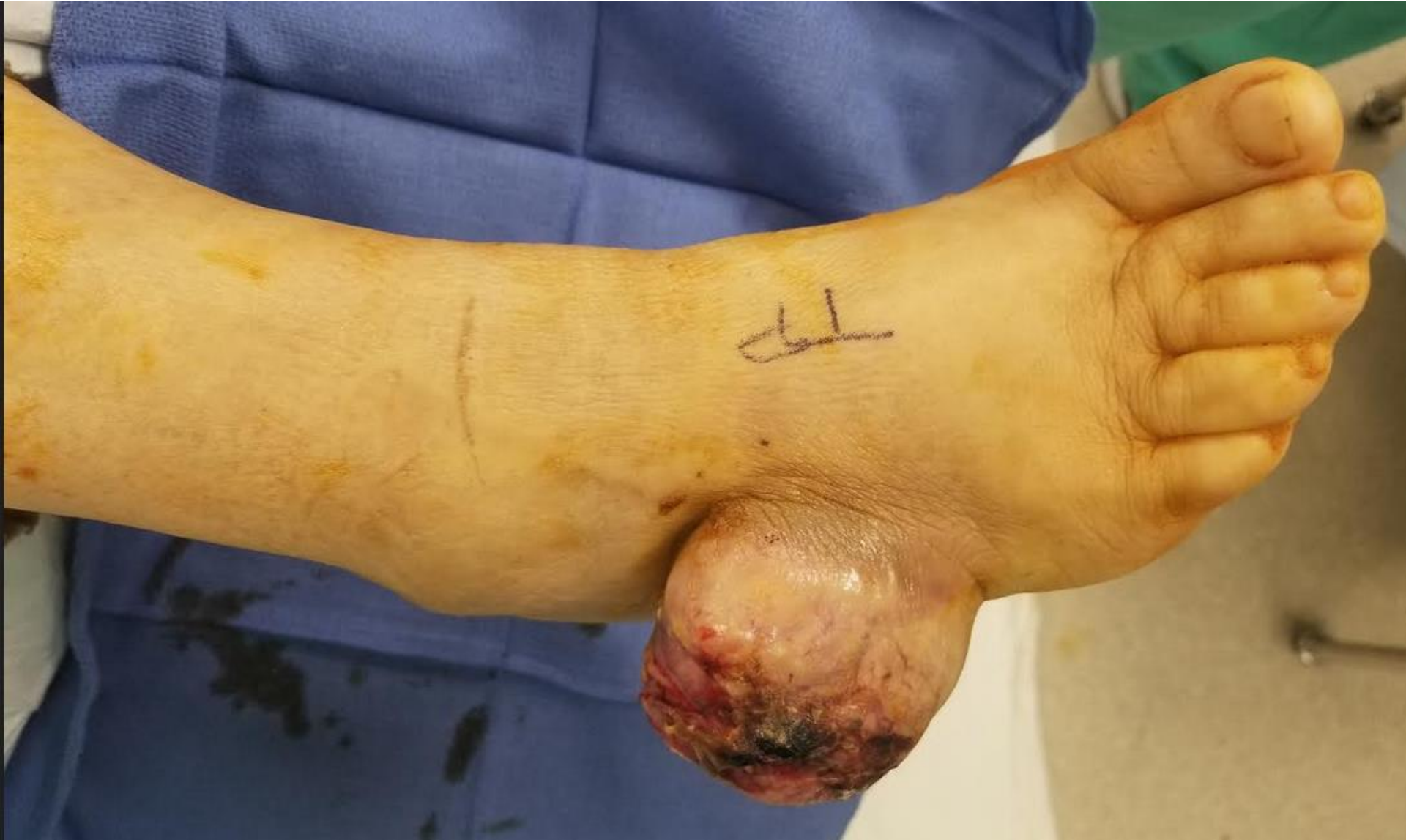G
6
Zoom 2
ww/wl 5

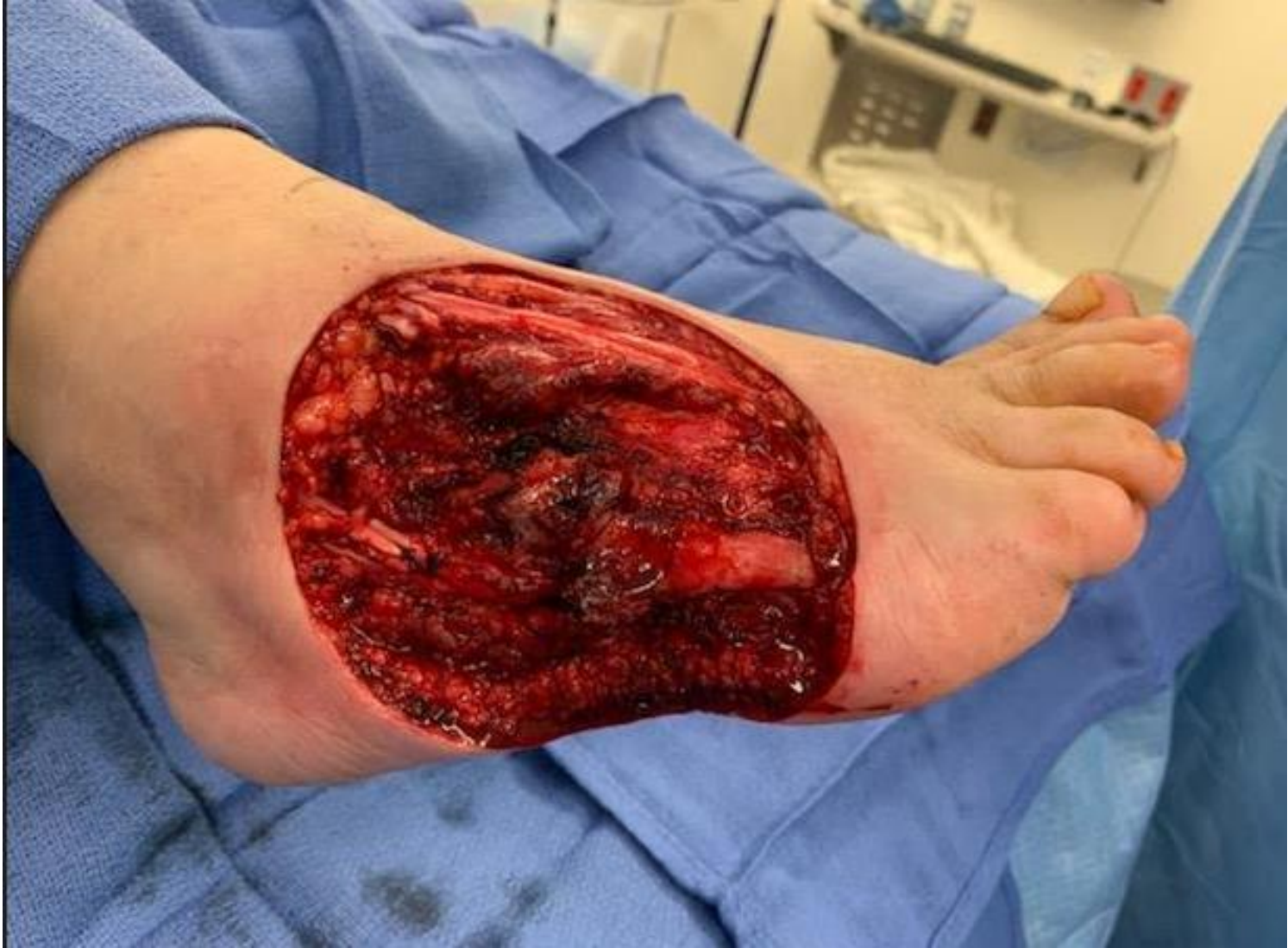56

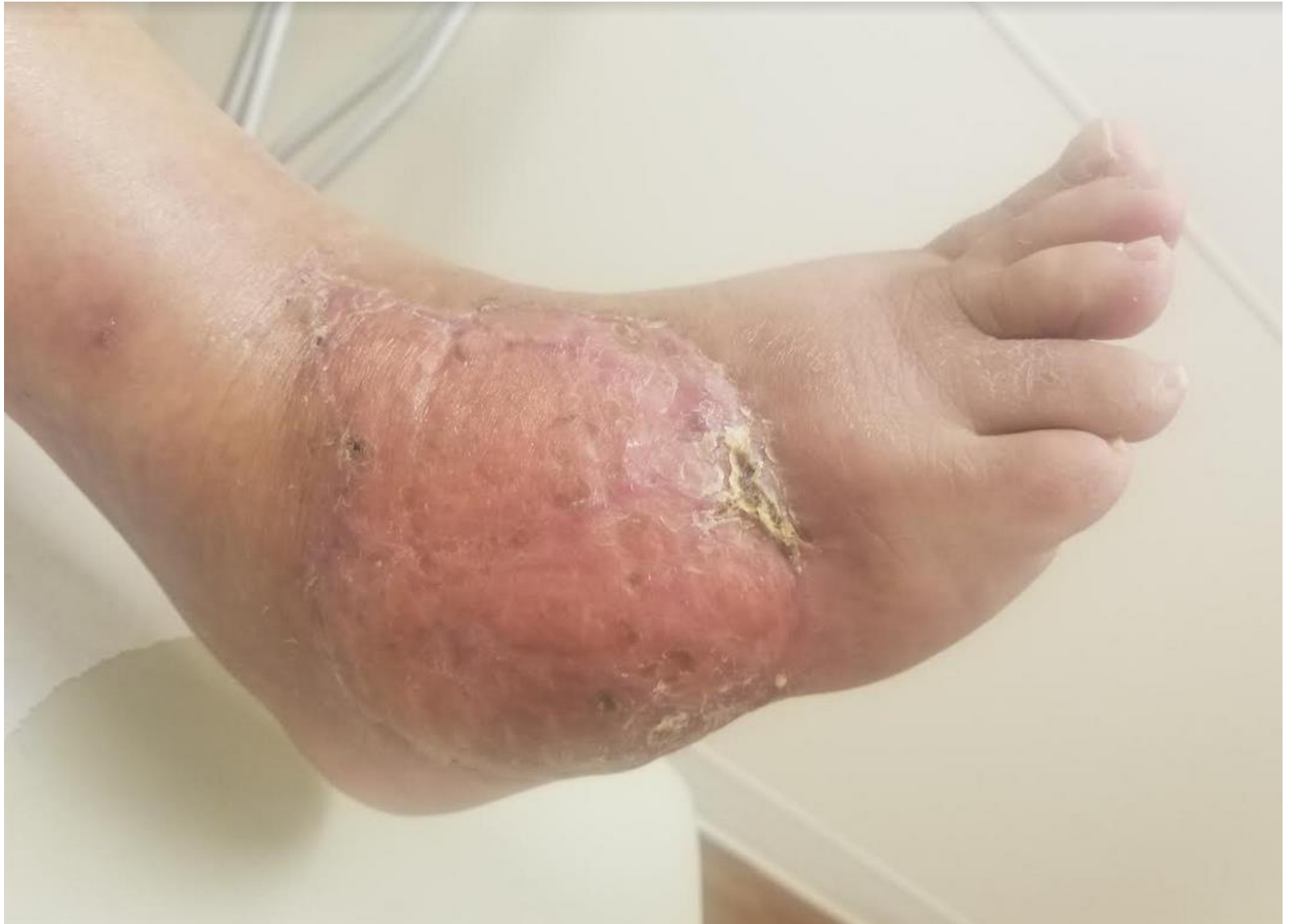



65F. "Callus" removed 4 mo ago.



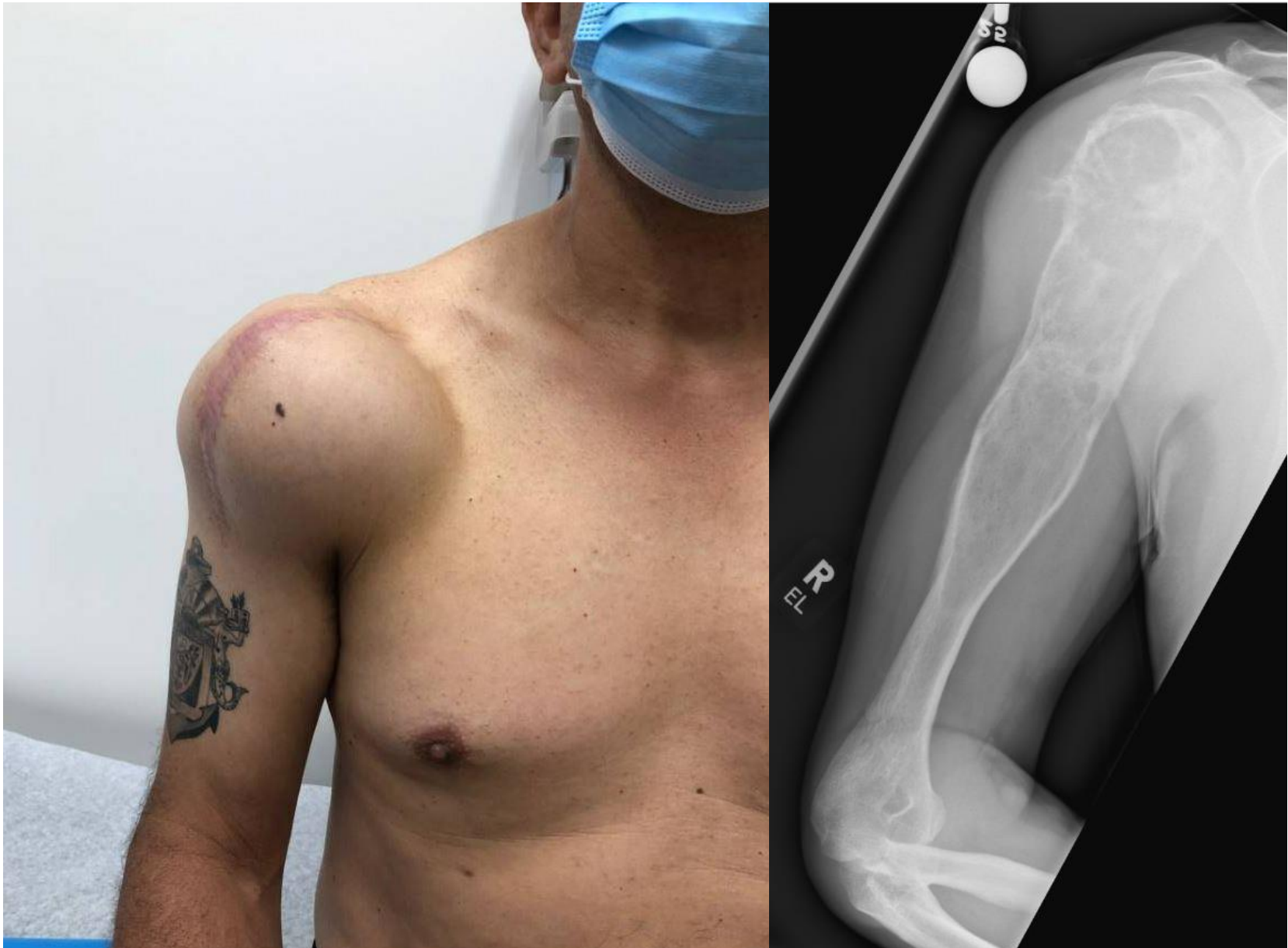

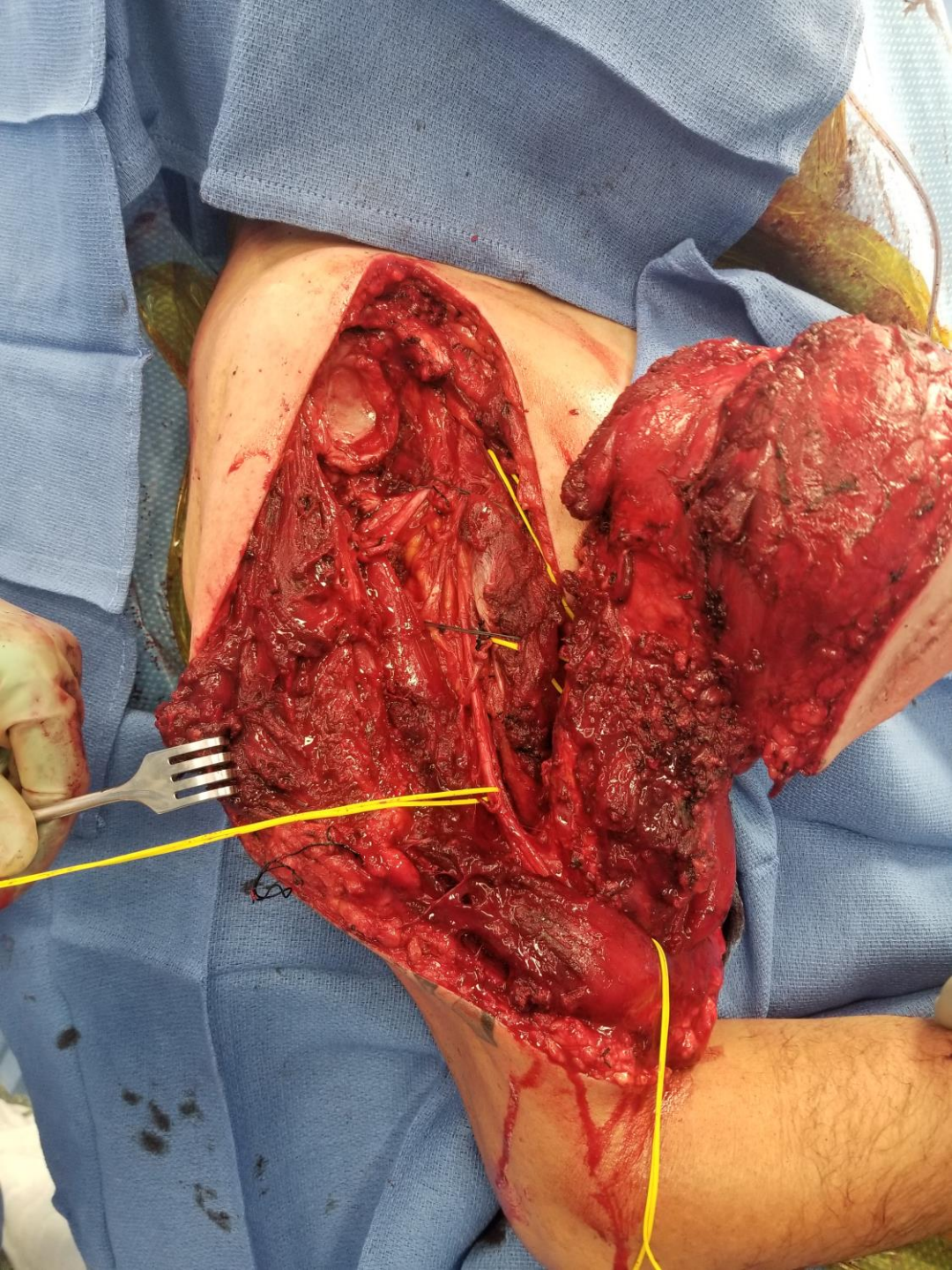
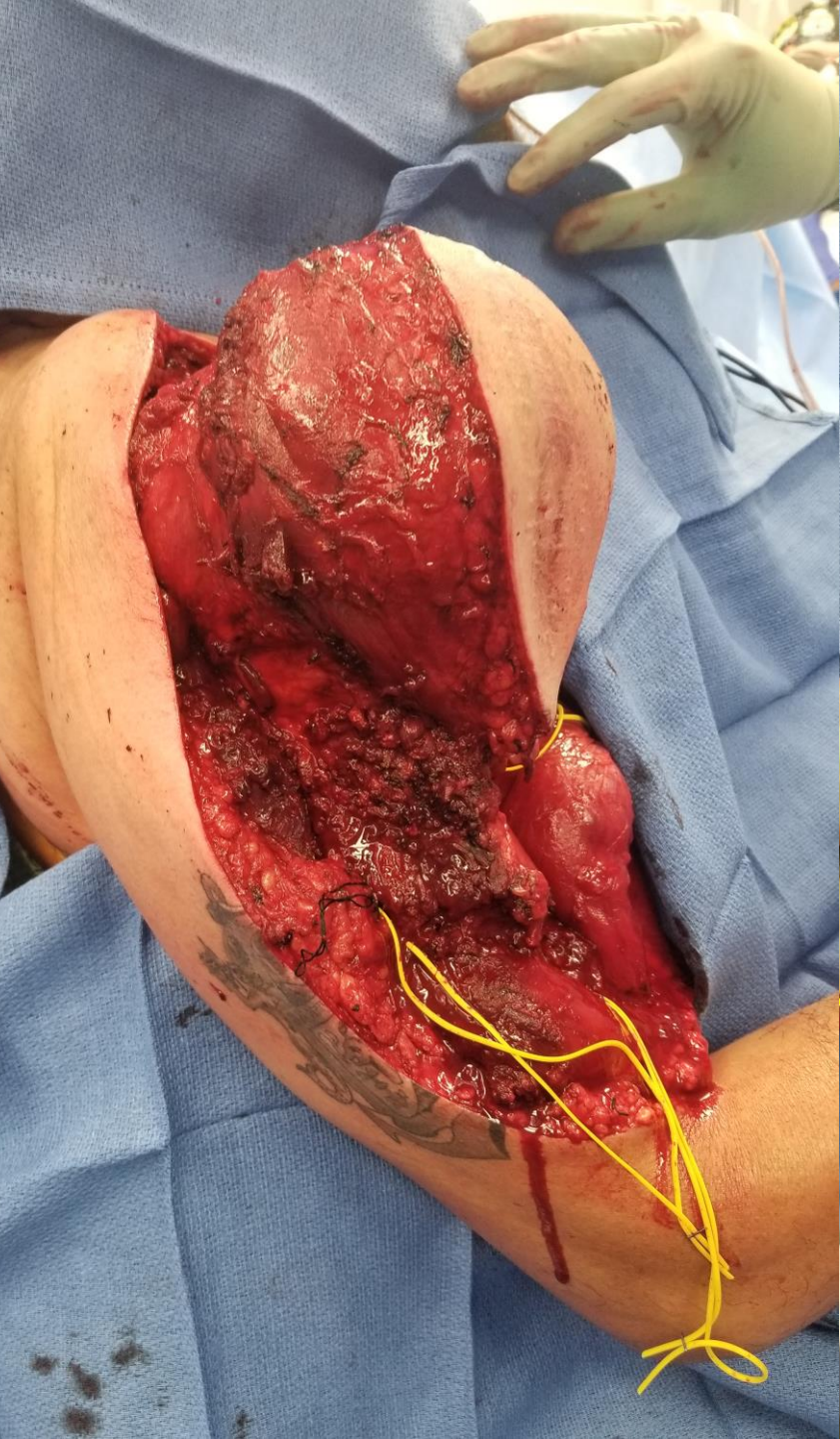


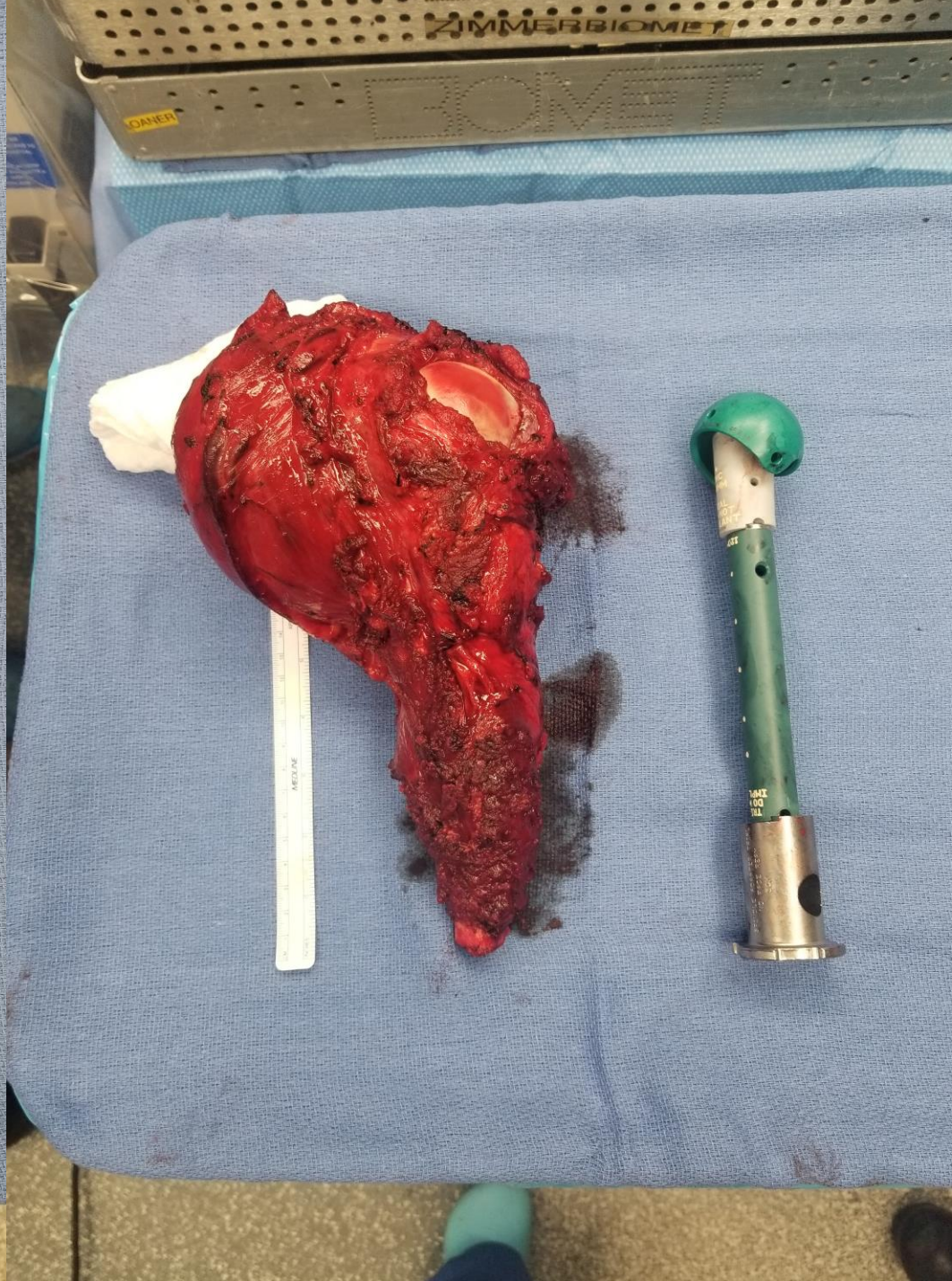
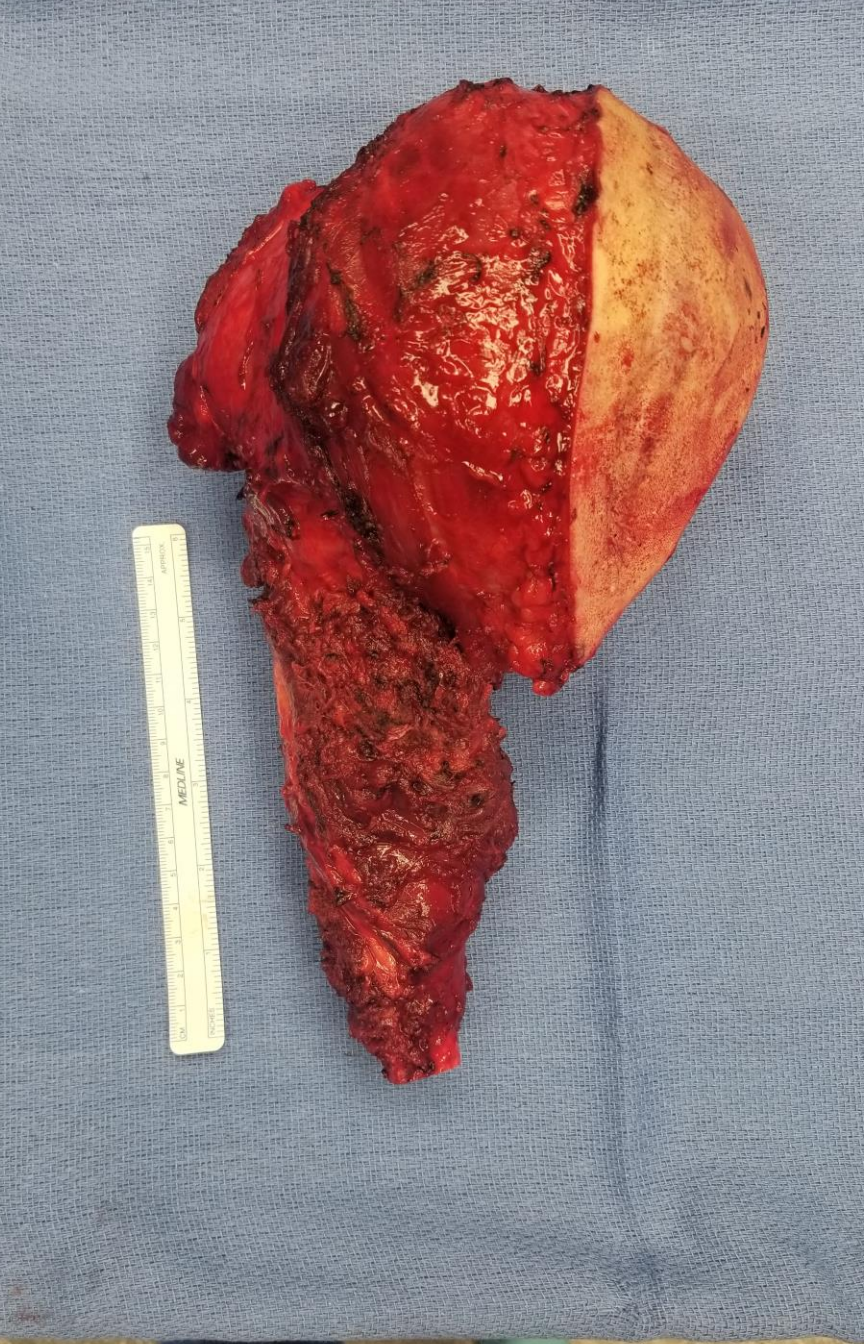Treatment

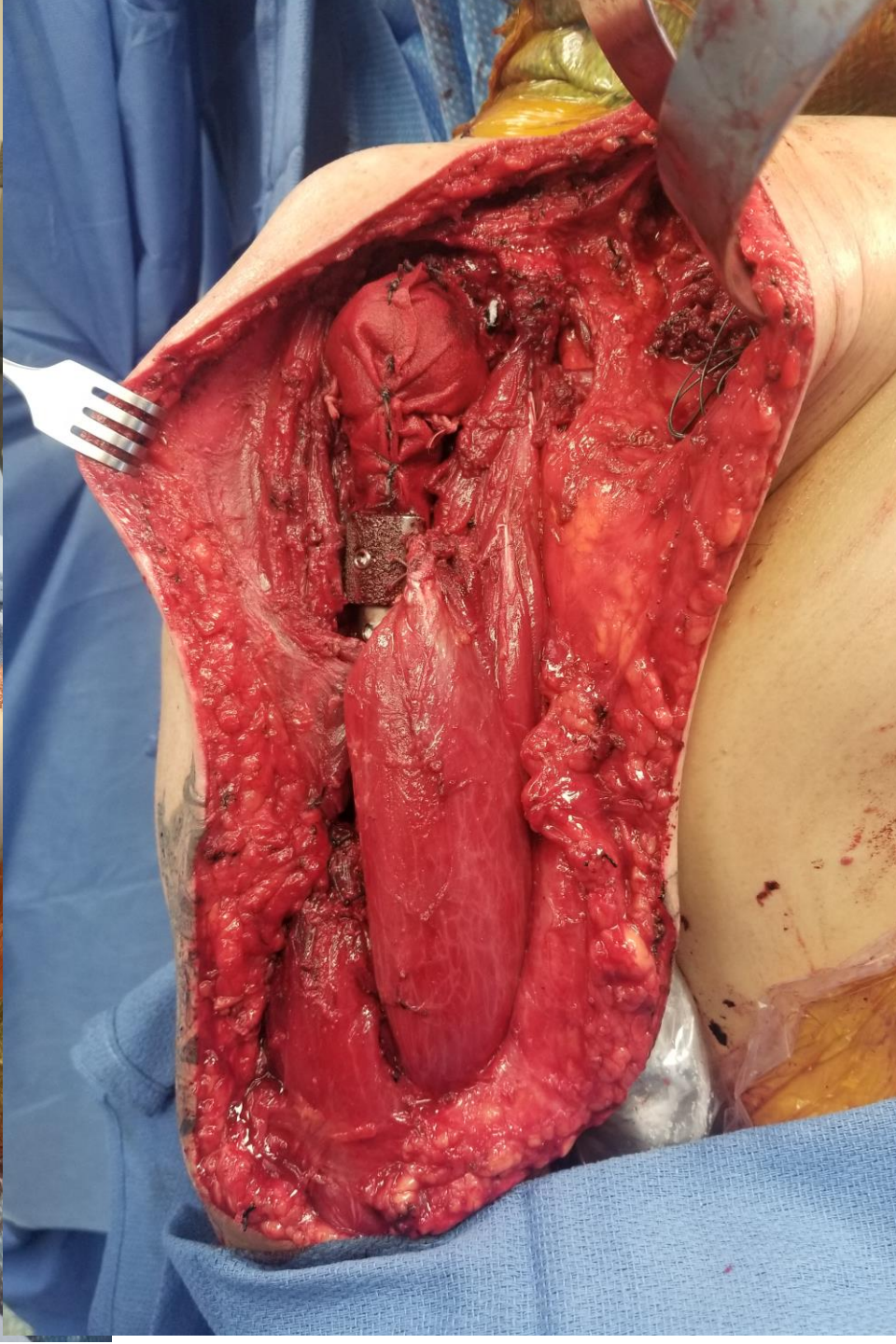
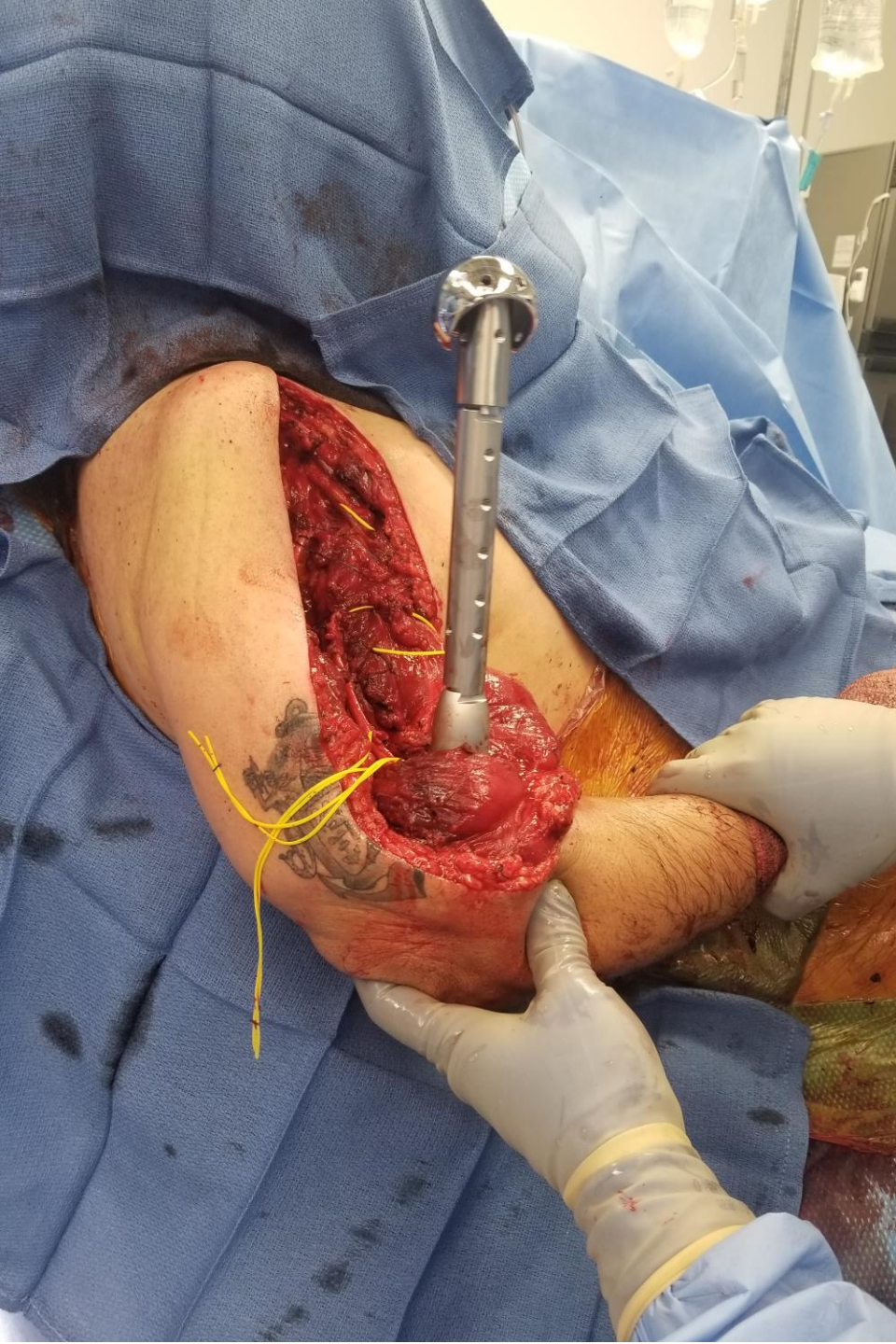
- Sarcoma Center (UCSD!!)
- Multi-disciplinary Tumor Board
- Multi-disciplinary Surgical Team
- Biopsy should be directed by treating surgeon

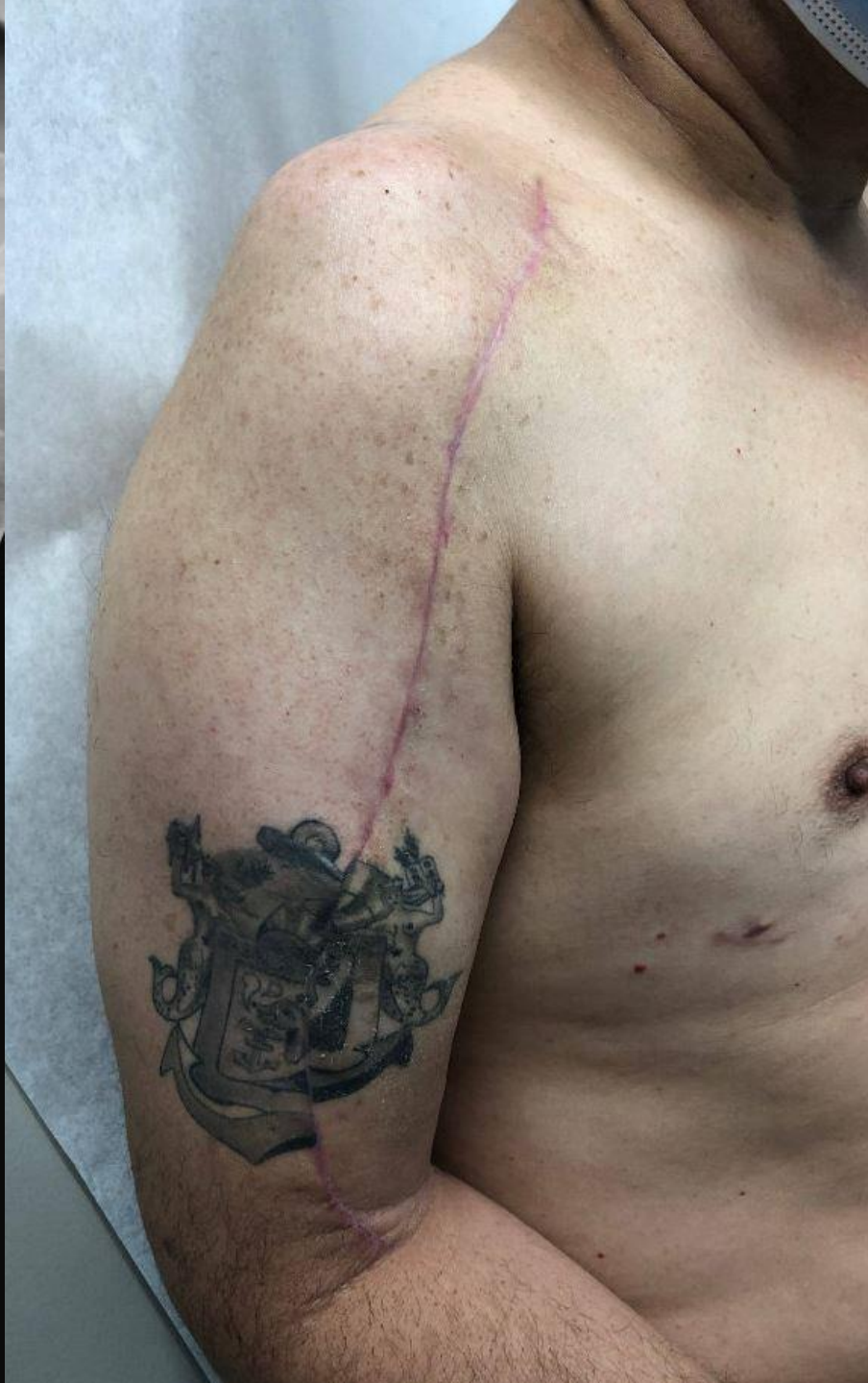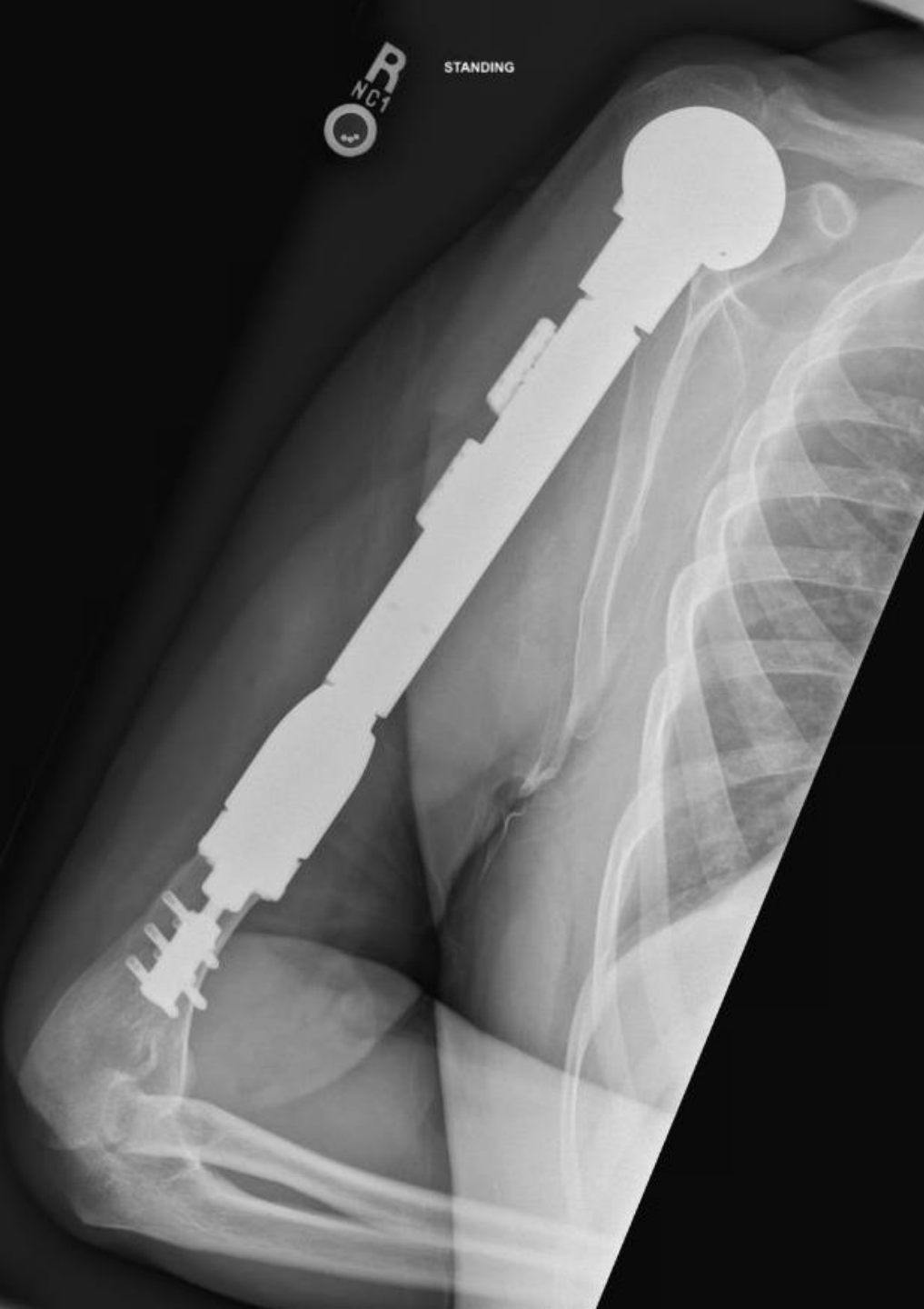52M. Shoulder chondrosarcoma.





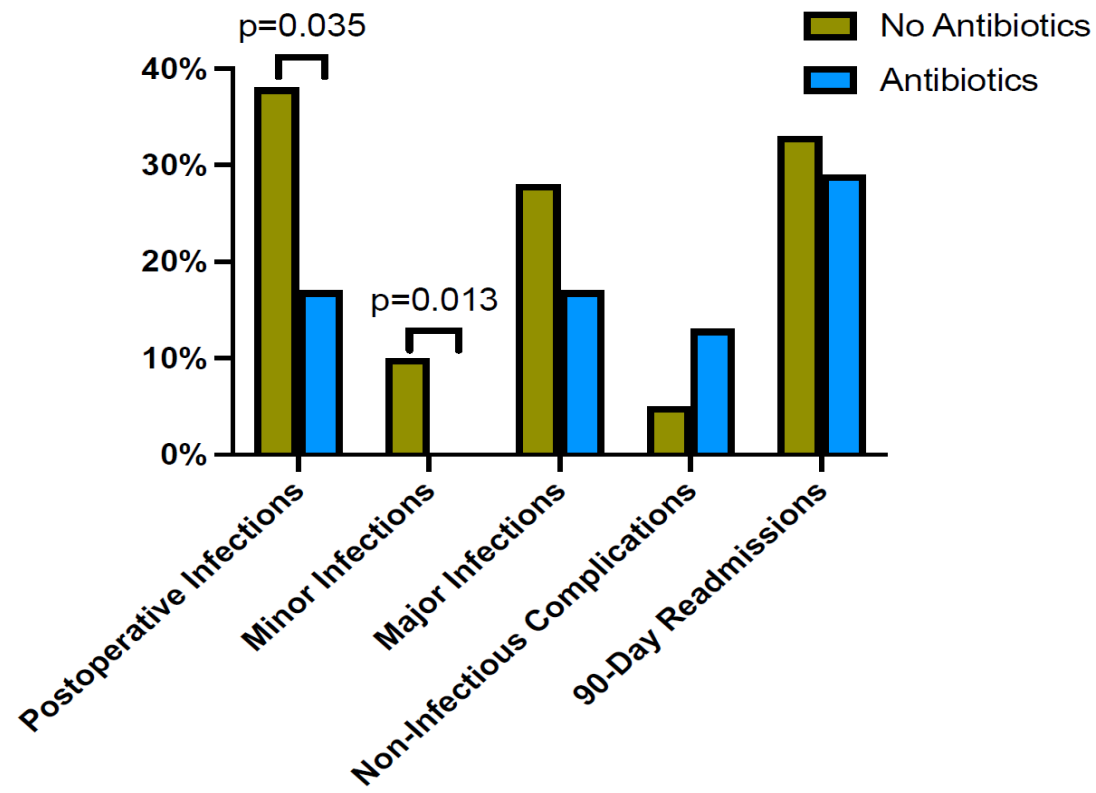






Preventing Complications-Topical Abx

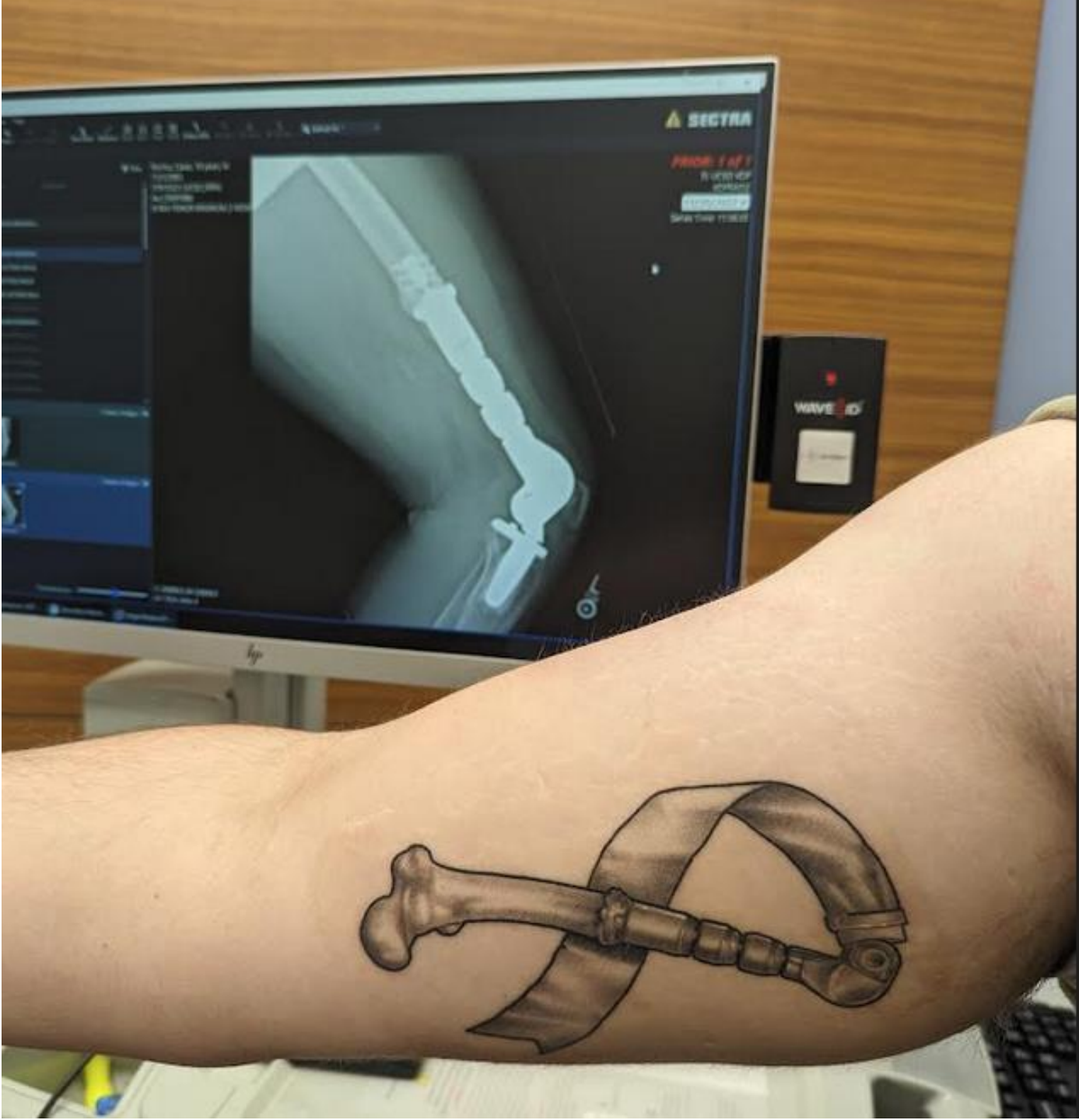	No topical antibiotic (n=57)	Topical antibiotic (n=24)	P-value
Age	58 ± 18	53 ± 21	0.258
Sex			0.275
Male	28 (49%)	15 (62.5%)	
Female	29 (51%)	9 (37.5%)	
BMI	28.2 ± 6.6	30 ± 5.8	0.234
ASA Class	2.6 ± 0.6	2.7 ± 0.5	0.542
Tumor Origin			0.006
Bone	7 (12%)	11 (46%)	
Soft Tissue	50 (88%)	13 (54%)	
Tumor Histology			
Liposarcoma	6 (10%)	4 (17%)	0.489
Synovial Sarcoma	2 (4%)	0 (0%)	0.159
Myxofibrosarcoma	16 (28%)	5 (20%)	0.489
Pleomorphic Sarcoma	12 (21%)	2 (8%)	0.114
Dematofibrosarcoma			
Protuberans	3 (5%)	1 (4%)	0.832
Leiomyosarcoma	5 (9%)	0 (0%)	0.024
Chondrosarcoma	1 (2%)	3 (13%)	0.143
Osteosarcoma	5 (9%)	6 (25%)	0.107
Other	7 (12%)	3 (13%)	0.979
Tumor Location			0.312
Proximal Upper Extremity	8 (14%)	1 (4%)	
Distal Upper Extremity	3 (5%)	0 (0%)	
Proximal Lower Extremity	39 (69%)	17 (71%)	
Distal Lower Extremity	7 (12%)	6 (25%)	
Tumor Grade	2.5 ± 0.7	2.4 ± 0.8	0.757
1	6 (11%)	3 (13%)	
2	15 (26%)	4 (17%)	
3	36 (63%)	17 (70%)	
Radiographic Tumor Size (cm)	7.61 ± 5.15	11.64 ± 7.79	0.030
Pathologic Tumor Size (cm)	8.68 ± 6.83	12.55 ± 7.31	0.032
Known Metastasis at Surgery			0.599
Yes	4 (7%)	1 (4%)	
No	53 (93%)	23 (96%)	
OR Time (minutes)	475 ± 322	783 ± 381	0.001
Estimated Blood Loss (mL)	188 ± 544	442 ± 399	0.019
Intraoperative Complications			0.083
Yes	3 (5%)	0 (0%)	
No	54 (95%)	24 (100%)	



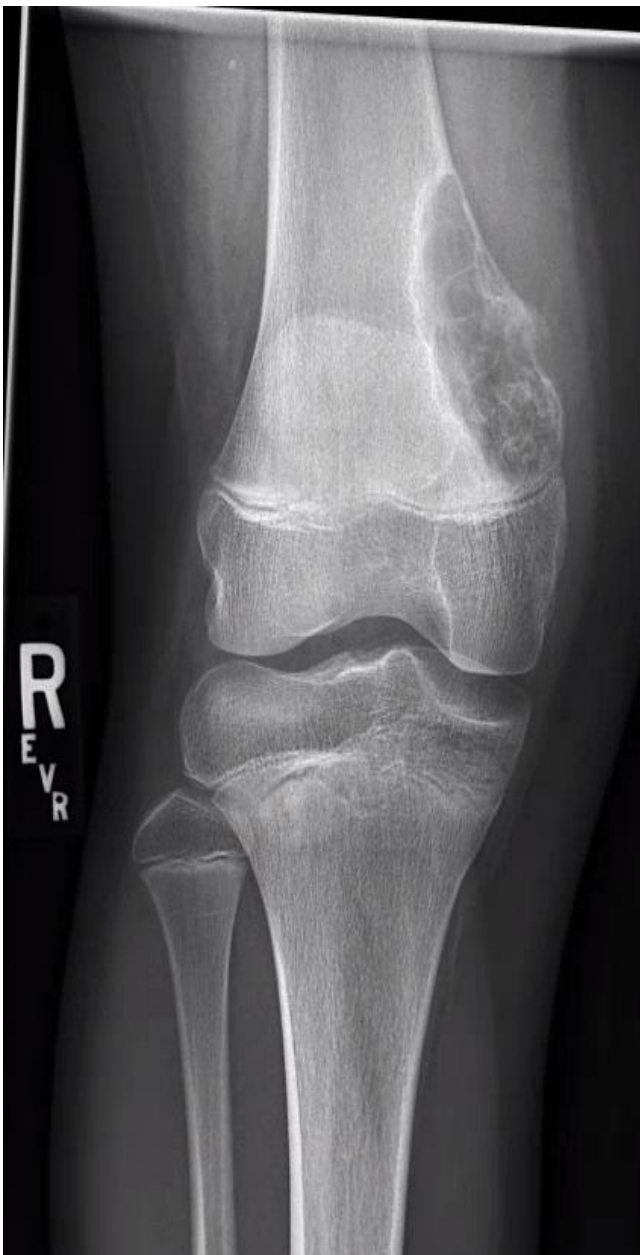Haldeman P, Trimm C, Chun L, Reid C, Flint J, Chiarappa F. Topical Antibiotics Decrease Infections in Extremity Sarcoma Surgery. Connective Tissue Oncology Society (CTOS) Annual Meeting. Dublin, IE.

Thriving vs surviving



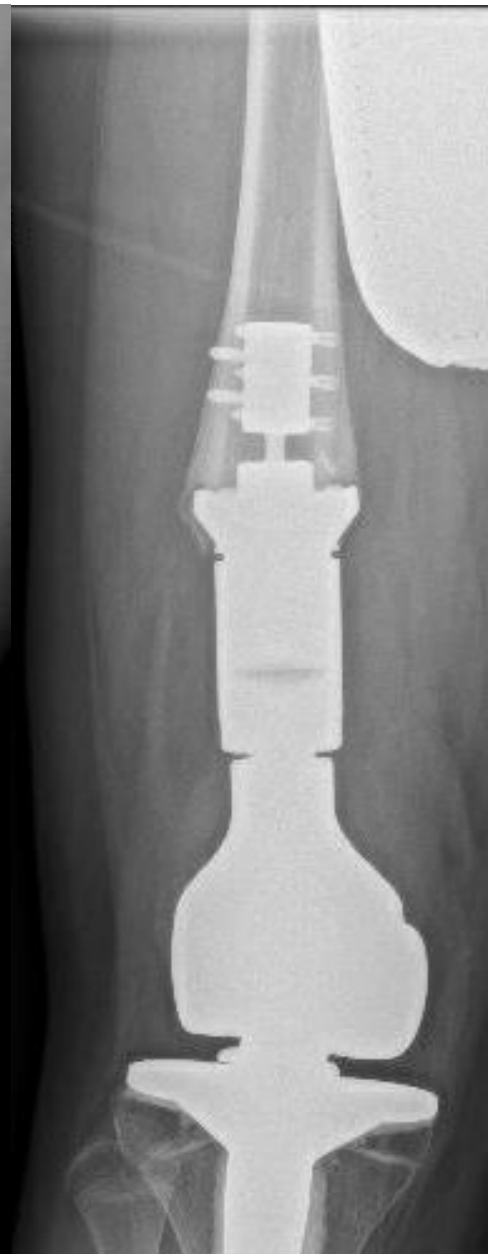
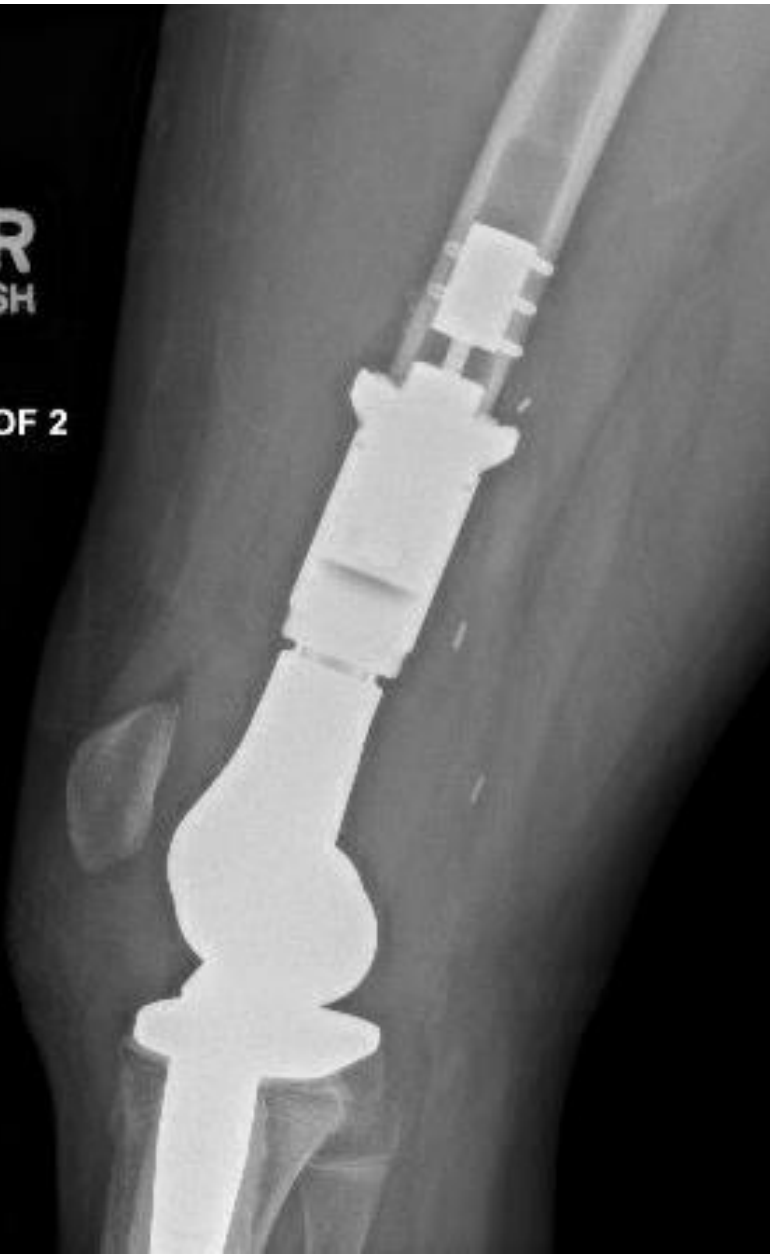
Osteosarcoma.



R
SH

OF 2



R
F
V
R

Feliz Navidad

Familia Costa Gilbert

oscar m...
photo

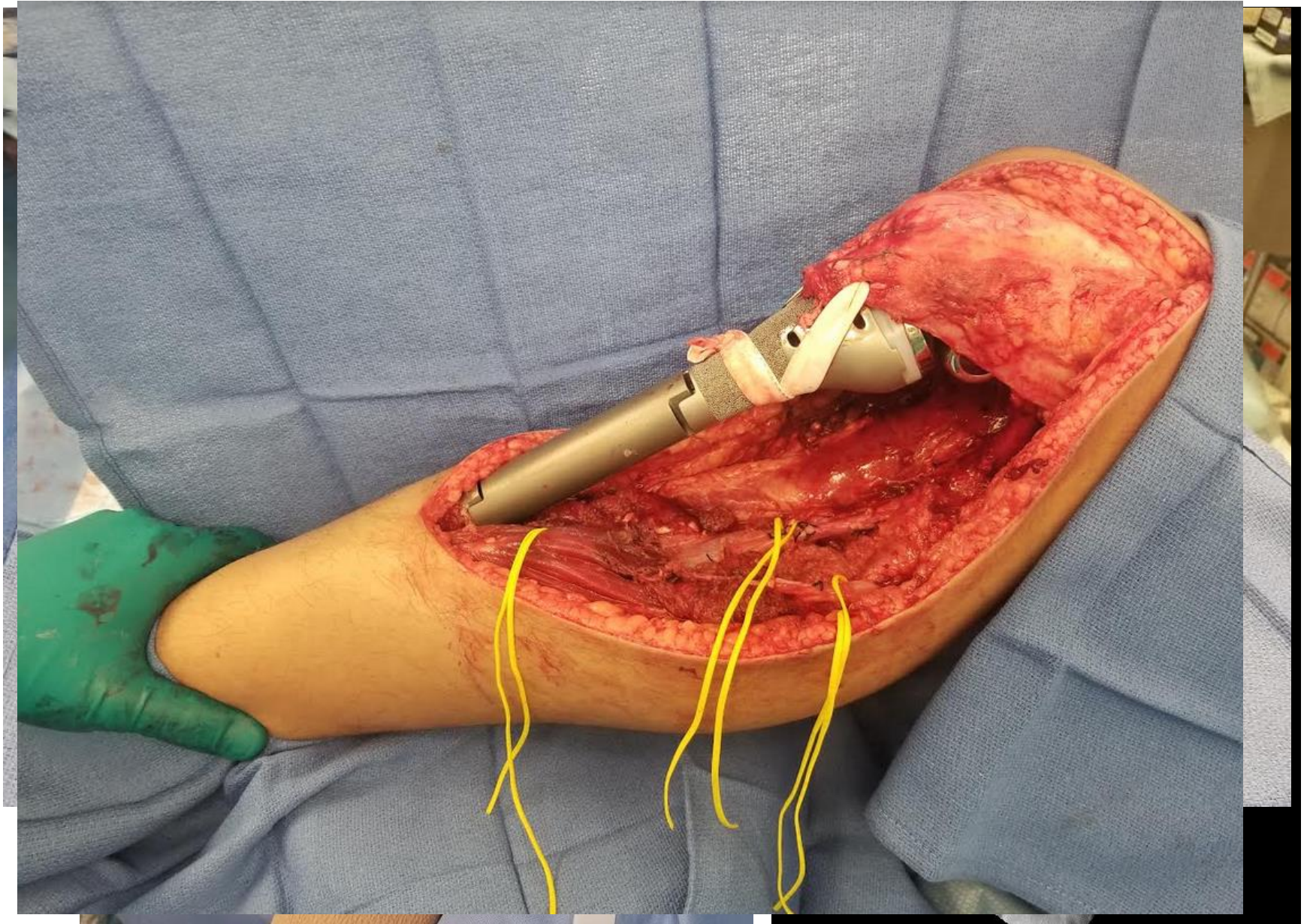


Merry Christmas

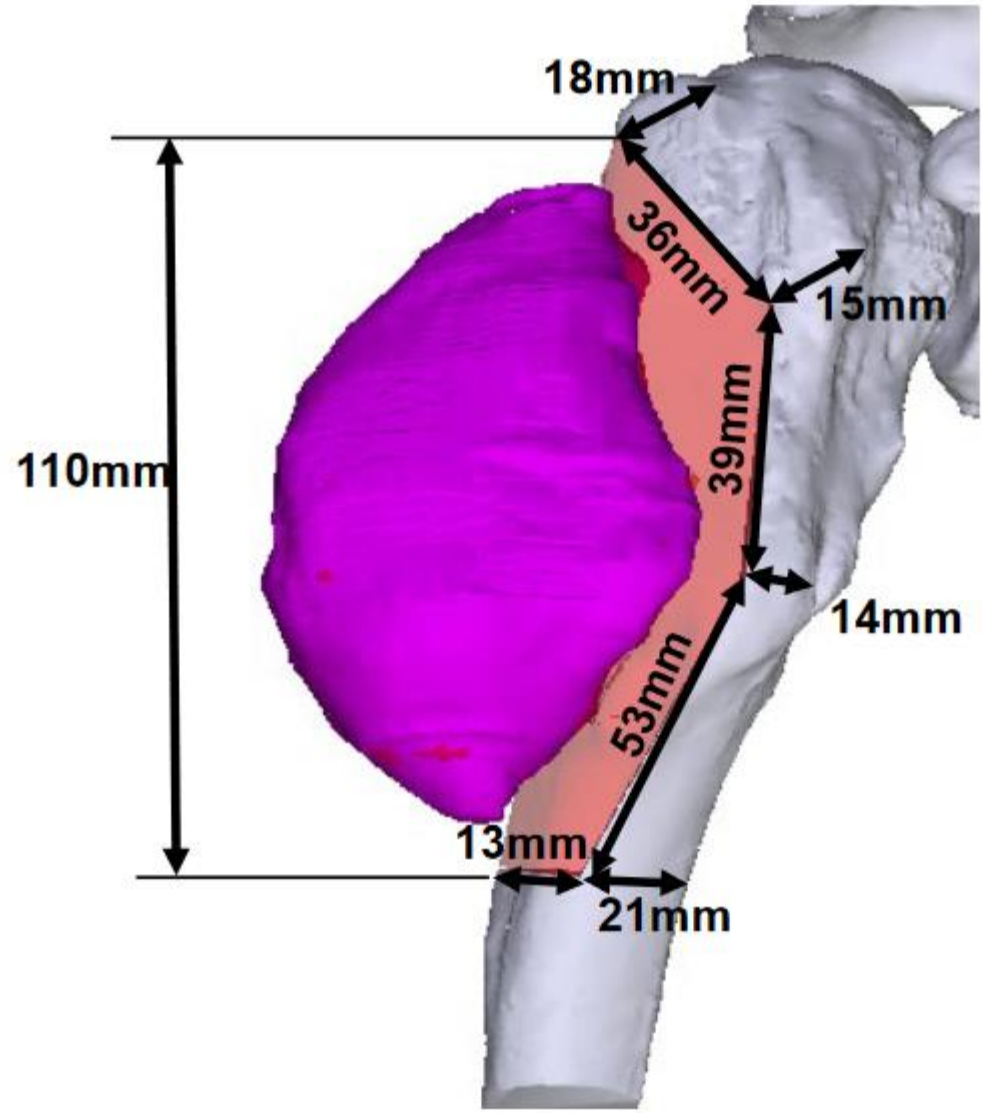
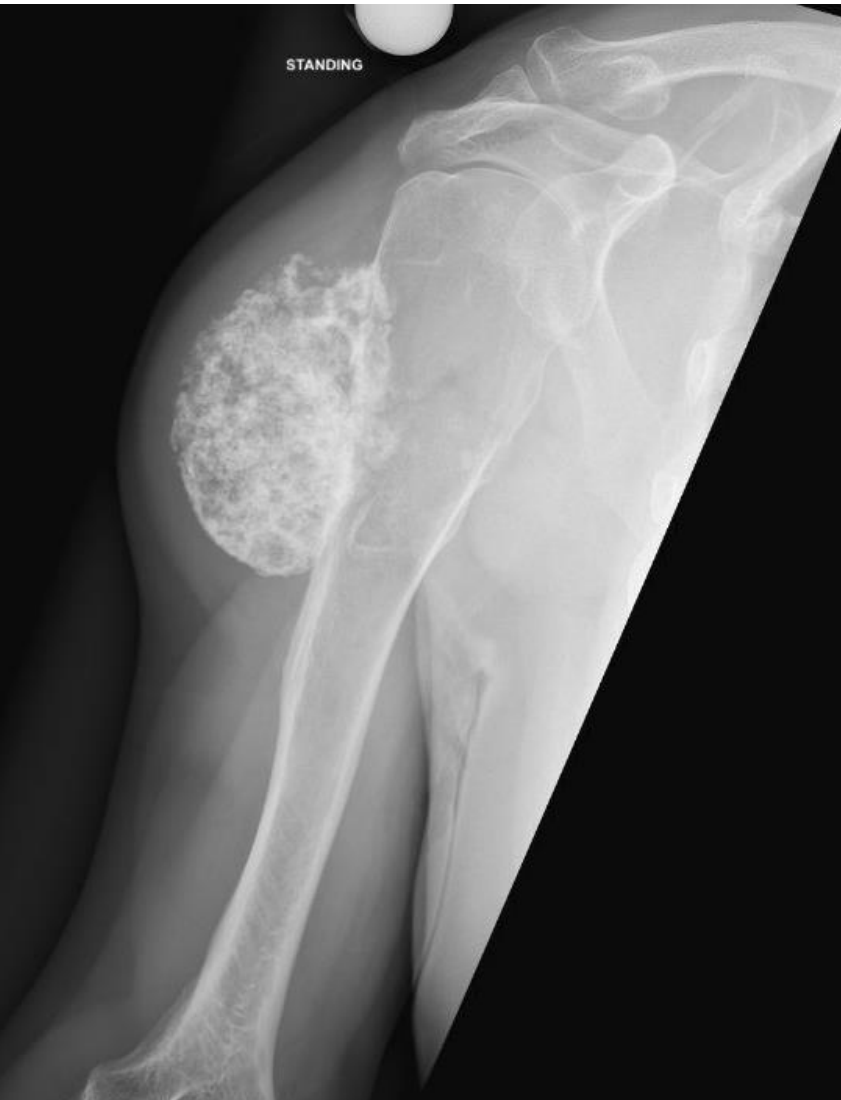2020

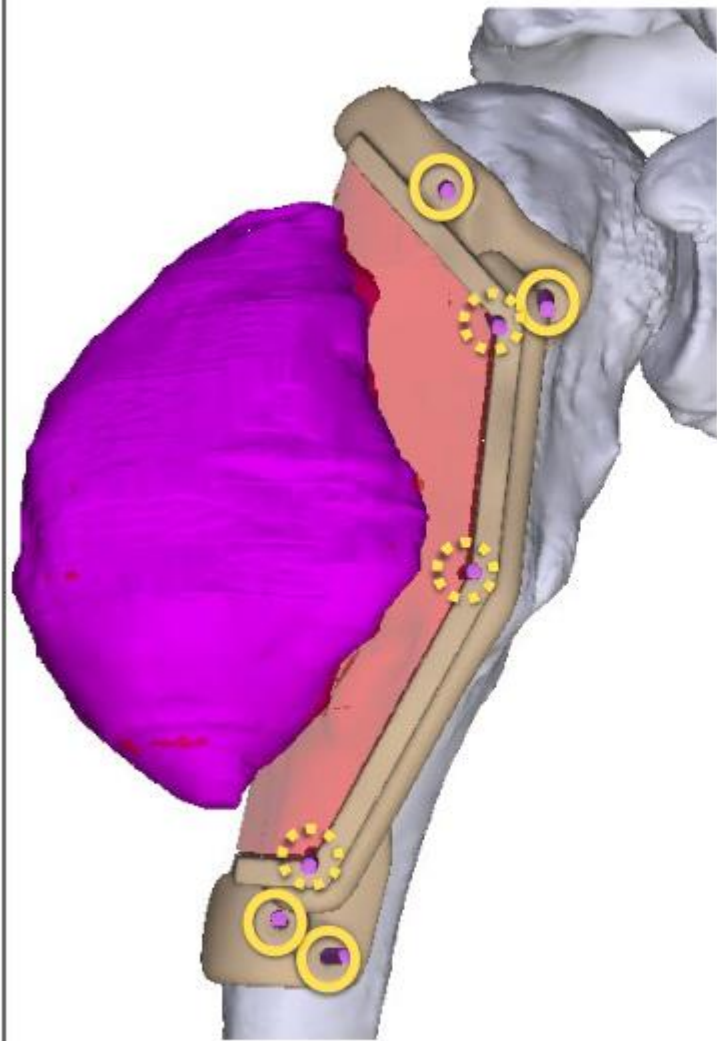
Costa Gilbert Family

PIC•COLLAGE

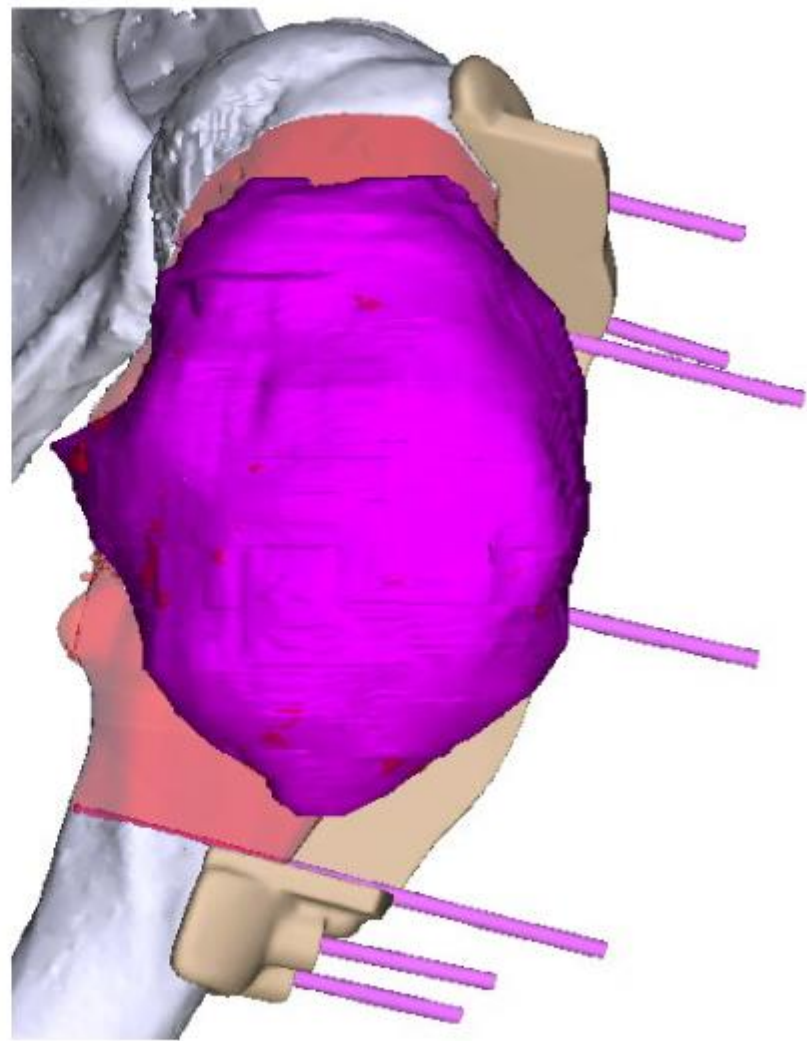


Limb salvage: Pushing the Envelope

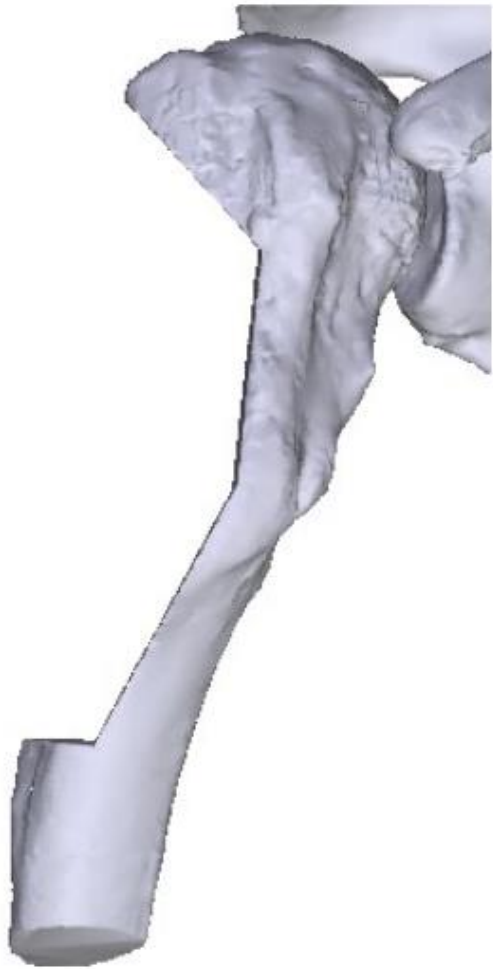



Anterior



Lateral



Anterior



Lateral



Posterior



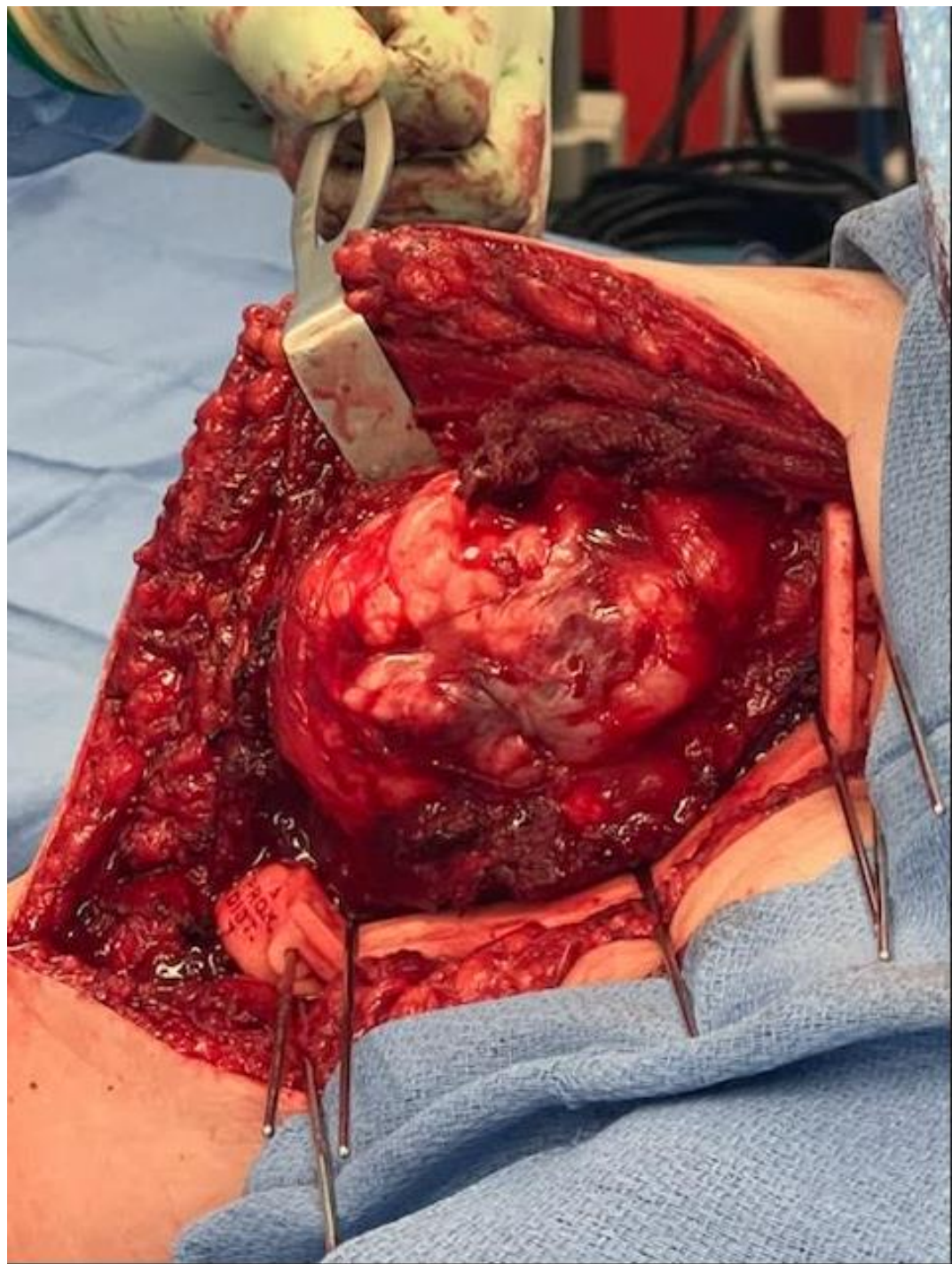
Anterior

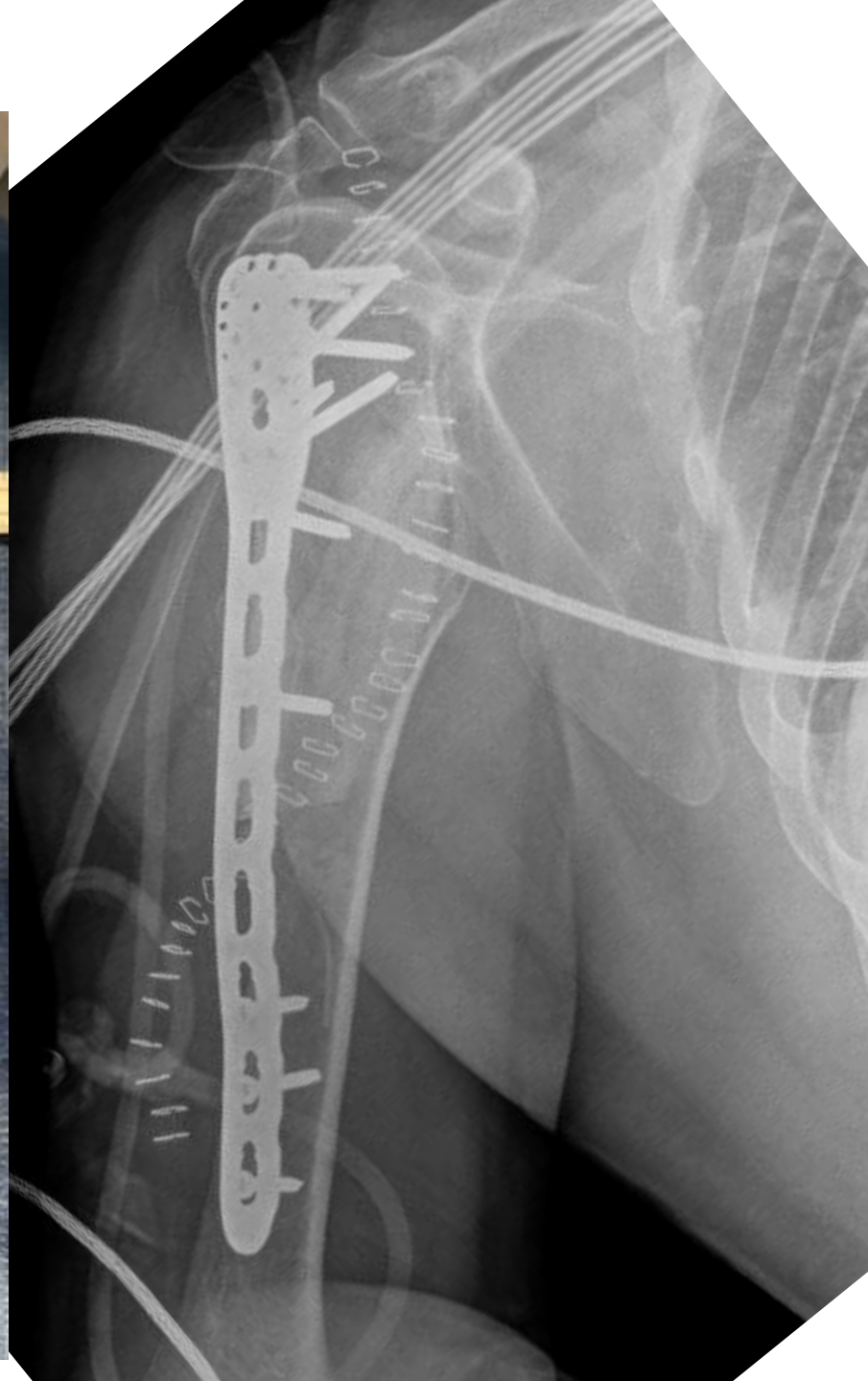
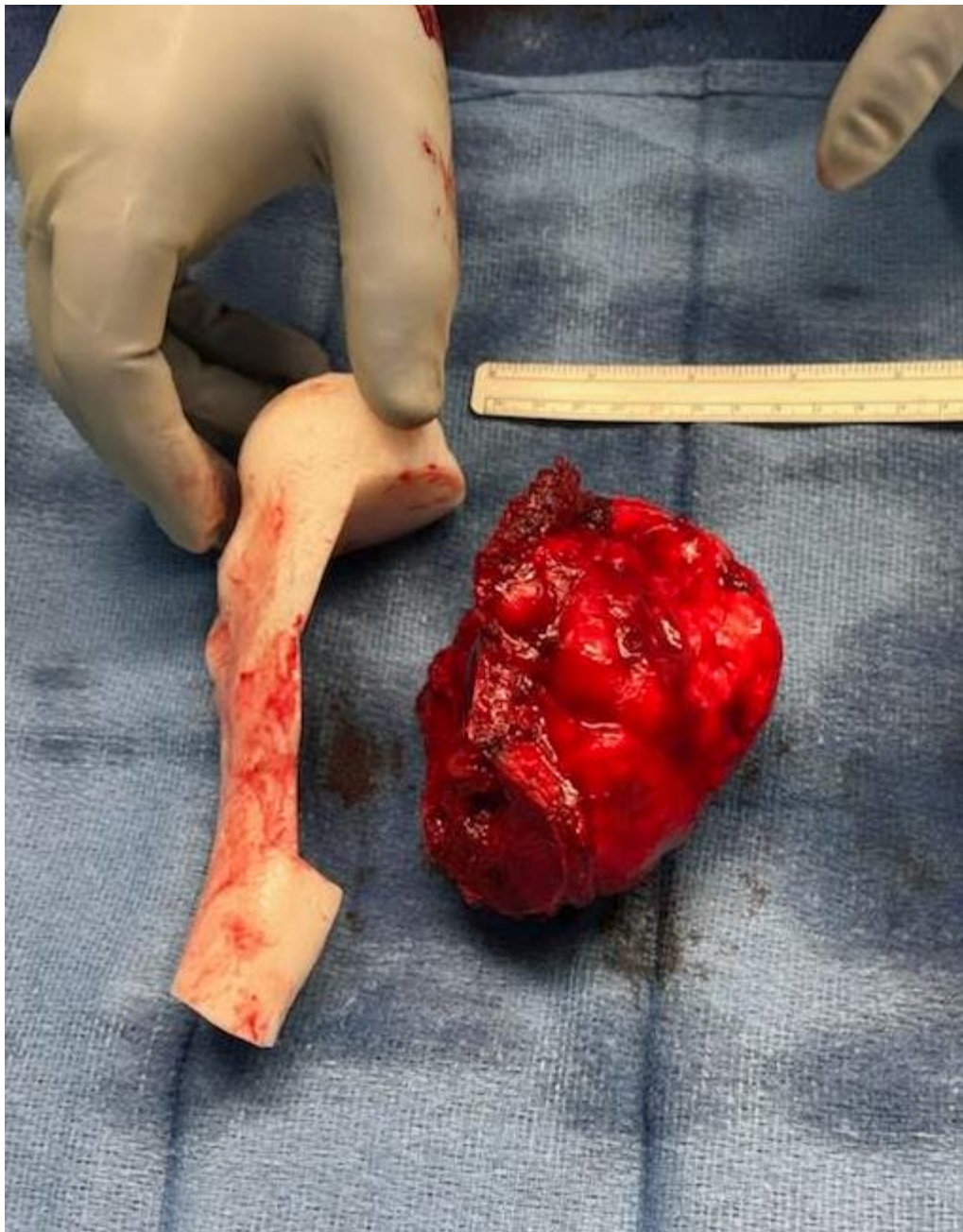


Lateral

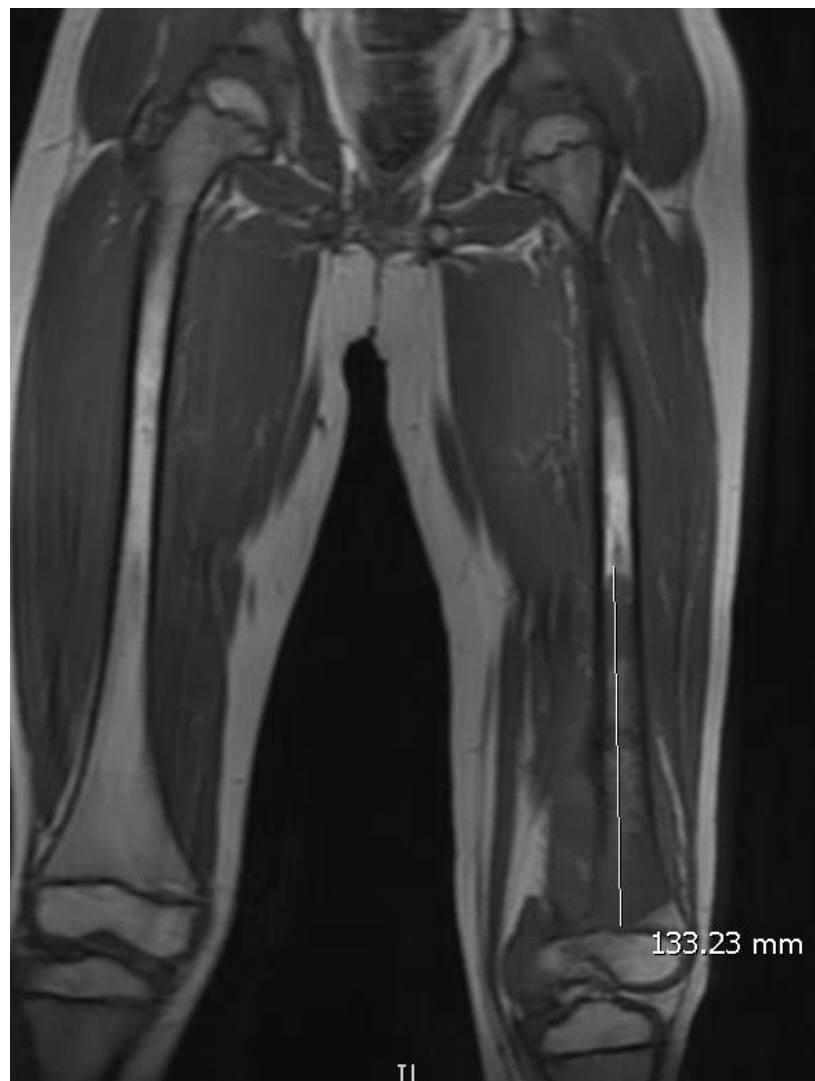
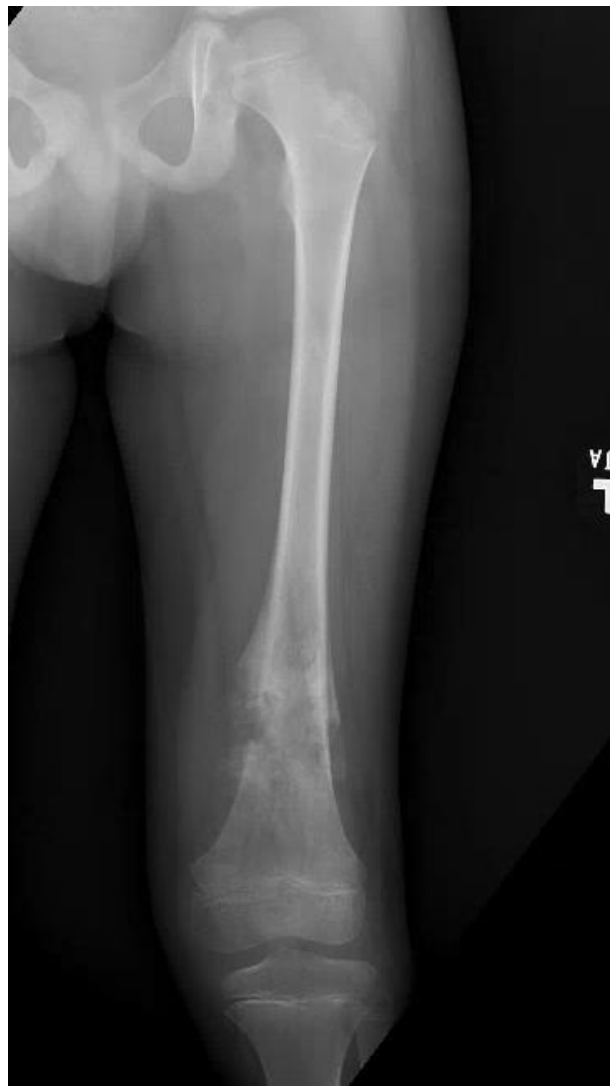
Posterior

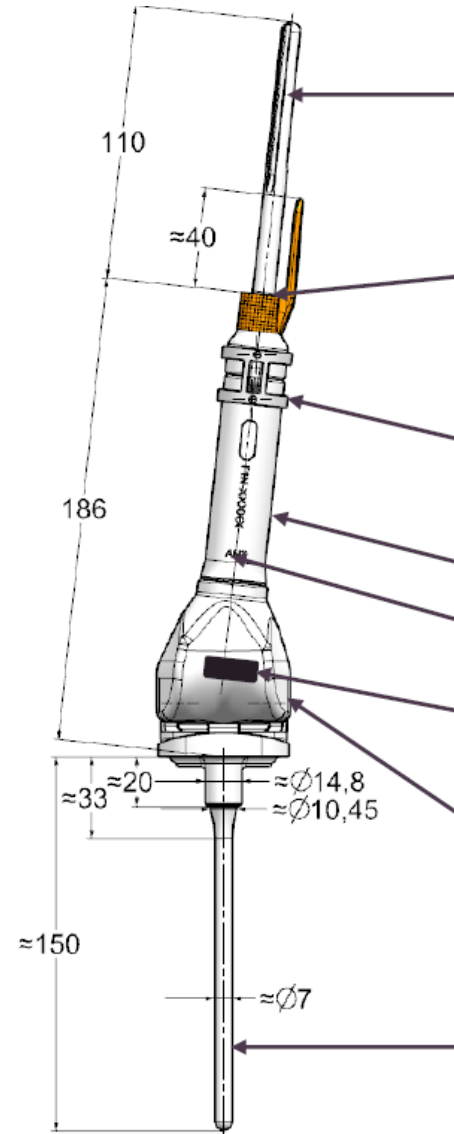
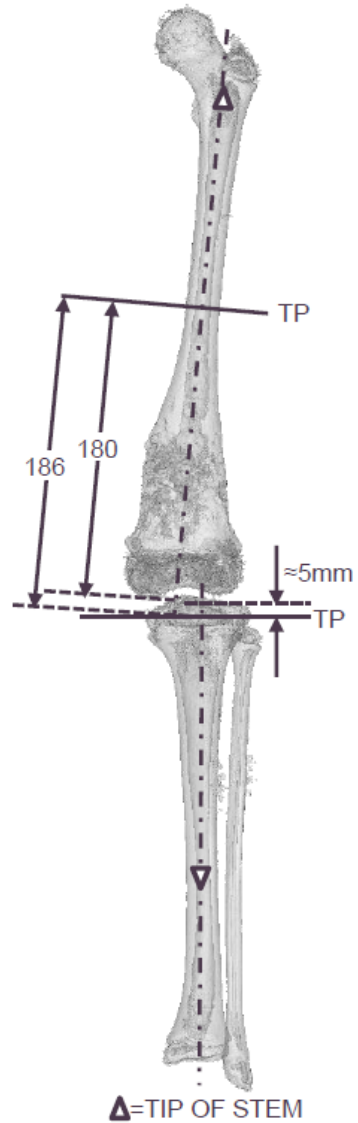




8yo. Osteosarcoma.



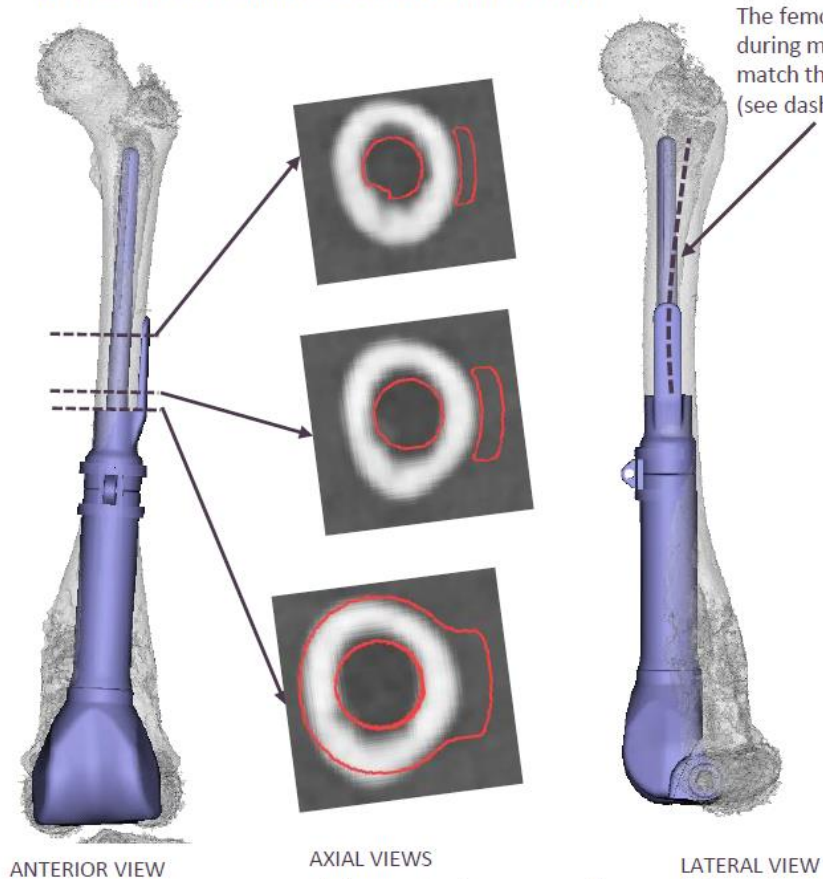
Patient specific growing prosthesis



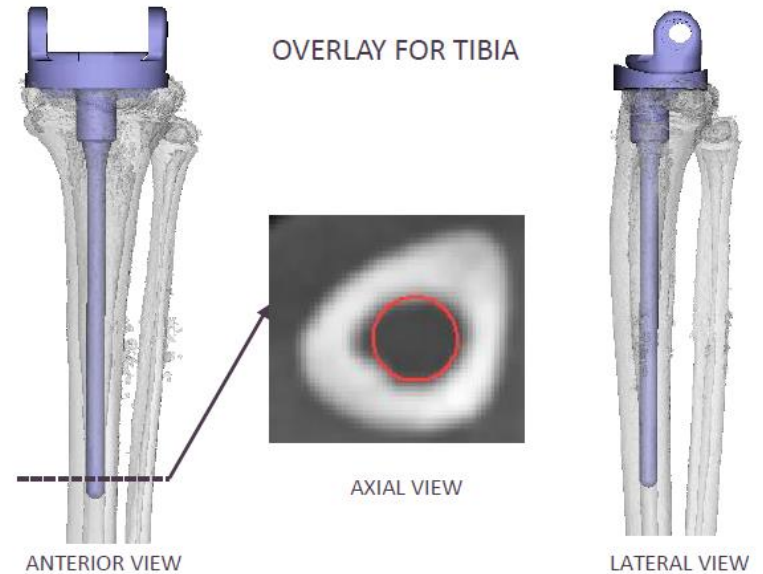
Patient specific growing prosthesis

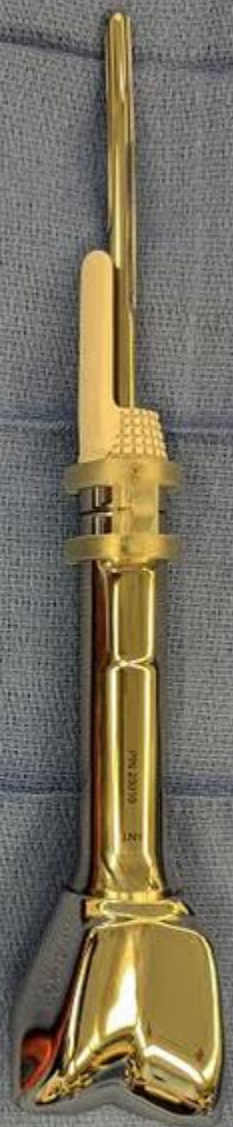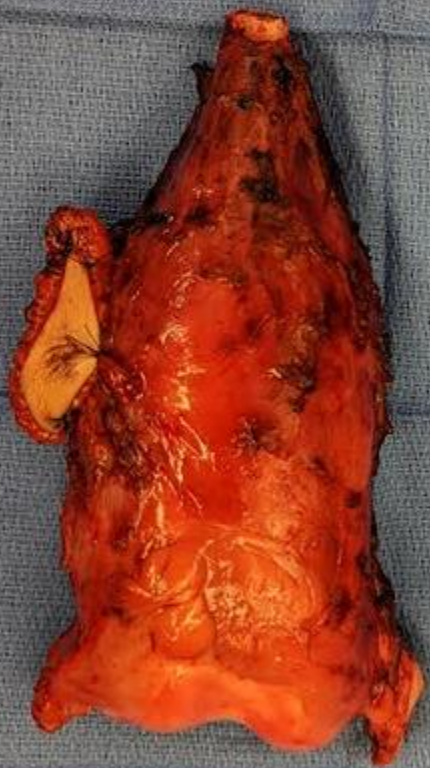OVERLAY OF THE IMPLANT WITH CT IMAGES

OVERLAY FOR FEMORAL COLLAR AND STEM



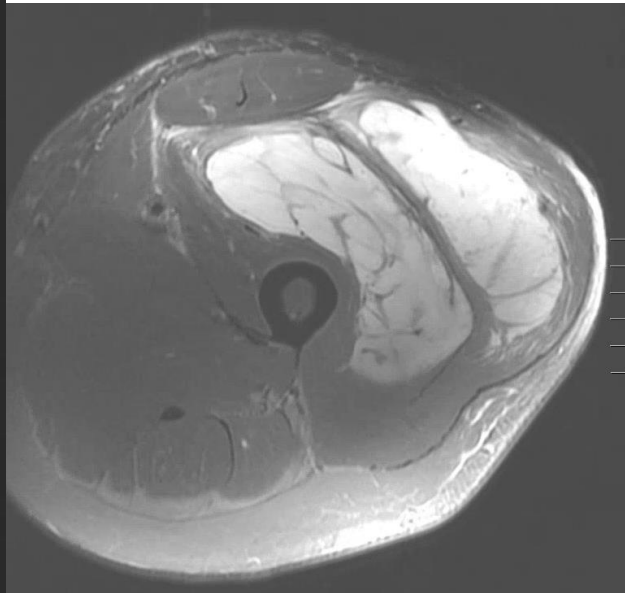
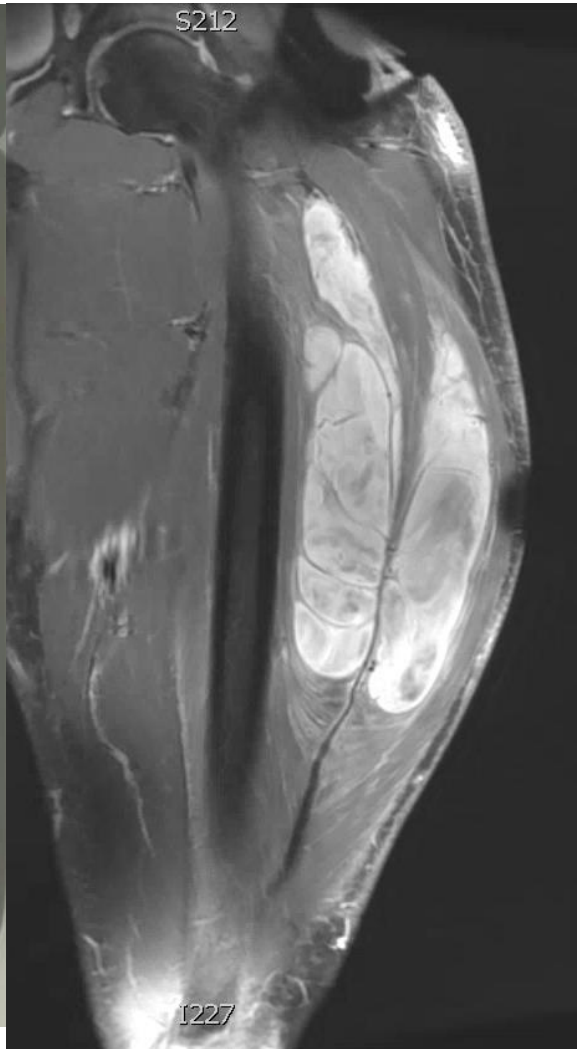
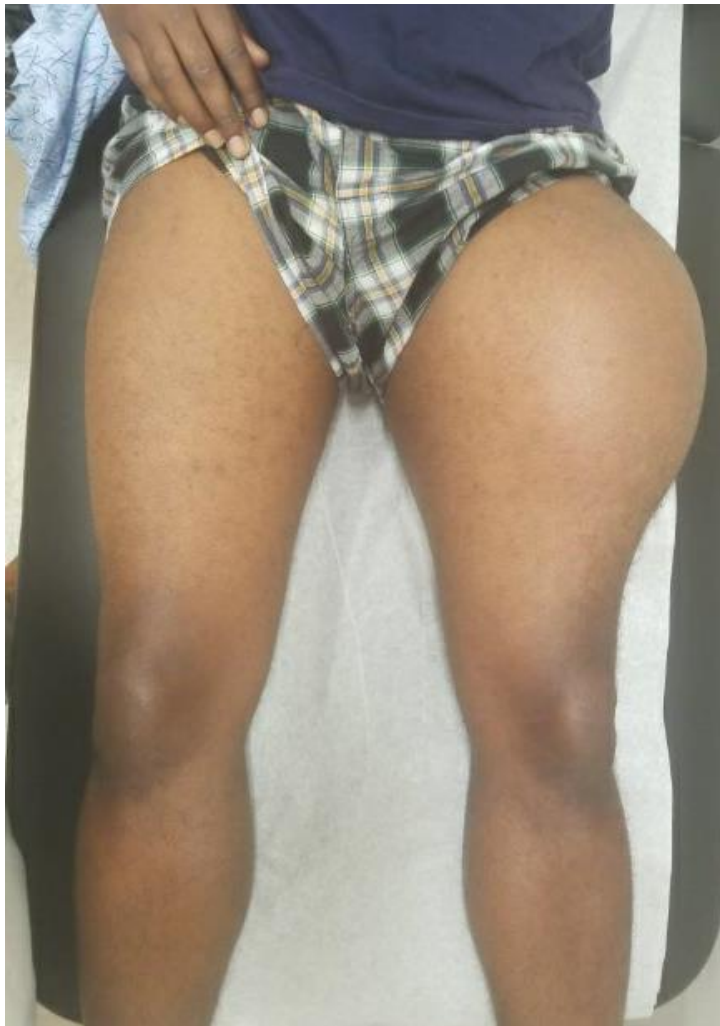OVERLAY FOR TIBIA



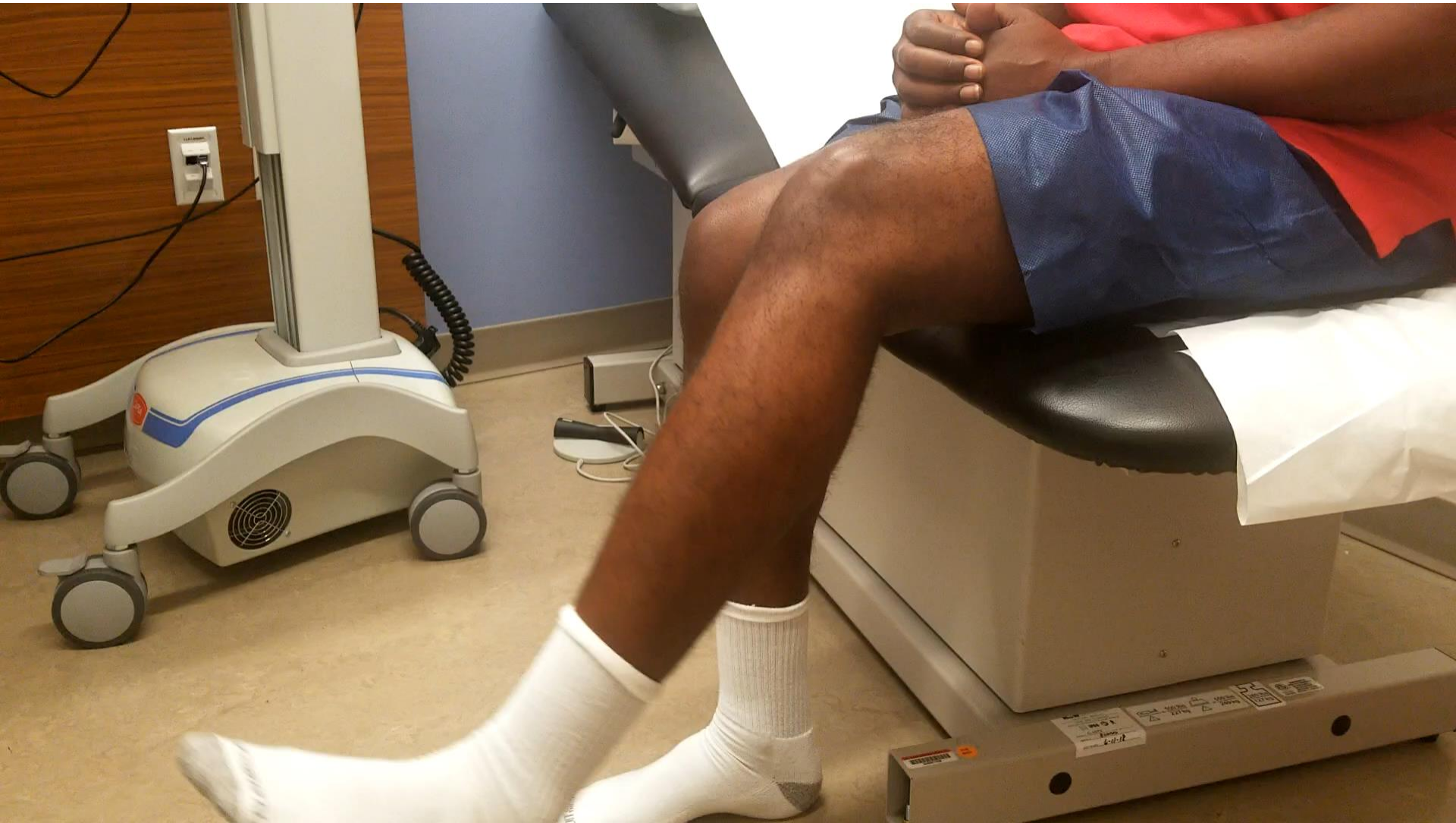

Magnetically controlled expansion





Multi-disciplinary Reconstruction



When to refer?

- Anytime!
- New mass
- Enlarging/symptomatic
- >5cm (raquetball)
- History of cancer

Thanks! 330-620-5021







